

HARRAN ÜNİVERSİTESİ VETERİNER FAKÜLTESİ DERGİSİ

Harran University
Journal of the Faculty of Veterinary Medicine



Harran Üniversitesi Veteriner Fakültesi Yayınıdır
Published by Harran University Faculty of Veterinary Medicine

HARRAN ÜNİVERSİTESİ VETERİNER FAKÜLTESİ DERGİSİ

Harran University
Journal of The Faculty of Veterinary Medicine



Harran Üniversitesi Veteriner Fakültesi Yayınıdır
Published by Harran University Faculty of Veterinary Medicine

YIL/YEAR:2024

CİLT/VOLUME:13

SAYI/ISSUE: 1

HARRAN ÜNİVERSİTESİ

VETERİNER FAKÜLTESİ DERGİSİ

Harran University
Journal of the Faculty of Veterinary Medicine

Harran Üniversitesi
Veteriner Fakültesi Adına
Sahibi/Owner
Prof. Dr. Nihat DENEK
Dekan/Dean

Baş Editör/Editor in Chief
Prof. Dr. Oktay KESKİN

Editörler Kurulu/Editorial board
Prof. Dr. Bestami YILMAZ
Prof. Dr. Füsün TEMAMOĞULLARI
Prof. Dr. Rahşan YILMAZ
Prof. Dr. Deniz KORKMAZ
Doç. Dr. Serap KILIÇ ALTUN
Doç. Dr. Birten EMRE
Doç. Dr. Mücahit KAHRAMAN
Doç. Dr. Ünal YAVUZ

İngilizce Editörü/English Editor
Prof. Dr. Ayşe MENTEŞ
Dr. Öğr. Üyesi Özlem BEDİR
Dr. Öğr. Üyesi Teyfik ÇELEN

Mizanpaj Editörü/Layout Editor
Dr. Öğr. Üyesi İrfan ÖZGÜNLÜK

Dergi Sekreteri/Journal Secretary
Dr. Öğr. Üyesi Ayfer GÜLLÜ YÜCETEPE

Yazışma /Correspondence
Harran Üniversitesi Veteriner Fakültesi Dergisi Editörlüğü
Eyyübiye Kampüsü, 63200 - Şanlıurfa/TÜRKİYE
Tel: +90 414 318 38 59
+90 414 318 38 55
Faks: +90 414 318 39 22
e-mail: harranvet@gmail.com

Harran Üniversitesi Veteriner Fakültesi Dergisi Hakemli Bir Dergi Olup, Yılda 2(iki) Sayı Olarak Yayınlanır. ULAKBİM (Yaşam Bilimleri Veri Tabanı), Türkiye Atıf Dizini, Cab abstracts, Index Copernicus, Zoological Record, SOBIAD gibi ulusal ve uluslararası indeksler tarafından taranmaktadır.
Yıl/Year: 2024- Cilt/Volume: 1432 Sayı/Issue 1

Danışma Kurulu/Advisory Board

Prof. Dr. Ahmet ÇAKIR, Ankara Üniv. Vet. Fak. Ankara, Türkiye.
Prof. Dr. Ali Reha AĞAOĞLU, Burdur Mehmet Akif Ersoy Üniv. Vet. Fak. Burdur, Türkiye.
Prof. Dr. Alkan KAMILOĞLU, Kafkas Üniv. Vet. Fak. Kars, Türkiye.
Prof. Dr. Anila HODA, Agric. Uni. of Tirana, Fac. of Agric.& Environ. Tirana, Albania.
Prof. Dr. Atilla ŞİMŞEK, Selçuk Üniv. Vet. Fak. Konya, Türkiye.
Prof. Dr. Bülent ULUTAŞ, Aydın Adnan Menderes Üniv. Vet. Fak. Aydın, Türkiye.
Prof. Dr. Ender YARSAN, Ankara Üniv. Vet. Fak. Ankara, Türkiye.
Prof. Dr. Ergun AKÇAY, Ankara Üniv. Vet. Fak. Ankara, Türkiye.
Prof. Dr. Gerald REINER, Justus-Liebig Uni. Fac. of Vet. Med. Giessen, Germany.
Prof. Dr. Gülay ÇİFTÇİ, Ondokuz Mayıs Üniv.. Vet. Fak. Samsun, Türkiye.
Prof. Dr. Halil Selçuk BİRİCİK, Afyon Kocatepe Üniv. Vet. Fak. Afyonkarahisar, Türkiye.
Prof. Dr. Hasan EREN, Aydın Adnan Menderes Üniv. Vet. Fak. Aydın, Türkiye.
Prof. Dr. Kazım ŞAHİN, Fırat Üniv. Vet. Fak. Elazığ, Türkiye.
Prof. Dr. Manzoor Ur Rahman MIR, SKUAST Kashmir Fac. of Vet. Sci. & Anim. Husbandry. Kashmir, India.
Prof. Dr. Mehmet Emin TEKİN, Selçuk Üniv. Vet. Fak. Konya, Türkiye.
Prof. Dr. Muammer GÖNCÜOĞLU, Ankara Üniv. Vet. Fak. Ankara, Türkiye.
Prof. Dr. Murat YILDIRIM, Kırıkkale Üniv. Vet. Fak. Kırıkkale, Türkiye.
Prof. Dr. Narin LİMAN, Erciyes Üniv. Vet. Fak. Kayseri, Türkiye.
Prof. Dr. Osman KUTSAL, Ankara Üniv. Vet. Fak. Ankara, Türkiye.
Prof. Dr. Rahşan ÖZEN, Fırat Üniv. Vet. Fak. Elazığ, Türkiye.
Doç. Dr. Bengi ÇINAR KUL, Ankara Üniv. Vet. Fak. Ankara, Türkiye.
Doç. Dr. İlknur PİR YAĞCI, Kırıkkale Üniv. Vet. Fak. Kırıkkale, Türkiye.
Prof. Assoc. Dr. Sokol DURO, Agricultural University of Tirana. Fac. of Vet. Med. Tirana, Albania.
Dr. Kushvar Mammadova, Azerbaijan State Agricultural Univ, Fac. of Vet. Med. Gence Azerbaijan.
Dr. Tomasz Szara, Institute of Veterinary Medicine. Warsaw, Poland.

Harran Üniversitesi Veteriner Fakültesi Dergisi
2024 Yılı 13. Cilt 1. Sayı Hakem Listesi (alfabetik sıra)
The Referees List of This Issue (in alphabetical order)

Prof. Dr. Canker Çağrı CINGI	Afyon Kocatepe Üniversitesi Veteriner Fakültesi
Prof. Dr. Cansel Güzin Özgüden AKKOÇ	Bursa Uludağ Üniversitesi Veteriner Fakültesi
Prof. Dr. Dilek ÖZTÜRK	Burdur Mehmet Akif Ersoy Üniversitesi Veteriner Fakültesi
Prof. Dr. Emel ALAN	Erciyes Üniversitesi Veteriner Fakültesi
Prof. Dr. Emine KARAKURUM	Burdur Mehmet Akif Ersoy Üniversitesi Veteriner Fakültesi
Prof. Dr. Engin BALIKÇI	Fırat Üniversitesi/Veteriner Fakültesi
Prof. Dr. Gonca Ozan KOCAMÜFTÜOĞLU	Burdur Mehmet Akif Ersoy Üniversitesi Veteriner Fakültesi
Prof. Dr. Gülsün PAZVANT	İstanbul Üniversitesi-Cerrahpaşa Veteriner Fakültesi
Prof. Dr. Leyla VATANSEVER	Kafkas Üniversitesi Veteriner Fakültesi
Prof. Dr. Nalan GÖKOĞLU	Akdeniz Üniversitesi Su Ürünleri Fakültesi
Prof. Dr. Nilgün KURU	Sivas Cumhuriyet Üniversitesi Veteriner Fakültesi
Prof. Dr. Nuri MAMAK	Burdur Mehmet Akif Ersoy Üniversitesi Veteriner Fakültesi
Prof. Dr. Öznur ASLAN	Erciyes Üniversitesi Veteriner Fakültesi
Prof. Dr. Sadık YAYLA	Dicle Üniversitesi Veteriner Fakültesi
Prof. Dr. Turgay ŞENGÜL	Bingöl Üniversitesi Ziraat Fakültesi
Prof. Dr. Ufuk Tansel ŞİRELİ	Ankara Üniversitesi Veteriner Fakültesi
Prof. Dr. Yakup Can SANCAK	Van Yüzüncü Yıl Üniversitesi Veteriner Fakültesi
Doç. Dr. Alper BARAN	Atatürk Üniversitesi Veteriner Fakültesi
Doç. Dr. Feray ALTAN	Dokuz Eylül Üniversitesi Veteriner Fakültesi
Doç. Dr. Funda YİĞİT	İstanbul Üniversitesi-Cerrahpaşa Veteriner Fakültesi
Doç. Dr. Özgül GÜLAYDIN	Siirt Üniversitesi Veteriner Fakültesi
Doç. Dr. Ruhi TÜRKMEN	Afyon Kocatepe Üniversitesi Veteriner Fakültesi
Doç. Dr. Saime Betül BAYGELDI	Fırat Üniversitesi Veteriner Fakültesi
Doç. Dr. Semih ALTAN	Dokuz Eylül Üniversitesi Veteriner Fakültesi
Doç. Dr. Semime DALGA	Kafkas Üniversitesi Veteriner Fakültesi
Dr. Öğr. Üyesi Ali GÜLAYDIN	Siirt Üniversitesi Veteriner Fakültesi
Dr. Öğr. Üyesi Ayşe KANICI TARHANE	Kafkas Üniversitesi Veteriner Fakültesi
Dr. Öğr. Üyesi Büşra KİBAR KURT	Aydın Adnan Menderes Üniversitesi Veteriner Fakültesi
Dr. Öğr. Üyesi Cavidan Gül VARİŞ	Adıyaman Üniversitesi Kahta Meslek Yüksekokulu
Dr. Öğr. Üyesi Gonca SÖNMEZ	Selçuk Üniversitesi Veteriner Fakültesi
Dr. Öğr. Üyesi Sedat AYDOĞDU	Selçuk Üniversitesi Veteriner Fakültesi

İçindekiler / Contents

Araştırma Makaleleri / Research Articles		Sayfa /Page
1.	Investigation of Ivermectin Susceptibility in Kangal and Akbaş Dogs via MDR1 Gene Mutation Kangal ve Akbaş Irkı Köpeklerde MDR1 Gen Mutasyonu Üzerinden İvermektine Duyarlılığın Araştırılması Emine BAYDAN, Bengi ÇINAR KUL, Mustafa Yenal AKKURT, Ebru YILDIRIM, Emre ARSLANBAŞ, Farah Gönül AYDIN	001-007
2.	Ördeklere Farklı Dozlarda Tolfenamik Asit Uygulamasının Biyokimyasal Parametrelere Etkisi Effect of Different Doses of Tolfenamic Acid Administration to Ducks on Biochemical Parameters Orhan ÇORUM, Devran COŞKUN, Murat KARAHAN, Duygu DURNA ÇORUM	009-013
3.	Geometric morphometric analysis of New Zealand rabbit cranium Yeni Zelanda Tavşanı Cranium'unun Geometrik Morfometrik Analizi Havali AKKAYA, İftar GÜRBÜZ	014-021
4.	Investigation of Etiological Prevalence of Neonatal Calves with Acute Diarrhea in Şanlıurfa Province with Immunochromatographic Test Şanlıurfa İlindeki Akut İshalli Neonatal Buzağuların İmmunokromatografik Test ile Etiyolojik Prevalanslarının Araştırılması Canberk BALIKÇI, Erdem GÜLERSOY, Adem ŞAHAN, İsmail GÜNAL, Fatma AKDAĞ, Esmâ KİSMET, Bilal İLGİNOĞLU	022-027
5.	The effect of Hydroxytyrosol on Spexin immunoreactivity in pancreatic islets and serum insulin levels in a Streptozotocin-induced experimental diabetes model in rats Sıçanlarda Streptozotosin ile İndüklenen Deneysel Diyabet Modelinde Hidroksitirozol'ün Pankreas Adacıklarında Speksin İmmünoreaktivitesi ve Serum İnsülin Düzeyleri Üzerine Etkisi Tuba YALÇIN, Sercan KAYA	028-033
6.	A Bibliometric Analysis of Thromboelastography in Veterinary Clinical Use Veteriner Klinik Kullanımında Tromboelastografinin Bibliyometrik Analizi Oya ERALP İNAN	034-041
7.	Sıcak iklim koşullarında Linda Kazları ve Yerli Kazların (<i>Anserinae sp.</i>) Yumurta Verimi ve Doğal Kuluçka Performansı Üzerine Bir Araştırma A Study on Egg Productivity and Natural Hatching Performance of Linda Geese and Domestic Geese (<i>Anserinae Sp.</i>) Under Hot Climate Conditions Sabri YURTSEVEN, Zeliha KAYA, Mehmet ÇETİN	042-047
8.	Morphological Comparison of Larynx, Syrinx, Trachea of Some Wild Birds Bazı Yabani Kuşların Larinks, Syrinx ve Trakealarının Morfolojik Karşılaştırması Funda AKSÜNGER KARAAVCI, Ali KOÇYİĞİT, Betül KANİK	048-055
9.	Fare (Balb/C mice) ve Sıçan (Wistar Albino Rat)'da Articulatio Genus'un Karşılaştırılmalı Morfolojik İncelenmesi Comparative Morphological Examination of Articulatio Genus in Mouse (Balb/C) and Rat (Wistar Albino) Sefa YEKELER, Yonca Betil KABAK, Burcu ONUK	056-062
10.	Investigation of the Presence and Prevalence of Listeriosis in Clinical Samples in Van and its Region Van'da Klinik Örneklerde Listeriosis'in Varlığının Araştırılması Kadir AKAR, Gökçenur SANIOĞLU GÖLEN, Ali Rıza BABAOĞLU, İsmail Hakkı EKİN	063-067
11.	Capsular Tension Ring and Iris Hook Use in The Management of Cataract with Phacoemulsification Method in Dogs Köpeklerde Fakoemülsifikasyon Tekniği ile Katarakt Cerrahisinde Kapsül Germe Halkası ve İris Kancası Kullanımı Osman BULUT, Ayşe İpek AKYÜZ ÜNSAL, Ali BELGE	068-075
12.	Evaluation of Cases of Foreign Body Ingestion in the Gastrointestinal Tract of Cats: 12 Cases Kedilerde Sindirim Sistemi Kanalında Tespit Edilen Yabancı Cisim Olgularının Değerlendirilmesi: 12 Olgu Ali GULAYDIN, Mustafa Barış AKGUL	076-083



Investigation of Ivermectin Susceptibility in Kangal and Akbaş Dogs via MDR1 Gene Mutation

Emine BAYDAN^{1,a}, Bengi ÇINAR KUL^{2,b}, Mustafa Yenal AKKURT^{2,c}, Ebru YILDIRIM^{3,d}, Emre ARSLANBAŞ^{4,e,*}, Farah Gönül AYDIN^{1,f}

¹Ankara University, Faculty of Veterinary Medicine, Department of Pharmacology and Toxicology, Ankara, Turkey.

²Ankara University, Faculty of Veterinary Medicine, Department of Genetics, Ankara, Turkey.

³Kırıkkale University, Faculty of Veterinary Medicine, Department of Pharmacology and Toxicology, Kırıkkale, Turkey.

⁴Aksaray University, Faculty of Veterinary Medicine, Department of Pharmacology and Toxicology, Aksaray, Turkey.

^aORCID:0001-5459-8616;

^bORCID:0002-8955-0097;

^cORCID:0002-8139-0252;

^dORCID:0002-6289-0729;

^eORCID:0003-0030-7195;

^fORCID:0002-0068-2078.

Received: 13.09.2023

Accepted: 08.02.2024

How to cite this article: Baydan E, Çınar Kul B, Akkurt MY, Yıldırım E, Arslanbaş E, Aydın FG. (2024). Investigation of Ivermectin Susceptibility in Kangal and Akbaş Dogs via MDR1 Gene Mutation. Harran Üniversitesi Veteriner Fakültesi Dergisi, 13(1): 1-07. DOI:10.31196/huvfd.1348411.

***Correspondence:** Emre Arslanbaş

Aksaray University, Faculty of Veterinary Medicine, Pharmacology and Toxicology Department, 68100, Aksaray/Turkey.

e-mail: emre.arslanbas@aksaray.edu.tr

Available on-line at: <https://dergipark.org.tr/tr/pub/huvfd>

Abstract: This research aimed to investigate the sensitivity to the drug (ivermectin) in Kangal and Akbaş breed dogs, which are dog breeds native to Turkey, via the MDR1 gene mutation.

For the research, blood, hair and intraoral swap samples were taken from 30 Kangal and 20 Akbaş breed dogs (male-female mixed, adult) with ethical permission and approval forms. Kangal dog samples were taken from the dogs bred in the farms in Sivas center and Kangal village, and Akbaş dog samples were taken from the dogs bred in the farms in the Sivrihisar center, Ankara and Eskişehir regions. The samples taken were evaluated based on polymerase chain reaction (PCR) from the wool and subsequent two-way dideoxy chain termination reaction in the presence of 4 base pair deletions (c.296-299delAGAT) in the 4th exon of the ABCB1 gene that encodes the P-glycoprotein (P-gp) drug transporter protein.

According to the obtained DNA sequence results, the deletion of "AGAT" was not determined in any of the individuals screened. The results of this study, which is preliminary research, showed that Kangal and Akbaş breed dogs are safe in terms of sensitivity to drugs that are set to be absorbed and excreted by the P-gp pump, especially ivermectin. However, it would be useful to repeat the analysis of both breeds with more examples.

Keywords: Akbaş, Ivermectin, Kangal, MDR1 mutation, Susceptibility.

Kangal ve Akbaş Irkı Köpeklerde MDR1 Gen Mutasyonu Üzerinden İvermektine Duyarlılığın Araştırılması

Özet: Bu araştırmada, Türkiye'ye özgü iki farklı ırk köpekte (Kangal ve Akbaş) ivermektine duyarlılığın gen mutasyonu (MDR1) üzerinden belirlenmesi amaçlanmıştır.

Araştırma için, etik izni ve onam formu bulunan 30 adet Kangal ve 20 adet Akbaş ırkı köpekten (erkek dişi karışık, erişkin) kan, kıl ve ağız içi svap örneği alınmıştır. Kangal köpek örnekleri Sivas merkez ve Kangal köyünde yetiştirilen çiftliklerdeki köpeklerden, Akbaş köpek örnekleri ise, Sivrihisar merkez, Ankara ve Eskişehir bölgesindeki çiftliklerde yetiştirilen köpeklerden alınmıştır. Alınan örnekler P-glycoprotein (P-gp) drug transporter proteinini kodlayan ABCB1 (MDR1) geninin 4. ekzonunda 4 baz çiftlik delesyonun (c.296-299delAGAT) varlığı yönünden Polimeraz Zincir Reaksiyonu (PZR) ve takiben çift yönlü dideoksi zincir sonlanma reaksiyonuna göre değerlendirilmiştir.

Elde edilen DNA dizi sonuçlarına göre "AGAT" delesyonu taranan hiçbir köpekte belirlenmemiştir. Bir ön araştırma niteliğinde olan bu çalışmanın sonuçları, Kangal ve Akbaş ırkı köpeklerin başta ivermektin olmak üzere P-gp pompası ile emilme ve atılmaları ayarlanan ilaçlara karşı duyarlılık yönünden güvende olduklarını göstermiştir. Ancak, her iki ırka ait analizlerin daha çok örnekle tekrarlanması yararlı olacaktır.

Anahtar Kelimeler: Akbaş, Duyarlılık, İvermektin, Kangal, MDR1 mutasyonu.

Introduction

Kangal (Karabaş), Akbaş Çoban, Karayaka and Kars (Kafkas) Çoban dogs are some of the shepherd dogs native to Turkey. The most well-known and world-renowned of these dog breeds are the Kangal dogs, whose breed characteristics are best preserved (Yıldırım, 2012). Kangal dog is known as Anatolian Shepherd Dog abroad. In Turkey, although there are five different shepherd dog breeds, only three of which are registered (Kangal, Akbaş, Kars) and two of which are not yet registered (Sheep and Karaman shepherd Dogs). Kangal dog was registered as a breed by the Turkish Standards Institute with the number 11471 TS 12891 on 27.11.2002 (Yılmaz et al., 2015). In a study to understand the genetic relationship between Kangal dogs, Akbaş dogs and dogs from different regions of Eurasia, a 585 base pair segment of the mitochondrial DNA control region from Kangals and Akbaş was sequenced. When the sequences of Kangal and Akbaş dogs were compared with previous studies in dogs, it was reported that the results showed that Kangal and Akbaş dogs may have come from different maternal origins (Koban et al., 2009). In another study, the genetic diversity of Kangal dogs was analyzed using 100 canine microsatellites, and when the results were compared with Central Anatolian feral dogs, Akbaş dogs and Turkish greyhounds, it was reported that Kangal, Akbaş, Turkish greyhounds and feral dogs were significantly different from each other according to FST measurement (Altunok et al., 2005). Kangal dog is a dog breed that has an important place among Turkish shepherd dogs, which is compatible with the cold and less humid climatic conditions that Turks brought with them during their migration from Central Asia to Anatolia (Atasoy et al., 2005; Çoban et al., 2011; Yılmaz et al., 2012). It is grown all over Anatolia, especially Sivas (Ministry of Agriculture and Rural Affairs, 2009; Yıldırım, 2012). It has been reported that they were much more successful in Turkey in 1975 than other dog breeds that were trained for military purposes and bred for many years (Erol, 2008).

The natural habitat of Akbaş, another shepherd and guard dog breed unique to Turkey, is Sivrihisar, Afyon, Eskişehir, Polatlı and Ankara. There are two types of Akbaş, long and short hairy. They are adapted to the continental climate (Atasoy et al., 2011; Ministry of Agriculture and Rural Affairs, 2009). Akbaş dog was registered as a breed by the Turkish Standards Institute on 27.11.2002 with the number 11471 TS 12891 (Yılmaz et al., 2012). The Akbaş dog, unlike the Kangal dog, is insufficiently known in Turkey. However, its cultivation is becoming widespread day by day in some countries, especially in America. In a study conducted in America, Akbaş was found to be the most successful dog breed in herd protection (Tepeli et al., 2003).

Pharmacoepidemiology related to pharmacogenetics is an important sub-branch of pharmacology and examines the change in drug response due to genetic differences in individuals (Upadhyay et al., 2019). Dosage, type, age, gender and race are important factors in the effectiveness of a drug. Pharmacogenetics focuses on individual differences in responses to drugs at the same dose and determines individualized drugs and doses (Elewa and Awaisu, 2019).

Parasite control in animals is carried out with the use of appropriate anthelmintic drugs. Ivermectin, a drug of the avermectin group, is widely used due to its action on internal and external parasites, its safety index and wide effectiveness. However, in some dog breeds there is sensitivity even to low doses of this drug due to genetic mutation (MDR1/ABCB1) (Hürlimann et al., 2023; Mealey et al., 2023). In some dog breeds (Sheltie, Australia Shepherd), especially dogs of the Collie breed, ATP-binding cassette, subfamily B (MDR/TAP), member 1 gene (ABCB1), better known as the sensitivity of ivermectin, which is characterized by the mutation of the 4-base pair in the 4th exon (Löscher, 2023). This gene encodes the transporter P-glycoprotein (Permeability glycoprotein; P-gp), which acts as a transmembrane protein pump. These carrier proteins are expressed in various tissues such as tumor cells, brain capillaries, endothelial cells, intestinal epithelium cells, kidney proximal tubular epithelium cells, spinal cord, placenta and testicular cells, and strongly affect the absorption and excretion of certain drugs, especially ivermectin, which is a macrocyclic lactone (ML) (Erkens et al., 2009; Linardi and Natalini, 2006). These carrier proteins, especially those found in the blood-brain barrier, act as a pump for the removal of drug molecules from the central nervous system (CNS). Since the blood-brain barrier is not sufficiently developed (the pump does not work well) in susceptible breeds, there is sensitivity due to the release of gamma-aminobutyric acid (GABA) in the drug-related CNS. Dogs of the Collie breed are sensitive to even as low as 0.1 mg/kg of ivermectin compared to other dogs. Brain concentrations of ivermectin were found to be much higher in dogs with sensitivity and this was associated with limited P-gp expression (Janko and Geyer, 2013; Turner, 2005). Pgp deficiency causes excessive permeability of the blood-brain barrier and leads to the accumulation of ivermectin in the brain (Mealey et al., 2001). This situation results in the ivermectin acting on GABA-mediated chlorine channels and the death of the sensitive individual (Beckers et al., 2022). Regarding the MDR1 mutation in dog breeds, sensitivity to drugs such as acepromazine, butorphanol, cyclosporine, digoxin, doxorubicin, loperamide, vinblastine, vincristine is also mentioned, apart from ivermectin (Geyer and Janko, 2012). There are several studies to identify the MDR1 mutation in dogs (Beckers et al., 2022; Dekel et al., 2017; Kawabata et al., 2005; Tappin et al., 2012). Also, Gramer et al. (2011) examined the samples collected without separating the dogs into breeds such as Akbaş, Kangal, and Kars, in terms of MDR1 mutation under the name Anatolian Shepherd Dogs.

In this research, it was aimed to screen for 4-base deletion mutations in the 4th exon of the MDR1 gene (c.296_299delAGAT) in samples taken separately from registered Kangal and Akbaş dog breeds specific to Turkey by PCR/Sequence analysis method and to protect these breeds in pharmacogenetic context with conscious drug applications in case of possible mutations.

Materials and Methods

Obtaining biological samples and DNAs: In the research, blood, hair and intraoral swab samples were taken from 30 Kangal bred in Sivas center and Kangal village and 20 Akbaş breed in Sivrihisar centers, Ankara and Eskişehir regions bred dogs (male-female mixed, adult), which were decided by the "Ankara University Animal Experiments Local Ethics Committee" (Decision; Date.10.02.2016, No. 2016-3-21), were used. Information about the pedigrees of the dogs was obtained from the owners of the animals, whose informed consent was signed for the study, and it was confirmed that they were not related for at least 3 generations, and their photographs were taken. Blood samples in the amount of 4-5 ml were taken from the *Vena saphena* or *Vena femoralis* of Kangal dogs into sterile needle-tipped vacuum EDTA tubes to represent each animal (n=30). Hair samples consisting of 5-6 hair bulbs were taken from interscapular area or intraoral swab samples were obtained from the buccal area to represent each animal, because of Akbaş dogs with an aggressive temperament or there is difficulty in taking a sample through a vein (n=20). The biological samples were transported to Ankara University Veterinary Medicine Faculty Genetics Department Molecular Genetics Laboratory under the cold chain (at +4°C). Blood samples were stored at -20°C, while swabs and hairs were at +4°C until the DNA isolation stage.

DNA isolation was performed with a commercial column-based kit (QIAamp DNA Mini Kit, cat. no. 51304, Qiagen, Germany), in accordance with the manufacturer's recommendations for all sample types. The integrity of the obtained DNAs was first checked by running under 90 volts electric current in 0.8% agarose gel electrophoresis stained with non-carcinogenic fluorescent dye (SafeView, Abmgood, cat. no. G108, Canada), then the amount and purity were determined by measuring with the spectrophotometric method Nanodrop (NanoDrop 2000, Thermo Fisher) device. After checking the purity and integrity of the DNAs, the DNA concentration of the isolates was diluted to 50 ng/µl and stored at -20°C until PCR processes.

Polymerase chain reaction: A pair of primer sets are designed to raise mutant and wild alleles in the elevation of the 4th exon of the MDR1 gene. Based on the reference genome sequence in primer design (*Canis lupus familiaris* breed boxer chromosome 14, CanFam3.1, whole genome shotgun sequence, GenBank accession code NC_006596.3:13725500-13727000 and Ensembl accession code ENSCAFG00845007972), "Primer3 (v.0.4.0)" (Koressaar and Remm, 2007) program was used. The primers used were indicated in Table 1.

In order to determine the binding conditions of the

primers, graded (gradient) PCR was established at different temperatures (52-62°C range) and MgCl₂ conditions (1.5 and 2.5 mM). PCR procedures were performed with the Biorad C1000 Thermal Cycler located in the Molecular Genetics Laboratory, Department of Genetics, Veterinary Medicine Faculty, Ankara University. For this purpose, PCR 50 ng DNA, 1X buffer, 1.5-2.5 mM MgCl₂, dNTP (200 µM), forward and backward primers (5 pmol) and Taq DNA polymerase (1 U) were completed with ddH₂O to a total volume of 25 µl. In order to determine the optimal binding temperature, 5 min at 95°C following the first denaturation, 30 sec at 95°C, 30 sec at 52-62°C range, 30 sec at 72°C were repeated at 39 cycles, and at 72°C 10 min final elongation was performed. PCR products were stained with non-carcinogenic fluorescent dye (SafeView, Abmgood, cat. no. G108, Canada), run under 120 volt electric current in 2% agar gel electrophoresis, then visualized under UV light with KODAK Gel Logic 200 device. The obtained PCR products were stored at -20°C until the purification and sequence analysis stage.

Purification of PCR products and DNA Sequence

Analysis: PCR products were purified using a commercial kit (QIAquick PCR Purification Kit, cat. no 28104, Qiagen, Germany) before sequence analysis, and thus removing PCR residues.

The dideoxy chain termination reaction was established in accordance with the manufacturer's recommendations with the sequencing kit (BigDye™ Terminator v3.1 Cycle Sequencing Kit, cat. no 4337457) separately, with the forward and backward primers used in PCR at a concentration of 1.6 picomoles. Sequence PCR products were carried out in polyacrylamide gel capillary electrophoresis in ABI310 (Applied Biosystems, USA) device and bidirectional DNA sequences were obtained according to fluorescent light waves by laser system. Sequences (Hall, 1999) were aligned according to the reference sequence (Ensembl access code ENSCAFG00845007972) in the package program and consensus sequences were obtained. At the same time, electropherogram images related to sequences were checked with the eye in order to verify device readings.

Results

PCR results: The results of the gradient PCR performed to determine the appropriate PCR conditions are given in Figure 1. Accordingly, the optimal condition was obtained at a concentration of 2.5 mM MgCl₂ and a binding temperature of 56°C (Figure 1). Then, PCR was applied to all samples at optimum temperature and MgCl₂ concentration (Figure 2), and after purification, dideoxy chain termination reaction was performed.

Table 1. MDR1 gene primers and expected amplicon size.

Primary	Sequence, 5'-3'	Amplicon Size (bp)
Forward	CGCTATTCAAATTGGCTTG	245 (wild) / 241 (mutant)
Backward	AATGAGGGCTAAACATCCTT	

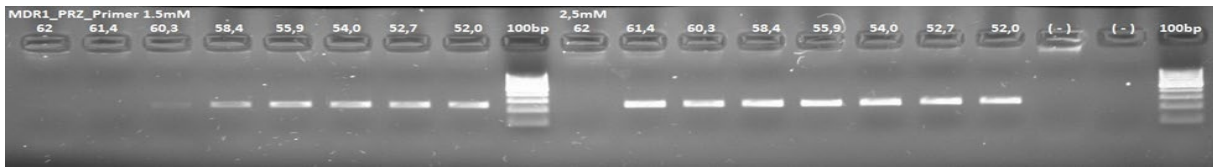


Figure 1. Gradient PCR experiment with concentration of 1.5 and 2.5 mM MgCl₂ and primary binding conditions at 62-52°C. Wells 9 and 20 show the 100 bp DNA ladder, and wells 18 and 19 show the negative control with water.

DNA sequence analysis results: The electropherogram image and alignment results of some samples were presented in Figure 2 and Figure 3, respectively. Accordingly, when the DNAs obtained from Kangal and Akbaş breed dogs

was bi-directional read backwards and forward with the primer and aligned according to the reference gene, it was determined that all the DNAs had a wild-type sequence and did not carry the corresponding mutation.

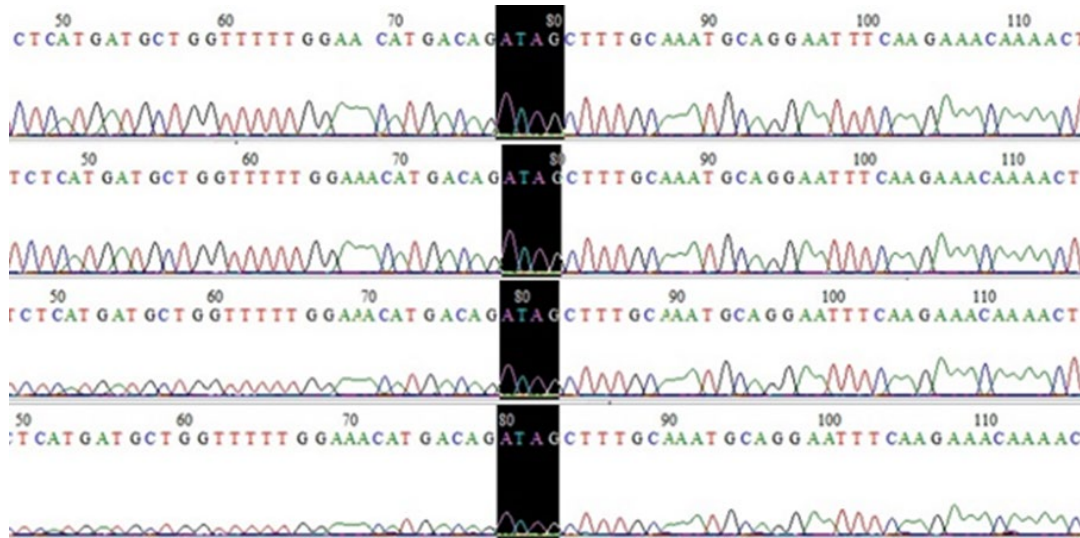


Figure 2. Corresponding electropherogram image of the MDR1 gene. The black area shows the mutation expected region.




Figure 3. View of the sequences aligned in BioEdit according to reference sequence NC_006596.3.

Discussion and Conclusion

Differences in efficacy or toxic effects of a drug between individuals are determined by genetic polymorphisms in drug-metabolizing enzymes, drug receptors, or drug

transporters (Mealey and Meurs, 2008). While the importance of pharmacogenetics in humans is seriously emphasized, it is still in its infancy in veterinary medicine. The issue that draws attention to pharmacokinetics in veterinary medicine is the sensitivity to ivermectin in Collie

dogs and its association with the mutation in the MDR1 gene, which encodes the membrane carrier P-gp (Martinez et al., 2008). The most striking example of pharmacogenetics in dogs is the drug transporter P-gp. The P-gp protein, which is a part of the blood-brain barrier and acts as an important barrier to the passage of drugs to certain tissues, especially the brain, is encoded by the MDR1 gene (Mealey and Meurs, 2008). In addition to dogs, the MDR1 gene has also been recorded in mice, rats, ruminants, monkeys and humans (Asawakarn et al., 2012). The sensitivity/toxicity situation that has developed against ivermectin and some other drugs due to MDR1 mutation in some dog breeds (Geyer and Janko, 2012), especially collie dogs (Beckers et al., 2022), has caused a focus on the issue on a country-by-country basis and dog breeds to be screened from this point of view. In a scan conducted in Brazil, doxorubicin toxicity developed in a cross-breed dog and MDR1 mutation (c.296_299delAGAT) in the dog was shown as the cause (Monobe et al., 2013). MDR1 mutation was also detected in the analyses performed on Australian Shepherd, Collie, Shetland Sheepdog and Swiss White Shepherds in Belgium (Erkens et al., 2009). In a study conducted in Germany to determine the presence and frequency of the nt230 (del4) MDR1 mutation in dogs, the frequency of homozygous mutated genotypes in 1500 dogs scanned was highest in the Collie breed (33.0%), followed by the Australian Shepherd Dog (6.9%) and Shetland Sheepdog (5.7%). Screening revealed heterozygosity for the mutant MDR1 (-) allele in Waller dogs (37%) and Old English Sheepdogs (12.5%) (Geyer et al, 2005). In Brazil, 103 Collies, 77 Border Collies, 76 Shetland Shepherd Dogs, 20 Old English Shepherd Dogs, 55 German Shepherd Dogs, 16 Australian Shepherd Dogs and 53 Whippet Dogs were screened for MDR1 mutation. As a result of the study, the frequency of heterozygous mutated genotype MDR1 (+/-) in Collies, Australian Shepherds and Shetland Shepherds was determined as 50.5%, 31.3% and 15.8%. The presence of homozygous mutated genotype MDR1 (-/-) has been reported to be 35.9% only in Collies (Monobe et al, 2015). In a retrospective study covering a 5-year period in Italy, the detection status of the MDR1 mutated allele in dog populations (811 dogs) was attempted to be determined. At the end of the research, it was reported that the presence of mutated alleles was detected in 9 of 31 breeds (Rough Collie, Smooth Collie, Border Collie, Bearded Collie, Shetland Shepherd Dog, Australian Shepherd Dog, White Swiss Shepherd Dog, Old English Shepherd Dog, Whippet and also in hybrids) (Marelli et al., 2020). In a study conducted in Portugal, among 105 dogs of different breeds scanned (23 Barbado da Terceira, 10 Cão da Serra d'Aires, 55 carrying mutations, Australian Shepperd, Border Collie etc., 17 Labrador Retriever, Jack Russel) and it has been reported that the presence of mutation was detected for the first time in the Terceira breed in Barbado (Barroso et al, 2022). Similarly, in a study in Thailand in which MDR1 gene mutation was tried to be determined in 263 dogs belonging to eight purebred dog breeds using the allele-specific multiplex PCR method and direct DNA sequencing, the mutant allelic frequency was determined for Australian Shepherd Dogs, Shetland Shepherd Dogs and Old English

Shepherd Dogs were 57.14%, 12.82%, 11.28% and 8.33%, respectively (Lerdkrai and Phungphosop, 2021).

On the other hand, MDR1 mutation was not found in Uruguay Cimmaron dogs by Rosa Gagliardi et al. (2013), German Shepherd, Doberman, Border Collie and Greyhound breed dogs (total 95 dogs) by Rosa Gagliardi et al. (2015) and Bearded Collies and German Shepherds breed dogs in the screenings of 92 dogs in Belgium by Erkens et al. (2009).

In population scans, the percentage of heterozygosity or allele frequency is usually taken into account. In the case of heterozygosity, which means the coexistence of a mutant allele and a wild allele, P-gp deficiency is less severe than homozygous mutants and may be clinically overlooked. Especially in homozygous dogs (MDR1 mutant/mutant), the passage of Pgp-dependent drugs to the brain is greater than in heterozygous dogs (MDR1 mutant/normal). Mealey et al. (2001) reported that there is a relationship between ivermectin sensitivity and deletion mutation of the MDR1 gene and that while dogs homozygous for the deletion mutation show sensitivity to ivermectin, homozygous normal or heterozygous dogs do not show increased sensitivity to ivermectin. In a study by Mealey and Meurs (2008), the presence of mutation was investigated in 5368 dogs, including 140 pure breeds and their hybrids, and the dog breeds with the highest percentage of heterozygosity were determined as Longhaired Whippet (58%) and Collie (42%). While the Collie breed dogs were represented by 1424 dogs, the Longhaired whippet breed was evaluated with only 24 dogs in this study, when the mutant allele frequency in the population was calculated by including homozygous mutants, values of 29% and 56% were obtained, respectively and high heterozygosity value was interpreted to be close inbreeding and working with less samples. In this study, 10 Akbaş dogs were also examined and no mutations were found. In another study by Gramer et al. (2011), the highest allelic frequency value was found to be 59% in Collies, 45% in Longhaired whippet and 30% in Shetland sheepdog breed in 7378 dogs consisting of 106 pure breeds and hybrids. However, the MDR1 nt230(del4) mutation has not been determined in some breeds, including the Anatolian shepherd dog breed, and it has been found that it is much rarer in some breeds.

In this study, which was carried out to determine the 4-base deletion mutation in the 4th exon of the MDR1 gene (c.296_299delAGAT) in blood, hair and intraoral swap samples of 30 Kangal and 20 Akbaş dog breeds native to Turkey by PCR/sequence analysis method, a mutation status could not be determined in either Akbaş or Kangal breed dogs (Figure 2 and 3). In the study conducted on Uruguayan Cimarron dogs, a relationship was established between not applying to the clinic for ivermectin toxicity and the absence of mutations in these breeds (Gagliardi et al., 2013). Since there is no retrospective study on the toxicity or sensitivity of ivermectin related to these breeds native to Turkey, such a relationship could not be established. However, it is thought that increasing the number of samples and increasing the frequency of controls will be useful in terms of clarifying the mutation status in special breeds.

Conflict of Interest

The authors stated that they did not have any real, potential or perceived conflict of interest.

Ethical Approval

This study was approved by the Ankara University Animal Experiments Local Ethics Committee (10.02.2016, 2016-3-21 Number Ethics Committee Decision). In addition, the authors declared that Research and Publication Ethical rules were followed.

Funding

This work has been supported by Ankara University Scientific Research Projects Coordination Unit under grant number 17B0239002.

Similarity Rate

We declare that the similarity rate of the article is 15% as stated in the report uploaded to the system.

Acknowledgment

This work has been supported by Ankara University Scientific Research Projects Coordination Unit under grant number 17B0239002.

Author Contributions

Motivation / Concept: EB

Design: EB

Control/Supervision: EB

Data Collection and/or Processing: BÇK, MYA, EY, EA, FGA

Analysis and / or Interpretation: EB, BÇK, MYA, EY

Literature Review: EB, BÇK, EY, EA

Writing the Article: EB

Critical Review: BÇK, EY, EA

References

- Altunok V, Koban E, Chikhi L, Schaffer A, Pedersen NC, Nizamlioglu M, Togan I, 2005: Genetic evidence for the distinctness of Kangal dogs. *Bull Vet Inst Pulawy*, 49(2), 249-254.
- Asawakarn S, Ruangchaiprakarn V, Srisowanna N, Wongwan L, Kanuengthong A, Suriyaphol G, 2012: Determination of multidrug resistance (MDR1) gene and its mutations in dogs by using polymerase chain reaction. *Thai J Vet Med*, 42(1), 37-42.
- Atasoy F, Uğurlu M, Özarslan B, Yakan A, 2011: Halk elinde yetiştirilen Akbaş köpeklerinde canlı ağırlık ve vücut ölçüleri. *Ankara Üniv Vet Fak Derg*, 58, 213-215.
- Atasoy F, Ünal N, Kanlı O, Yakan A, 2005: Damızlık Kangal köpeklerinde canlı ağırlık ve bazı vücut ölçüleri. *Lalahan Hay Araşt Enst Derg*, 45(1), 33-39.
- Beckers E, Casselman I, Soudant E, Daminet S, Paepe D, Peelman L, Broeckx BJ, 2022: The prevalence of the ABCB1-1Δ variant in

a clinical veterinary setting: The risk of not genotyping. *Plos one*, 17(8), e0273706.

- Barroso MC, Grilo A, Aguiar S, Aires da Silva F, São Braz B, 2022: Occurrence of MDR1 1-delta mutation in herding dog breeds in Portugal. *Front Vet Sci*, 9, 990884.
- Çoban Ö, Yıldız A, Sabuncuoğlu N, Laçın E, Yıldırım F, 2011: Kangal Köpeği yavrularında vücut ağırlığı değişimlerinin tanımlanmasında doğrusal olmayan büyüme modellerinin kullanılması. *Atatürk Üniv Vet Bil Derg*, 6(1), 17-22.
- Dekel Y, Machluf Y, Stoler A, Aderet A, Baumel D, Kellerman E, Plotsky Y, Noked Partouche O, Elhalal G, Ben-Shlomo I, 2017: Frequency of canine nt230 (del4) MDR1 mutation in prone pure breeds, their crosses and mongrels in Israel-insights from a worldwide comparative perspective. *BMC vet res*, 13(1), 1-8.
- Elewa H, Awaisu A, 2019: Pharmacogenomics in pharmacy practice: Current perspectives. *Integr Pharm Res Pract*, 8, 97-104.
- Erkens T, Daminet S, Rogiers C, Gommeren K, Lampo E, Vander Donckt D, Van den Broeke A, Van Poucke M, Van Zeveren A, Peelman LJ, 2009: Presence of the ABCB1 (MDR1) deletion mutation causing ivermectin hypersensitivity in certain dog breeds in Belgium. *Vlaams Diergeneeskundig Tijdschrift*, 78(4), 256-260.
- Erol B, 2008: Kangal köpeklerinde bazı faktörlerin dölverimi, yaşama gücü ve büyüme üzerine etkisi. Doctoral dissertation, University of Ankara.
- Gagliardi R, García GC, Llambí DS, Arruga LM, 2013: Analysis of mdr1-1Δ mutation of MDR1 gene in the "Cimarron Uruguayo" dog. *Rev MVZ Córdoba*, 18(2), 3480-3483.
- Gagliardi R, Martínez AD, Tellechea HB, Sitjar QP, Llambí DS, Arruga LM, 2015: The search for the mdr1-1Δ mutation of the MDR1 gene in four canine breeds in Uruguay (preliminary study). *Rev MVZ Córdoba*, 20(1), 4482-4487.
- Geyer J, Döring B, Godoy JR, Leidolf R, Moritz A, Petzinger E, 2005: Frequency of the nt230 (del4) MDR1 mutation in Collies and related dog breeds in Germany. *J Vet Pharmacol Therap*, 28(6), 545-551.
- Geyer J, Janko C, 2012: Treatment of MDR1 mutant dogs with macrocyclic lactones. *Curr pharm biotechnol*, 13(6), 969-986.
- Gramer I, Leidolf R, Döring B, Klintzsch S, Krämer EM, Yalcin E, Petzinger E, Geyer J, 2011: Breed distribution of the nt230 (del4) MDR1 mutation in dogs. *Vet J*, 189(1), 67-71.
- Hall TA (1999). BioEdit: a user-friendly biological sequence alignment editor and analysis program for Windows 95/98/NT. In: *Nucleic acids symposium series*. (Vol. 41, No. 41), 95-98, Information Retrieval Ltd., London.
- Hürlimann E, Hofmann D, Keiser J, 2023: Ivermectin and moxidectin against soil-transmitted helminth infections. *Trends Parasitol*, 39(4), 272-284.
- Janko C, Geyer J, 2013: Moxidectin has a lower neurotoxic potential but comparable brain penetration in P-glycoprotein-deficient CF-1 mice compared to ivermectin. *J Vet Pharmacol Ther*, 36(3), 275-284.
- Kawabata A, Momoi Y, Inoue-Murayama M, Iwasaki T, 2005: Canine mdr1 gene mutation in Japan. *J vet med sci*, 67(11), 1103-1107.
- Koban E, Saraç ÇG, Ağan SC, Savolainen P, Togan İ, 2009: Genetic relationship between Kangal, Akbash and other dog populations. *Discrete Appl Math*, 157(10), 2335-2340.
- Koressaar T, Remm M, 2007: Enhancements and modifications of primer design program Primer3. *Bioinformatics*, 23(10), 1289-1291.
- Lerdkrai C, Phungphosop N, 2021: Prevalence of the MDR1 gene mutation in herding dog breeds and Thai Ridgebacks in Thailand. *Vet World*, 14(11), 3015-3020.

- Linardi RL, Natalini CC, 2006: Multi-drug resistance (MDR1) gene and P-glycoprotein influence on pharmacokinetic and pharmacodynamic of therapeutic drugs. *Ciênc Rural*, 36, 336-341.
- Löscher W, 2023: Is the antiparasitic drug ivermectin a suitable candidate for the treatment of epilepsy?. *Epilepsia*, 64(3), 553-566.
- Marelli SP, Polli M, Frattini S, Cortellari M, Rizzi R, Crepaldi P, 2020: Genotypic and allelic frequencies of MDR1 gene in dogs in Italy. *Vet Rec Open*, 7(1), e000375.
- Martinez M, Modric S, Sharkey M, Troutman L, Walker L, Mealey K, 2008: The pharmacogenomics of P-glycoprotein and its role in veterinary medicine. *J Vet Pharmacol Therap*, 31(4), 285-300.
- Mealey KL, Bentjen SA, Gay JM, Cantor GH, 2001: Ivermectin sensitivity in collies is associated with a deletion mutation of the *mdr1* gene. *Pharmacogenetics*, 11, 727-33.
- Mealey KL, Meurs KM, 2008: Breed distribution of the ABCB1-1Δ (multidrug sensitivity) polymorphism among dogs undergoing ABCB1 genotyping. *J Am Vet Med Assoc*, 233(6), 921-924.
- Mealey KL, Owens JG, Freeman E, 2023: Canine and feline P-glycoprotein deficiency: What we know and where we need to go. *J Vet Pharmacol Therap*, 46(1), 1-16.
- Ministry of Agriculture and Rural Affairs, 2009: Türkiye Evcil Hayvan Genetik Kaynakları Tanıtım Kataloğu. Birinci Basım. <http://www.tarim.gov.tr/TAGEM/Belgeler/yayin/Katalog%20T%C3%BCrk%C3%A7e.pdf>
- Monobe MM, Junior JPA, Lunsford KV, Silva RC, Bulla C, 2015: Frequency of the MDR1 mutant allele associated with multidrug sensitivity in dogs from Brazil. *Vet Med (Auckl)*, 6, 111-117.
- Monobe MM, Lunsford KV, Araújo Júnior JP, Bulla C, 2013: Detection of heterozygous MDR1 nt230 (del4) mutation in a mixed-breed dog: case report of possible doxorubicin toxicosis. *Vet Med*, 4, 35-38.
- Tappin S, Goodfellow M, Peters I, Day M, Hall E, Mealey K, 2012: Frequency of the mutant MDR1 allele in dogs in the UK. *Vet Rec*, 171(72), 10.1136.
- Tepeli C, Çetin O, İnal Ş, Kırıkçı K, Yılmaz A, 2003: Kangal ve Akbaş Irkı Türk Çoban Köpeklerinde Büyüme Özellikleri. *Turk J Vet Anim Sci*, 27(4), 1011-1018.
- Turner T, 2005: Prescribing for dogs, Prescribing for cats In: The Veterinary Formulary, Bishop Y (Ed), (Sixth Edt.), 43-45, Pharmaceutical Press, London.
- Upadhyay S, Shrivastava S, Kumar D, Kabra A, Baghel US, 2019: Pharmacoepidemiology: A review. *AJPRD*, 7(2), 83-87.
- Yıldırım A, 2012: Kangal Irkı Köpeklerde Büyüme ve Beden Ölçülerine ait Özellikler. *J Inst Sci Tech*, 2(3), 117-126.
- Yılmaz O, Aktan S, Ertugrul M, 2012: Türkiye yerli ve yeni köpek ırkları. In: International Animal Science Congress of Turkish and Relatives Communities. pp: 39-52.
- Yılmaz O, Sireli HD, Ertugrul M, 2015: The shepherd dog breeds in Turkey: a survey. *ROAVS*, 5(4), 172-177.



Ördeklere Farklı Dozlarda Tolfenamik Asit Uygulamasının Biyokimyasal Parametrelere Etkisi

Orhan ÇORUM^{1,a}, Devran COŞKUN^{2,b*}, Murat KARAHAN^{3,c}, Duygu DURNA ÇORUM^{1,d}

¹Hatay Mustafa Kemal Üniversitesi, Veteriner Fakültesi, Farmakoloji ve Toksikoloji Anabilim Dalı, Hatay.

²Siirt Üniversitesi, Veteriner Fakültesi, Farmakoloji ve Toksikoloji Anabilim Dalı, Siirt.

³Hatay Mustafa Kemal Üniversitesi, Veteriner Fakültesi, Mikrobiyoloji Anabilim Dalı, Hatay.

^aORCID: 0000-0003-3168-2510;

^bORCID: 0000-0003-1151-1861;

^cORCID: 0000-0002-7024-1649;

^dORCID: 0000-0003-1567-991X;

Geliş Tarihi: 26.08.2023

Kabul Tarihi: 25.12.2023

Bu makale Nasıl kaynak gösterilir: Çorum O, Coşkun D, Karahan M, Durna Çorum D. (2024). Ördeklere Farklı Dozlarda Tolfenamik Asit Uygulamasının Biyokimyasal Parametrelere Etkisi. Harran Üniversitesi Veteriner Fakültesi Dergisi, 13(1): 8-13.
DOI:10.31196/huvfd.1350424.

***Yazışma adresi: Devran COŞKUN**

Siirt Üniversitesi, Veteriner Fakültesi, Farmakoloji ve Toksikoloji Anabilim Dalı, Siirt.

e-mail: devrancoskun@gmail.com

Online erişim adresi: <https://dergipark.org.tr/tr/pub/huvfd>

Özet: Bu çalışmanın amacı ördeklere tolfenamik asitin farklı dozlarda damar içi yolla uygulaması sonrası biyokimyasal parametrelerdeki değişimi ortaya koymaktır. Toplam 18 adet sağlıklı ördek 3 doz grubuna ayrıldı. Tolfenamik asit ördeklere 2 mg/kg, 4 mg/kg ve 8 mg/kg dozda damar içi yolla uygulandı. Kan örnekleri 0., 12., 24. ve 48. saatlerde brachial venden alındı. Kan örneklerinden elde edilen serumlardan kreatinin, üre, total protein, albümin, kolesterol, trigliserid, gamma glutamiltransferaz (GGT), alkalen fosfataz (ALP), alanin aminotransferaz (ALT) ve aspartat aminotransferaz (AST) seviyeleri otoanalizör cihazında belirlendi. Tolfenamik asitin artan dozlarda damar içi uygulaması ördekler tarafından iyi tolere edildi. Tolfenamik asitin farklı dozlardan uygulaması AST, ALP, GGT, albümin, total protein, kolesterol, üre ve kreatinin değerlerinde herhangi bir farklılığa neden olmadı ($p>0.05$). Tolfenamik asitin tüm dozları ALT ve trigliserid düzeylerinde önemli değişikliklere neden oldu ($p<0.05$). Sonuç olarak tolfenamik asit ördeklere genel olarak iyi tolere edildi. Ancak, tolfenamik asitin farklı dozlarda uygulamalarının ardından güvenilirliğinin hematolojik, moleküler ve histopatolojik sonuçlarla ortaya konulmasına ihtiyaç vardır.

Anahtar Kelimeler: Artan doz, Biyokimyasal parametreler, Ördek, Tolfenamik asit.

Effect of Different Doses of Tolfenamik Acid Administration to Ducks on Biochemical Parameters

Abstract: The objective of this study is to reveal the changes in biochemical parameters after intravenous administration of different doses of tolfenamik acid to ducks. A total of 18 healthy ducks were divided into 3 dose groups. Tolfenamik acid was administered intravenously to ducks at doses of 2 mg/kg, 4 mg/kg and 8 mg/kg. Blood samples were taken from the brachial vein at 0, 12, 24 and 48 hours. Creatinine, urea, total protein, albumin, cholesterol, triglyceride, gamma glutamyltransferase (GGT), alkaline phosphatase (ALP), alanine aminotransferase (ALT) and aspartate aminotransferase (AST) levels were determined in the autoanalyzer from the serum obtained from blood samples. Intravenous administration of increasing doses of tolfenamik acid was well tolerated by the ducks. Administration of tolfenamik acid at different doses did not cause any difference in AST, ALP, GGT, albumin, total protein, cholesterol, urea and creatinine values ($p>0.05$). All doses of tolfenamik acid caused significant changes in ALT and triglyceride levels ($p<0.05$). As a result, tolfenamik acid was generally well tolerated in ducks. However, the safety of tolfenamik acid after application at different doses needs to be demonstrated with hematological, molecular and histopathological results.

Keywords: Ascending dose, Biochemical parameters, Duck, Tolfenamik acid

Giriş

Ördek dünyanın birçok yerinde yetiştiriciliği yapılan önemli kanatlı türüdür. Ördek et ve yumurtasının önemli bir protein ve demir kaynağı olması, bakımının, idaresinin ve çevre koşullarına adaptasyonunun kolaylığı, ayrıca suda yaşayan alg, solucan, kurtçuk ve salyangoz gibi çeşitli böcek türleri ile beslenebilmesi ve tarım arazilerinin verimliliğini artırması gibi avantajlar sunar (Adzitey ve Adzitey, 2011; Coşkun ve ark., 2023; Tai ve Tai, 2001). Dejeneratif eklem hastalıkları, pre- ve postoperatif ağrılar, kas iskelet sistemi ağrıları, gaga kesimi ve bakteriyel enfeksiyonlar kanatlılarda ağırlı ve yangılı durumlara neden olabilir (Arda ve ark., 2002; Dinev, 2007; Machin, 2005). Ancak, ördek minör bir kanatlı türüdür ve düşük ekonomik kazançtan dolayı onaylı ilaç sayısı sınırlıdır. Bu durumda ihtiyaç duyulan ilaçlar diğer türlerden etiket dışı olarak kullanılır (Needham ve ark., 2007). Ancak kanatlı türlerinin anatomi ve fizyolojileri memeli türlerine göre farklıdır. Hatta kanatlı türlerinin arasında bile farklılık görülmesinden dolayı başka türlerden uyarlanan dozaj rejimi uygun olmayabilir. Bu nedenle hedef; kanatlı türlerinde ilaçların etkinliği ve güvenilirliğinin ortaya konulması gerekir.

Non-steroidal antiinflatuvar ilaç (NSAİİ)'ler sahip oldukları analjezik, antipiretik ve antiinflatuvar özelliklerinden dolayı kanatlılarda yaygın olarak kullanılır. NSAİİ'ler etkilerini arazidonik asitten prostaglandin sentezinden sorumlu siklooksijenaz enzimlerini (COX-1 ve COX-2) inhibe ederek gösterir (Hawkins, 2006). COX-1 enzimi vücutta yapısal olarak eksprese edilir ve normal fizyolojik süreçlerin sürdürülmesinde kritik öneme sahiptir. COX-2 enziminin ekspresyonu ise sitokinler, büyüme faktörleri ve diğer inflamatuvar uyaranlar tarafından uyarılabilir (Hawkey, 2001). Yapılan çalışmalarda kanatlılarda ağrı ve yangı mekanizmasında da COX-1 ve COX-2 enziminin rol aldığı rapor edilmiştir (Machin, 2005). Tolfenamik asit fenamat grubu bir NSAİİ'tir. Tolfenamik asitin COX enzimleri üzerine inhibitör etkisi türler arasında farklılık gösterir ve buzağlarda non-selektif etki gösterirken keçilerde özellikle COX-2 enzimi üzerine etki gösterir (Landoni ve ark., 1996; Sidhu ve ark., 2005; Sidhu ve ark., 2006). Tolfenamik asitin analjezik, antipiretik ve antiinflatuvar etkilerinin yanında antiendotoksik, antikanser, antibakteriyel ve Alzheimer hastalığının ilerlemesini yavaşlatıcı etkisi vardır (Ahmed ve ark., 2018; Lees ve ark., 1998). Tolfenamik asitin sığırlarda pnömoni ve mastitis, domuzlarda mastitis–metritis–agalactia sendromu ve kedi ve köpekte perioperatif ve postoperatif ağrılarda 2 ve 4 mg/kg dozlarında kullanımı onaylanmıştır (Anonim, 2023). Kanatlılarda tolfenamik asitin etkinliği ile ilgili çalışma olmamasına karşın kaz (Türk ve ark., 2021a), bildircin (Türk ve ark., 2021b) ve keklilerde (Çetin ve ark., 2022) farmakokinetiği ortaya konulmuştur. Tolfenamik asit hayvanlarda genelde 2 ve 4 mg/kg dozlarında kullanılır. Buzağı ve köpekte tolfenamik asitin etkinliğinin doza bağlı olarak arttığı bildirilmiştir (Lees ve ark., 1998; Mckellar ve ark., 1994).

NSAİİ'ler prostaglandin sentezini inhibe ettiği için uzun süre veya yüksek dozlarda kullanımları böbrek, gastrointestinal sistem ve kalp olmak üzere organ ve dokular üzerinde istenmeyen etkilere neden olabilir. Kanatlılar,

NSAİİ'lerin özellikle renal hasarına duyarlıdır ve son yıllarda akbaba popülasyonundaki azalmada bu durumun etkili olduğu bildirilmiştir (Galligan ve ark., 2020; Toutain ve ark., 2010). Tolfenamik asit akbabalarda güvenli bulunan NSAİİ'lerden birisidir. Tolfenamik asit yan etki profilinin düşük olması ve etkinliğinin güçlü olmasından dolayı ördeklerde kullanılabilir. Ancak yapılan kaynak taramasında ördeklerde tolfenamik asitin biyokimyasal parametreler üzerine etkinliği hakkında herhangi bir çalışma bulunamamıştır. Bu çalışmada ördeklere tolfenamik asitin 2, 4 ve 8 mg/kg dozda damar içi uygulaması sonrası biyokimyasal parametrelere etkisini ortaya koymak amaçlandı.

Materyal ve Metot

Hayvanlar: Araştırma, son 1 aylık dönemde herhangi bir ilaç uygulanmamış, sağlıklı 18 adet Pekin ırkı ördek (1-2 yaş, 2-3 kg) üzerinde gerçekleştirildi. Ördeklerin sağlıklı olduğuna genel klinik muayene ve davranışları gözlemlenerek karar verildi. Çalışma süresince ördekler ticari yem ile beslendi ve su *ad-libitum* olarak verildi. Ördekler 2, 4 ve 8 mg/kg dozlarını alacak şekilde rastgele 3 gruba ayrıldı. Ördekler ayaklarına halka takılarak numaralandırıldı. Gruplar 1-18'e kadar rakamların yazılı olduğu kapalı kağıtlar rastgele çekilerek oluşturuldu. Ördekler çalışma ortamına alışmaları için deneysel prosedürden 1 hafta önce çalışmanın yapılacağı kafeslere alındı. Araştırmanın deneysel süreci Hatay Mustafa Kemal Üniversitesi Hayvan Araştırmaları Yerel Etik Kurulu tarafından onaylandı (2022/03-16).

Deneysel prosedür: İlaç uygulaması için tolfenamik asitin enjeksiyonluk (Tolfine, 40 mg/mL) preparatı kullanıldı. Ördekler farklı dozları alacak şekilde rastgele 3 eşit gruba ayrıldı. Tolfenamik asit gruplara sırası ile 2 mg/kg, 4 mg/kg ve 8 mg/kg dozda damar içi (sağ brachial ven) yolla uygulandı. Kan örnekleri (2 mL) tolfenamik asit uygulaması öncesi (0.dk, kontrol) ve uygulama sonrası 12., 24. ve 48. saatlerde sol brachial venden vena punktur yöntemi ile antikoagülsüz tüplere alındı. Alınan kan örnekleri santrifüj edilerek (4000 x g'de 10 dakika) serum örnekleri elde edildi ve örnekler analiz zamanına kadar -80 °C'de saklandı. Araştırma süresince hayvanlar klinik olarak gözlemlendi.

Biyokimyasal Analizler: Serum örneklerinden kreatinin, üre, total protein, albumin, kolesterol, trigliserid, gamma glutamilttransferaz (GGT), alkalen fosfataz (ALP), alanin aminotransferaz (ALT) ve aspartat aminotransferaz (AST) değerlerinin ölçümü ticari kitler kullanılarak otoanalizatör cihazında (Abbott architect c8000, Abbott Core 20 Laboratory, USA) gerçekleştirildi.

İstatistiksel Analiz: Elde edilen sonuçlar ortalama±SD olarak sunuldu. Veri dağılımının normalliği ve varyansın homojenliği Shapiro-Wilk ve Levene testiyle değerlendirildi. Biyokimyasal parametrelerinin istatistiksel karşılaştırılması tek yönlü varyans analizi (ANOVA) ve post-hoc Tukey testi ile gerçekleştirildi. İstatistiksel önemlilik sınırı P<0.05 olarak kabul edildi. Analizler SPSS programı (22.0 software; IBM) kullanılarak gerçekleştirildi.

Tablo 1. Ördeklere tolfenamik asitin damar içi yolla 2 mg/kg, 4 mg/kg ve 8 mg/kg tek doz uygulaması sonrası 0., 12., 24. ve 48. saatlerde biyokimyasal parametreleri (Ortalama±SD, min-max).

Parametre	Grup	0.saat	12.saat	24.saat	48.saat
AST (U/L)	2 mg/kg	17.00±7.64 (12.00-32.00)	31.33±11.83 (20.00-46.00)	18.33±6.99 (9.00-27.00)	20.83±8.18 (7.00-30.00)
	4 mg/kg	17.00±7.95 (10.00-32.00)	25.33±6.12 (16.00-35.00)	20.00±6.24 (12.00-30.00)	16.17±3.92 (12.00-23.00)
	8 mg/kg	17.67±7.00 (12.00-31.00)	28.50±9.99 (17.00-45.00)	19.83±4.26 (15.00-27.00)	29.67±17.85 (21.00-66.00)
ALT (U/L)	2 mg/kg	33.33±9.89 ^b (21.00-46.00)	55.50±17.72 ^a (39.00-78.00)	39.17±3.18 ^{aby} (35.00-43.00)	35.67±4.03 ^{by} (28.00-39.00)
	4 mg/kg	34.00±9.40 ^c (22.00-45.00)	75.50±8.36 ^a (64.00-85.00)	68.50±17.97 ^{abx} (54.00-107.00)	51.00±15.39 ^{bctx} (37.00-80.00)
	8 mg/kg	32.50±9.65 ^b (21.00-45.00)	59.00±25.68 ^{ab} (37.00-107.00)	54.83±21.11 ^{abxy} (35.00-97.00)	64.17±10.07 ^{ax} (52.00-77.00)
ALP (U/L)	2 mg/kg	31.50±5.61 (24.00-41.00)	28.33±8.19 (14.00-35.00)	26.83±6.91 (15.00-37.00)	36.83±7.36 (38.00-45.00)
	4 mg/kg	33.17±5.64 (25.00-42.00)	33.50±8.55 (25.00-44.00)	35.00±9.66 (28.00-56.00)	36.33±21.71 (12.00-75.00)
	8 mg/kg	30.83±5.78 (23.00-40.00)	37.17±12.64 (22.00-54.00)	39.83±17.35 (19.00-59.00)	42.17±16.79 (23.00-62.00)
GGT (U/L)	2 mg/kg	1.83±0.98 (1.00-3.00)	1.67±0.82 (1.00-3.00)	2.00±1.41 (1.00-5.00)	2.17±0.41 (2.00-3.00)
	4 mg/kg	1.83±0.75 (1.00-3.00)	1.67±0.52 (1.00-2.00)	1.83±1.07 (1.00-4.00)	2.00±0.63 (1.00-3.00)
	8 mg/kg	1.83±0.41 (1.00-2.00)	1.67±0.52 (1.00-2.00)	1.67±0.47 (1.00-2.00)	2.00±0.63 (1.00-3.00)
Albumin (g/dL)	2 mg/kg	16.17±1.16 (14.50-17.70)	15.60±1.01 (14.40-16.70)	15.60±1.05 (13.60-16.50)	15.90±1.69 (13.70-18.90)
	4 mg/kg	16.45±1.92 (14.50-19.70)	15.02±1.96 (12.50-18.40)	14.47±0.75 (13.40-15.40)	15.92±0.74 (14.80-17.10)
	8 mg/kg	16.13±0.85 (15.30-17.50)	15.23±2.32 (11.90-17.90)	15.10±1.40 (13.40-17.10)	16.72±0.77 (15.50-17.30)
Total protein (g/dL)	2 mg/kg	45.45±2.15 (42.40-48.90)	44.18±3.11 (39.30-48.10)	45.12±2.63 (41.70-50.40)	46.40±2.22 (43.70-49.80)
	4 mg/kg	45.62±2.30 (42.50-49.20)	42.45±6.71 (34.80-53.80)	43.05±2.75 (39.70-48.60)	45.82±5.02 (42.60-55.90)
	8 mg/kg	45.77±1.70 (44.20-49.10)	42.18±4.57 (34.90-47.70)	44.03±3.84 (38.70-49.40)	45.37±1.67 (42.80-46.60)
Kolesterol (mg/dL)	2 mg/kg	136.83±22.85 (117.00-172.00)	136.00±5.66 (129.00-143.00)	145.33±15.08 (115.00-164.00)	144.17±17.43 (117.00-171.00)
	4 mg/kg	137.33±24.82 (116.00-176.00)	130.17±38.16 (103.00-206.00)	148.83±29.39 (121.00-211.00)	162.67±61.57 (121.00-285.00)
	8 mg/kg	138.00±21.51 (114.00-174.00)	138.83±21.52 (112.00-170.00)	146.00±20.42 (124.00-176.00)	140.33±12.94 (118.00-153.00)
Trigliserid (mg/dL)	2 mg/kg	174.00±59.12 ^a (116.00-284.00)	116.50±33.97 ^{ab} (71.00-149.00)	103.00±25.77 ^b (75.00-148.00)	135.67±28.79 ^{ab} (101.00-185.00)
	4 mg/kg	175.50±40.03 ^a (135.00-240.00)	87.67±28.03 ^b (61.00-139.00)	81.83±11.19 ^b (69.00-145.00)	123.17±36.20 ^b (88.00-192.00)
	8 mg/kg	174.33±37.32 ^a (130.00-233.00)	101.50±19.81 ^b (77.00-121.00)	106.83±53.21 ^b (46.00-206.00)	99.67±24.78 ^b (73.00-139.00)
Üre (mg/dL)	2 mg/kg	4.00±0.89 (3.00-5.00)	4.83±1.33 (3.00-7.00)	3.83±1.07 (3.00-6.00)	4.33±1.97 (3.00-8.00)
	4 mg/kg	3.83±0.75 (3.00-5.00)	5.17±2.04 (4.00-9.00)	3.33±1.49 (1.00-6.00)	2.83±1.17 (1.00-4.00)
	8 mg/kg	4.00±1.10 (2.00-5.00)	4.33±0.52 (4.00-5.00)	4.00±0.58 (3.00-5.00)	4.17±1.33 (3.00-6.00)
Kreatinin (mg/dL)	2 mg/kg	0.10±0.06 (0.05-0.16)	0.14±0.04 (0.09-0.22)	0.09±0.05 (0.01-0.16)	0.14±0.04 (0.12-0.22)
	4 mg/kg	0.11±0.06 (0.06-0.20)	0.09±0.05 (0.05-0.16)	0.07±0.04 (0.03-0.13)	0.14±0.07 (0.09-0.26)
	8 mg/kg	0.10±0.06 (0.05-0.19)	0.09±0.03 (0.05-0.12)	0.12±0.06 (0.02-0.19)	0.09±0.04 (0.02-0.16)

^{x,y}; Aynı sütundaki (gruplar arası) ve ^{a,b,c}; aynı satırdaki (grup içi) istatistiksel farklılığı gösterir. (p <0.05).

AST; aspartat aminotransferaz, ALT; alanin aminotransferaz, ALP; alkalin fosfataz, GGT; gamma glutamiltransferaz

Bulgular

Ördeklere tolfenamik asitin damar içi yolla 2 mg/kg, 4 mg/kg ve 8 mg/kg dozda uygulaması sonrası ördeklerin iştah, davranış ve aktivitelerinde herhangi bir farklılık görülmedi. Ördeklere artan dozlarda tolfenamik asit uygulaması sonrası elde edilen biyokimyasal parametreler Tablo 1'de sunuldu. Tolfenamik asitin farklı dozlarda uygulaması sonrası AST, ALP, GGT, albümin, total protein, kolesterol, üre ve kreatinin değerlerinin grup içi ve gruplar arası değerlendirmesinde herhangi bir farklılık görülmedi ($p > 0.05$). Tolfenamik asitin 2, 4 ve 8 mg/kg dozlarda uygulaması ALT ve trigliserid düzeylerinde önemli değişikliklere neden oldu ($p < 0.05$). ALT düzeyi; 2 mg/kg'da 12. saatte, 4 mg/kg'da 12 ve 24. saatlerde ve 8 mg/kg'da 48. saatte yükseldi ($p < 0.05$). Trigliserid düzeyi 2 mg/kg doz grubunda geçici olarak azalırken, 4 ve 8 mg/kg doz gruplarında tüm örnekleme zamanlarında azaldığı belirlendi ($p < 0.05$). Farklı doz grupları karşılaştırıldığında trigliserid düzeyinde herhangi bir farklılık görülmedi.

Tartışma ve Sonuç

Ördek yetiştiriciliği endüstriyel ve kırsal kanatlı yetiştiriciliğinin önemli bir ayağını oluşturmaktadır ve son yıllarda yetiştiriciliğinde dünya çapında önemli bir artış görülmüştür. Ördek yetiştiriciliğindeki artışa bağlı olarak ortaya çıkan olumsuz çevre şartları ve kötü yönetim, ölüm ve ekonomik kayıplara neden olan önemli hastalıkların görülmesine yol açmaktadır. Ölüm ve hastalık sonucunda gelişebilecek verim kayıplarının önüne geçilmesi için etkili tedavi seçeneklerinin geliştirilmesine ihtiyaç vardır (Adzitey ve Adzitey, 2011). Ancak ördeklere onaylı ilaçların sınırlı olmasından dolayı tedavide kullanılan ilaçlar farklı türlerden uyarlanır. Bu durum tedavide başarısızlığa veya istenmeyen etkilere yol açabileceği için hedef türde etkinlik ve güvenilirlik çalışmalarının yapılması gerekir. İlaçların istenmeyen etkilerinin değerlendirilmesinde ise biyokimyasal parametreler kullanılabilir (Coşkun ve ark., 2022). Tolfenamik asit sığır, domuz, kedi ve köpekte yaygın olarak kullanılan NSAİİ'tir. Yapılan çalışmalarında tolfenamik asitin antiinflamatuvar etkinliğinin doza bağlı olarak arttığı belirtilmiştir (Lees ve ark., 1998; Mckellar ve ark., 1994). Ancak NSAİİ'lerin yüksek dozlarda kullanımı istenmeyen etkilere yol açabilir. Tolfenamik asitin yan etki profili genel olarak düşüktür. Ratlarda yapılan araştırmalarda tolfenamik asitin gastrik ülser riskinin asetil salisilik asit, naproksen, ibuprofen, ketoprofen ve indometazin gibi NSAİİ'lardan düşük olduğu bulunmuştur (Eskerod, 1994; Hendel, 1994). Tolfenamik asit ağrılı ve yangılı durumlarda ördeklere kullanıma potansiyeli olmasına karşın güvenilirliği hakkında herhangi bir bilgi bulunamamıştır. Bu araştırma sonucunda tolfenamik asitin artan dozlarda uygulamasının ördeklere biyokimyasal parametrelere önemli etkisinin olmadığı görülmüştür.

Bu çalışmada ördeklere tolfenamik asitin 2, 4 ve 8 mg/kg tek doz uygulaması hayvanlarda klinik olarak herhangi bir istenmeyen etkiye neden olmadı. Benzer şekilde kazlarda (Türk ve ark., 2021a) ve keklilerde (Çetin ve ark., 2022) damar içi yolla ve bıldırcınlarda kas içi (Türk ve ark., 2021b)

yolla 2 mg/kg tolfenamik asit uygulamasında herhangi bir yan etki bildirilmemiştir. Ayrıca damar içi yolla keçi ve kaplumbağalara 2 ve 4 mg/kg dozlarda (Çorum ve ark., 2019; Tekeli ve ark., 2020; Türk ve ark., 2021) ve keçi ile koyunlara 2, 4 ve 8 mg/kg dozlarda (Çetin ve Türk, 2020; Çorum ve ark., 2018) uygulaması iyi tolere edilmiştir. Ancak damar içi yolla koyunlara 16 mg/kg dozda ve sığırlara 18-20 mg/kg dozda uygulaması geçici nörolojik sıkıntılara neden olmuştur (Anonim, 2023; Çorum ve ark., 2018).

Pekin ördeklerine tolfenamik asitin artan dozlarda uygulaması AST, ALP, GGT, albümin, total protein, kolesterol, üre ve kreatinin değerlerinde herhangi bir farklılık belirlenmedi ($p > 0.05$). Ancak doza bağlı olarak ALT değerlerinde artış ve trigliserid değerlerinde ise azalma belirlendi ($p < 0.05$). Yapılan diğer çalışmalarda tolfenamik asitin aynı dozlarda damar içi yolla keçilere uygulaması sonucu AST, ALP, GGT, ALP, albümin, total protein, kolesterol, trigliserid, üre ve kreatinin değerlerinde ve koyunlara uygulaması sonucu üre ve kreatinin değerlerinde önemli bir değişiklik olmamıştır (Çetin ve Türk, 2020; Yıldız ve ark., 2019). Ratlara tolfenamik asitin kas içi yolla 14 gün boyunca uygulaması sonrası ALT, ALP, AST, total protein, total bilirubin, glikoz, albümin, globülin, üre, kreatinin ve ürik asit değerlerinde herhangi bir farklılık bulunmamıştır (Patel ve ark., 2011). Koyunlarda tolfenamik asitin 8 ve 16 mg/kg dozda nötrofiljelatinaz ilişkili lipokalin (NGAL) ve böbrek hasar molekülü (KIM)-1 gibi böbrek hasar ve trefoil faktör (TFF)-2 gibi gastrik hasar belirteçlerinde artışa neden olmuştur (Yıldız ve ark., 2019). ALT ve trigliserid parametrelerindeki değişim karaciğer hasarı ile ilişkili olabilir (Coşkun ve ark., 2019). Kanatlılarda yapılan çalışmalarda yüksek doz veya tekrarlı ilaç uygulaması sonrasında diklofenak sodyum, meloksikam ve ibuprofen'in karaciğer hasarına neden olduğu rapor edilmiştir (Hedau ve Bhadarkar, 2016; Osičková ve ark., 2014; Shafi ve ark., 2015). Tolfenamik asitin metabolizması ördeklere bilinmemesine karşın insanlarda önemli bir kısmı karaciğerde metabolize olur ve %10'u değişmeden idrar ile atılır (Pentikäinen ve ark., 1982). Bu durumda karaciğere yoğun tolfenamik asit maruziyetini göstermektedir. Bu çalışmada ALT ve trigliserid parametrelerdeki değişimin nedeni bu durum olabilir.

Sonuç olarak klinik gözlemler ve biyokimyasal değerler incelendiğinde, ördeklere tolfenamik asitin IV yolla artan dozda uygulaması iyi tolere edildi. Ancak tolfenamik asitin tüm doz grupları ALT ve trigliserid değerlerinde farklılığa neden oldu. Bu nedenle ördeklere tolfenamik asitin farklı dozlarda tek veya tekrarlayan uygulamalarının güvenilirliği için hematolojik, biyokimyasal, moleküler ve histopatolojik sonuçların ortaya konulmasına ihtiyaç vardır.

Çıkar çatışması

Yazarlar, bu makale için gerçek, potansiyel veya algılanan bir çıkar çatışması olmadığını beyan eder.

Etik izin

DeneySEL prosedür Hatay Mustafa Kemal Üniversitesi Hayvan Araştırmaları Yerel Etik Kurulu tarafından Etik onay

alındı (2022/03-16). Ayrıca yazarlar Araştırma ve Yayın Etiğine uyulduğunu beyan etmişlerdir.

Finansal destek

Bu çalışma herhangi bir kurum/kuruluş tarafından desteklenmemiştir.

Benzerlik Oranı

Makalenin benzerlik oranının sisteme yüklenen raporda belirtildiği gibi %11 olduğunu beyan ederiz.

Yazar Katkıları

Fikir/Kavram: OÇ, DC, DDÇ
Tasarım: OÇ, DC, MK, DDÇ
Denetleme/Danışmanlık: OÇ, DC, DDÇ
Veri Toplama ve/veya İşleme: OÇ, DC, MK, DDÇ
Analiz ve/veya Yorum: OÇ, DC, DDÇ
Kaynak Taraması: OÇ, DC, DDÇ
Makalenin Yazımı: OÇ, DC, MK, DDÇ
Eleştirel İnceleme OÇ, DC, DDÇ

Kaynaklar

Adzitey F, Adzitey S, 2011: Duck production: has a potential to reduce poverty among rural households in Asian communities—a review. *J World Poult Res*, 1, 7–10.

Ahmed S, Sheraz MA, Ahmad I, 2018: Tolfenamic acid. *Profiles Drug Subst Excip Relat Methodol*, 43, 255–319.

Anonim (1): https://www.ema.europa.eu/en/documents/mrl-report/tolfenamic-acid-summary-report-committee-veterinary-medicinal-products_en.pdf. Erişim Tarihi; 24.08.2023.

Arda M, Minbay A, Aydın N, Akay Ö, İzgür M, Yardımcı H, Esendal ÖM, Erdeğer J, Akan M, 2002: Kanatlı hayvan hastalıkları. Medisan Yayınları, Ankara, Türkiye.

Coşkun D, Canbar R, Korkmaz Y, Dik B, Er A, 2019: Danofloksasinin 8-hidroksi-2-deoksiguanozin düzeyine etkisinin belirlenmesi. *Eurasian J Vet Sci*, 35 (4), 224–229

Coşkun D, Çetin G, Çorum O, 2022: Effect of ascending doses of pentoxifylline administration on biochemical and hematological parameters in goats. *Kocatepe Vet J*, 15 (1), 63–68.

Coşkun D, Çorum O, Durna Çorum D, Üney K, 2023: Pharmacokinetics and bioavailability of meloxicam in Pekin ducks following intravenous, intramuscular and oral administration. *Vet Anaesth Analg*, 1-7.

Çetin G, Çorum O, Durna Çorum D, Atik O, Altan F, Türk E, Tekeli İO, Eser Fakı H, Üney K, 2022: Pharmacokinetics of intravenous meloxicam, ketoprofen and tolfenamic acid in chukar partridge (*Alectoris chukar*). *Brit Poultry Sci*, 63 (1), 14–20.

Çetin G, Türk E, 2020: Keçilerde tolfenamik asitin artan dozlarda uygulanmasının biyokimyasal parametrelere etkisi. *Dicle Üniv Vet Fak Derg*, 13 (2), 162–165.

Çorum O, Atik O, Durna Çorum D, Er A, Üney K, 2019: Pharmacokinetics of tolfenamic acid in red-eared slider turtles (*Trachemys scripta elegans*). *Vet Anaesth Analg*, 46 (5), 699–706.

Çorum O, Durna Çorum D, Er A, Yıldız R, Üney K, 2018: Pharmacokinetics and bioavailability of tolfenamic acid in sheep. *J Vet Pharmacol Ther*, 41 (6), 871–877.

Dinev I, 2007: Diseases of poultry, a colour atlas, 1st ed., 2M Print House Ltd., St. Zagora, Bulgaristan.

Eskerod O, 1994: Gastrointestinal tolerance studies on tolfenamic acid in humans and animals. *Pharmacol Toxicol*, 75, 44–48.

Galligan TH, Bhusal KP, Paudel K, Chapagain D, Joshi AB, Chaudhary IP, Chaudhary A, Baral HS, Cuthbert RJ, Green RE, 2020: Partial recovery of critically endangered gyps vulture populations in nepal. *Bird Conserv Int*, 30 (1), 87–102.

Hawkey CJ, 2001: COX-1 and COX-2 inhibitors. *Best Pract Res Clin Gastroenterol*, 15, 801–820.

Hawkins MG, 2006: The use of analgesics in birds, reptiles, and small exotic mammals. *J Exot Pet Med*, 15, 177–192.

Hedau M, Bhadarkar AG, 2016: Pathology of meloxicam toxicity in cockerel birds. *Ind J Vet Sci and Biotech*, 11 (3), 63–68.

Hendel J, 1994: The overall safety of tolfenamic acid. *Pharmacol Toxicol*, 75, 53–55.

Landoni MF, Cunningham FM, Lees P, 1996: Pharmacokinetics and pharmacodynamics of tolfenamic acid in calves. *Res Vet Sci*, 61 (1), 26–32.

Lees P, McKellar QA, Foot R, Gettinby G, 1998: Pharmacodynamics and pharmacokinetics of tolfenamic acid in ruminating calves: Evaluation in models of acute inflammation. *Vet J*, 155 (3), 275–288.

Machin KL, 2005: Controlling avian pain. *Comp Cont Educ Pract Vet*, 27, 299–307.

McKellar QA, Lees P, Gettinby G, 1994: Pharmacodynamics of tolfenamic acid in dogs. evaluation of dose response relationships. *Eur J Pharmacol*, 253 (3), 191–200.

Needham ML, Webb AI, Baynes RE, Riviere JE, Craigmill AL, Tell LA, 2007: Current update on drugs for game bird species. *JAVMA*, 231 (10), 1506–1508.

Osičková J, Bandouchová H, Kováčová V, Král J, Novotný L, Ondráček K, Pohanka M, Sedláčková J, Škočková H, Vitula F, Pikula J, 2014: Oxidative stress and liver damage in birds exposed to diclofenac and lead. *Acta Vet Brno*, 83 (4), 299–304.

Patel SD, Sadariya KA, Gothi AK, Patel UD, Jain MR, Bhavsar SK, Thaker AM, 2011: Safety of tolfenamic acid following repeated intramuscular administration in wistar rats. *Pharma Sci Monitor Int J Pharm Sci*, 2 (2), 79–85.

Pentikäinen PJ, Penttilä A, Neuvonen PJ, Khalifah RG, Hignite CE, 1982: Human metabolism of tolfenamic acid. I. Isolation, preliminary characterization and pharmacokinetics of tolfenamic acid and its metabolites. *Eur J Drug Pharmacokin*, 7, 259–267.

Shafi M, Hussain K, Garg UK, Baba OK, 2015: Haemato-biochemical and immunological study on NSAIDs induced acute toxicity in broiler chicken. *J Animal Res*, 5 (2), 297–302.

Sidhu PK, Landoni MF, Lees P, 2005: Influence of marbofloxacin on the pharmacokinetics and pharmacodynamics of tolfenamic acid in calves. *J Vet Pharmacol Ther*, 28 (1), 109–119.

Sidhu PK, Landoni MF, Lees P, 2006: Pharmacokinetic and pharmacodynamics interactions of tolfenamic acid and marbofloxacin in goats. *Res Vet Sci*, 80 (1), 79–90.

Tai C, Tai JLL, 2001: Future prospects of duck production in asia. *J Poult Sci*, 38, 99–112

Tekeli İO, Türk E, Durna Çorum D, Çorum O, Kırgız FC, Üney K, 2020: Effect of dose on the intravenous pharmacokinetics of tolfenamic acid in goats. *J Vet Pharmacol Ther*, 43 (5), 435–439.

- Toutain PL, Ferran A, Bousquet-Melou A, 2010: Species differences in pharmacokinetics and pharmacodynamics In: Comparative and Veterinary Pharmacology, Cunningham F, Elliott J, Lees P (Eds.), 19–48, Springer, Berlin.
- Türk E, Tekeli İO, Çorum O, Durna Çorum D, Kırgız FC, Cetin G, Arslan Ateşşahin D, Üney K, 2021b: Pharmacokinetics of meloxicam, carprofen, and tolfenamic acid after intramuscular and oral administration in Japanese quails (*Coturnix coturnix japonica*). *J Vet Pharmacol Ther*, 44 (3), 388–396.
- Türk E, Tekeli İO, Durna Çorum D, Çorum O, Altınok Yipel F, İlhan A, Emiroğlu SB, Uğuz H, Üney K, 2021; Pharmacokinetics of tolfenamic acid in goats after different administration routes. *J Vet Pharmacol Ther*, 44 (3), 367–373.
- Türk E, Tekeli İO, Durna Çorum D, Çorum O, Sakin F, Üney K, 2021a: Pharmacokinetics of tolfenamic acid after different administration routes in geese (*Anser cygnoides*). *J Vet Pharmacol Ther*, 44 (3), 381–387.
- Yıldız R, Çorum O, Atik O, Durna Çorum D, Altan F, Ok M, Üney K, 2019: Changes in novel gastrointestinal and renal injury markers in the blood plasma of sheep following increasing intravenous doses of tolfenamic acid. *Acta Vet Hung*, 67 (1), 87–97.



Geometric morphometric analysis of New Zealand rabbit cranium

Havali AKKAYA^{1,a}, İftar GÜRBÜZ^{2, b, *}

¹ Burdur Mehmet Akif Ersoy University, Institute of Health Sciences
Student, Department of Veterinary Anatomy, Burdur, Türkiye.

² Burdur Mehmet Akif Ersoy University, Faculty of Veterinary
Medicine, Department of Anatomy, Burdur, Türkiye.

^aORCID: 0000-0002-0941-1864;

^bORCID: 0000-0001-9460-0645;

Received: 10.11.2023

Accepted: 15.01.2024

How to cite this article: Akkaya H, Gürbüz I. (2024). Geometric morphometric analysis of New Zealand rabbit cranium. Harran Üniversitesi Veteriner Fakültesi Dergisi, 13(1): 14-21.

DOI:10.31196/huvfd.1388962.

***Correspondence:** İftar GÜRBÜZ

Burdur Mehmet Akif Ersoy University, Faculty of Veterinary
Medicine, Department of Anatomy, Burdur, Türkiye.

e-mail: iftargurbuz@mehmetakif.edu.tr

Available on-line at: <https://dergipark.org.tr/tr/pub/huvfd>

Abstract: This study, aimed to determine the shape features of the New Zealand rabbit skull and to reveal the differences between individuals and genders in terms of shape features. For this purpose, the geometric morphometry method was used. A total of 10 female and 10 male New Zealand Rabbit craniums were used. The skulls were photographed in a dorsal, ventral and lateral view, and the mandible was photographed in a lateral view. Homologous landmarks were marked on the photographs. Consensus graphs were created by the TpsRelw (Version 1.70) program. Additionally, principal component analysis and relative warp analysis were performed. As a result of the study, principal components explained 34.813%, 57.225% and 42.427% of the total shape difference in the dorsal, ventral and lateral views of the skull, respectively. In the first principal component graph obtained as a result of principal component analysis, no significant clustering was observed between genders. According to the graphics obtained in the MorphoJ program, inter-individual variation was detected mainly in the viscerocranium, followed by the neurocranium. This study will contribute to morphological and archaeological studies on rabbit skulls.

Keywords: Gender, geometric morphometry, mandible, rabbit, skull.

Yeni Zelanda Tavşanı Cranium'unun Geometrik Morfometrik Analizi

Özet: Bu çalışmada Yeni Zelanda tavşanı kafatasının şekilsel özelliklerinin belirlenmesi ve bu özellikler bakımından bireyler arası ve cinsiyetler arası farklılıkların ortaya konulması amaçlandı. Bu amaçla geometrik morfometri yöntemi kullanıldı. Toplamda 10 adet dişi ve 10 adet erkek Yeni Zelanda Tavşanı kafatası kullanıldı. Kafatasları dorsal, ventral ve lateral görünümde, mandibula lateral görünümde fotoğraflandı. Fotoğraflar üzerinde homolog landmarklar işaretlendi. Konsensüs grafikleri TpsRelw (Sürüm 1.70) programı tarafından oluşturuldu. Ayrıca temel bileşen analizi ve relative warp analizi yapıldı. Çalışma sonucunda temel bileşenler, kafatasının dorsal, ventral ve lateral görünümündeki toplam şekil farkının sırasıyla %34,813, %57,225 ve %42,427'sini açıklamaktadır. Temel bileşenler analizi sonucunda elde edilen birinci temel bileşenler grafiğinde cinsiyetler arasında anlamlı bir kümelenme gözlenmedi. MorphoJ programında elde edilen grafiklere göre bireyler arası varyasyonun en çok viscerocranium'da, ardından da neurocranium'da olduğu tespit edildi. Bu çalışmanın tavşan kafatasları üzerinde yapılacak morfolojik ve arkeolojik çalışmalara katkı sağlayacağına inanıyoruz.

Anahtar Kelimeler: Cinsiyet, geometrik morfometri, kafatası, mandibula, tavşan.

Introduction

New Zealand White rabbit (*Oryctolagus cuniculus* L.) belongs to the Craniata group of Chordata, Mammalian class, Lagomorpha order, Leporidae family (McLaughlin and Chiasson, 1979). Rabbits are frequently used in scientific studies because they have a short growth period and are easy to follow before and after the experiment (Mapara et al., 2012). In the rabbit, the skull consists of bones joined by immobile joints. The rabbit's skull has a well-developed posterior section (neurocranium) surrounding the brain and a front section (viscerocranium) consisting of jaws. Orbits are between the posterior section and anterior sections (Farang et al., 2012).

The traditional morphometry method analyzes structure distance and ratios, angle, area and volume measurements statistically (Mitteroecker and Gunz, 2009). The limitations of traditional morphometry analysis methods have led to the emergence of a new method, geometric morphometry, over time (Adams et al., 2004; Aytekin, 2017). Geometric morphometry is a method based on the analysis of anatomical points obtained from two- or three-dimensional Cartesian coordinates (Bookstein, 1997; Boz et al., 2023).

There are many geometric morphometric studies on the skull in the literature (Demiraslan et al., 2023; Demircioğlu et al., 2021; Erol and Aytekin, 2016; Gündemir et al., 2023; Gürbüz et al., 2020, Gürbüz et al., 2022; Yalçın and Kaya, 2009; Yaprak et al., 2023). However, no study was found in the literature in which the skull and mandible of male and female New Zealand Rabbits were examined using the geometric morphometric method. The aim of the study was to examine New Zealand Rabbit's cranium according to gender using geometric morphometric methods.

Materials and methods

Ethical approval: Approval for the study was received from Burdur Mehmet Akif Ersoy University Animal Experiments Local Ethics Committee (Date: 13.10.2021, Number: 820).

Materials: A total of 20 adult New Zealand rabbit cranium, 10 female and 10 male, were used in the research. There was no pathology in the craniums. The weights of the male and female rabbits were determined as 1896.72 ± 399.8 kg and 1910 ± 485.9 kg, respectively. After the rabbit cranium was macerated, the skull was photographed in the ventral, dorsal and left lateral directions, and the left mandible was photographed in the lateral direction. These photographs were taken from a distance of 50 cm for all materials.

Geometric morphometric analysis: Photos were saved in JPEG format. Then, a file in Tps format was created with the TpsUtil (Version 1.79) program to place landmarks (LM) on the photographs (Rohlf, 2019). Homologous LMs were ticked on the photographs with the TpsDig2 (Version 2.31) program (Rohlf, 2018). 14 homologous LMs were ticked on the dorsal images of the skulls (Figure 1), 15 on the ventral images (Figure 2), 14 on the lateral images (Figure 3) and 10

on the mandible images (Figure 4). Thus, the Cartesian coordinates of the LMs were determined. Homologous LM validation testing was done with the TpsSmall (Version 1.34) program (Rohlf, 2017). As a result of this analysis, uncentred correlation and root mean square error were specified as 1.000000 and 0.000025 on dorsal images, 1.000000 and 0.000080 on ventral images, 1.000000 and 0.000025 on lateral images, and 1.000000, 0.000033 on mandibles. All these results demonstrated the accuracy of LMs.

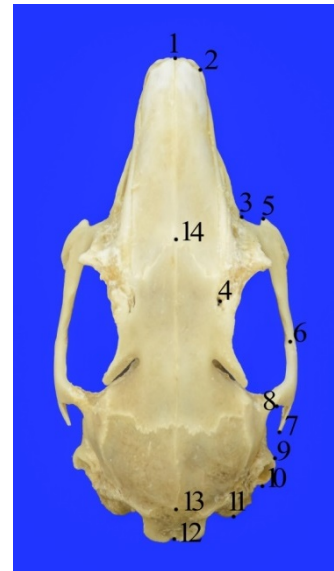


Figure 1. Landmarks on dorsal images of the female skull. **LM1.** Craniomedial of os incisivum, **LM2.** Craniolateral of os nasale, **LM3.** Medial eye angle, **LM4.** Incisura supraorbitalis rostralis, **LM5.** Cranial of arcus zygomaticus, **LM6.** Junction of processus temporalis and processus zygomaticus, **LM7.** Caudal of arcus zygomaticus, **LM8.** Caudomedial of the processus zygomaticus osis temporalis, **LM9.** Cranial external auditory canal, **LM10.** Caudal external auditory canal, **LM11.** Caudal of os occipitale, **LM12.** Caudomedial of the skull, **LM13.** Midpoint of os interparietale, **LM14.** Medial of sutura nasofrontalis.

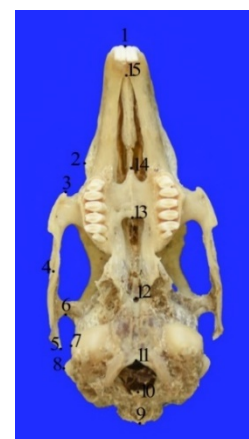

Figure 2. Landmarks on ventral images of a female skull. **LM1.** Craniomedial of os incisivum, **LM2.** Lateral projection of facies facialis, **LM3.** Cranial of tuber faciale, **LM4.** Midpoint of arcus zygomaticus, **LM5.** Caudal of arcus zygomaticus, **LM6.** Caudomedial of the processus zygomaticus osis temporalis, **LM7.** Lateral process of os temporale, **LM8.** Lateral process of the external auditory canal, **LM9.** Caudomedial of os occipitale, **LM10.** Dorsomedial line of foramen magnum, **LM11.** Ventromedial line of foramen magnum, **LM12.** Canalis craniopharyngeus, **LM13.** Caudomedial of os palatinum, **LM14.** Craniomedial of the processus palatinum of maxilla, **LM15.** Craniomedial of processus palatinum of os incisivum.

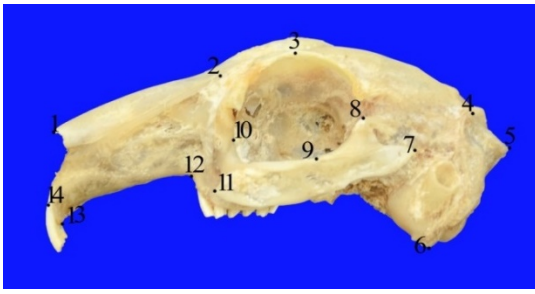


Figure 3. Landmarks on lateral aspect of skull in male rabbit skull. LM1. Craniomedial of os nasale, LM2. Proc of os incisivum. caudal of nasalis, LM3. Dorsal of the orbit, LM4. Intersection of os interparietale and os parietale, LM5. Medial of crista nuchae, LM6. Caudoventral of os occipitale, LM7. Caudal of arcus zygomaticus, LM8. Proc. of os temporale. zygomaticus, LM9. Proc of os maxilla. zygomaticus and proc of os temporale. intersection of zygomaticus (midpoint of Arcus zygomaticus), LM10. Medial eye angle, LM11. Cranial end of arcus zygomaticus, LM12. Caudoventral angle of corpus maxilla, LM13. Caudal of the roots of Dentes incisivi, LM4. Craniomedial of os incisivum.

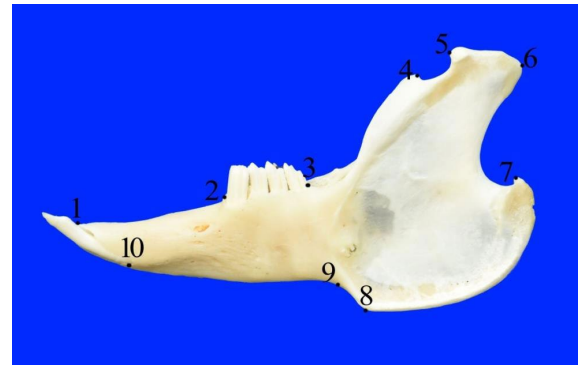


Figure 4. Landmarks identified on lateral views of the mandible in a female New Zealand Rabbit. LM1. Craniomedial of os incisivum, LM2. Cranial end of premolar tooth root, LM3. Caudal of the last molar tooth root, LM4. Caudal of proceccus coronoideus, LM5. Cranial of processus condylaris, LM6. Caudal of processus condylaris, LM7. Processus angularis, LM8. Cranial end of angulus mandible, LM9. Incisura vasorum facialis, LM10. Caudal border of incisive tooth root.

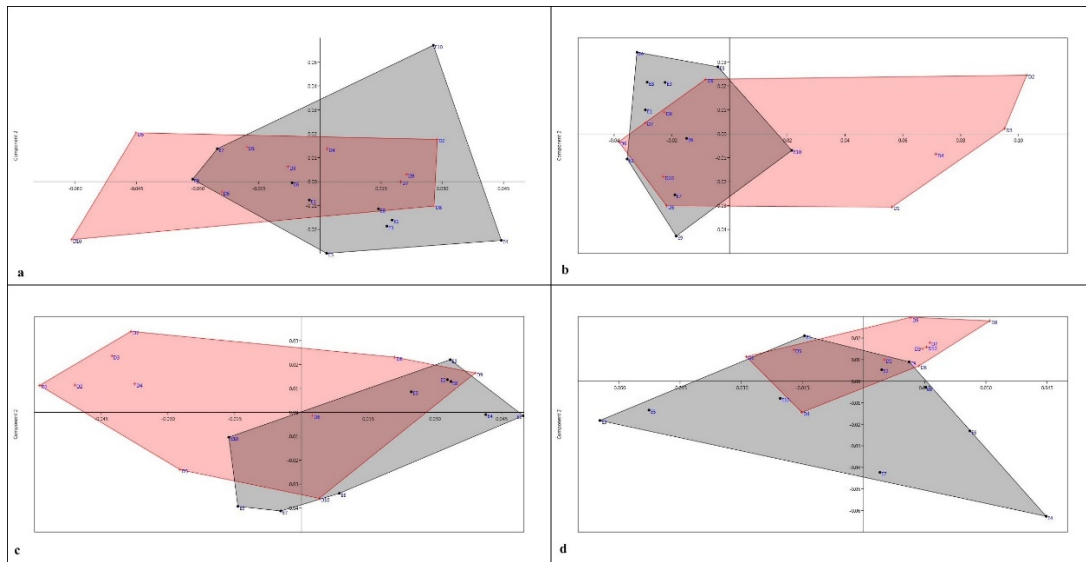


Figure 5. Graphical representation of the results obtained based on the first principal component on skull images. a. Dorsal images of skull, b. Ventral images of skull, c. Lateral images of skull, d. Mandible

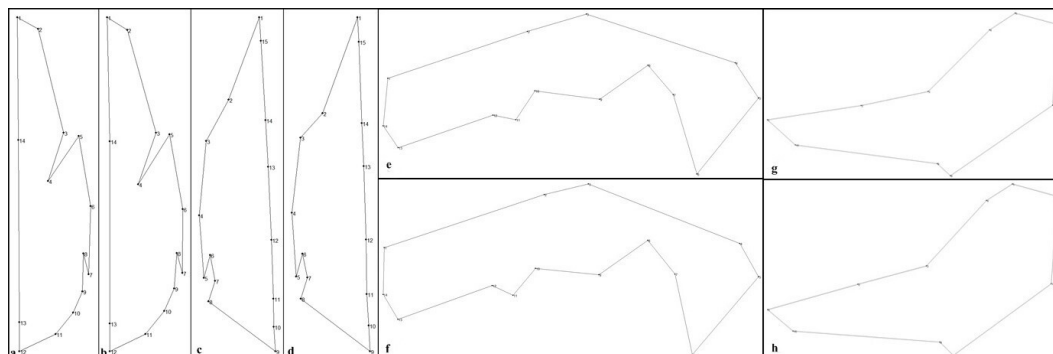


Figure 6. Consensus graph of images of New Zealand rabbit cranium a. Dorsal images of female’s skull, b. Dorsal images of male’s skull, c. Ventral images of female’s skull, d. Ventral images of male’s skull, e. Lateral images of female’s skull, f. Lateral images of male’s skull, g. Female’s mandible, h. Male’s mandible.

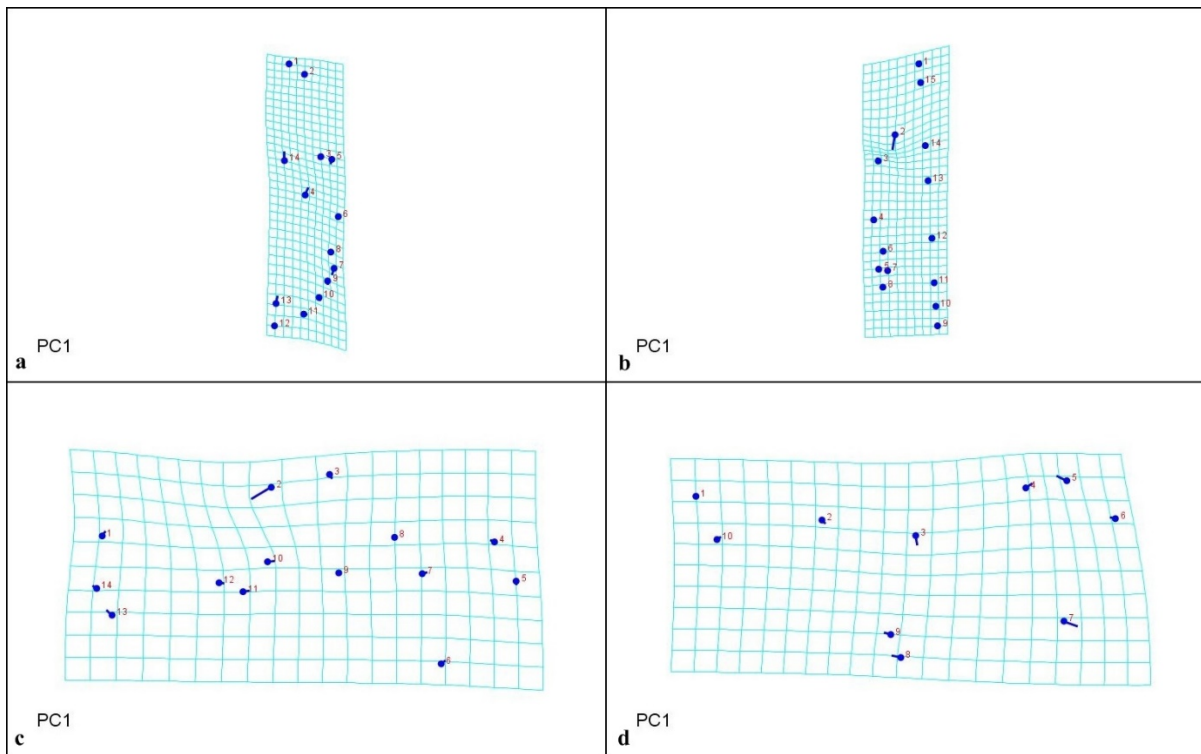


Figure 7. Lollipop graph of PC1 obtained in the MorphoJ program in New Zealand rabbit skull images (Scale factor: 0.05) **a.** Dorsal, **b.** Ventral, **c.** Lateral, **d.** Mandible

In this study, superimposition were applied to the images with Generalized Procrustes analysis (GPA) because the photographs may differ in size, direction and position (Slice, 2007). The PAST (Version 4.02) program was used to perform this analysis (Hammer et al., 2001). After the superimposition was performed, Principal Component (PC) analysis was applied to the new coordinate values that were obtained. Thus, the degree of differentiation of rabbit craniums according to gender was determined. (Zelditch et al., 2004). Additionally, the Morpho J program was used to determine shape differences between individuals. In this program, the differences in LM positions were examined (Klingenberg, 2011). Relative Warp (RW) Analysis was performed in TpsRelw (Version 1.70) program. Consensus graphs of male and female rabbit skulls were created, and the positions of LMs on the figure were determined (Rohlf, 2019). LM coordinate values were compared statistically between genders with the ANOVA test in the PAST (Version 4.02) program.

Results

Table 1 and Table 2 show the results of principal components analysis of the skulls. Accordingly, PC1 explained 34.813%, 57.225% and 42.427% of the total shape differences on dorsal, ventral and lateral views of the skull, respectively. This value was 31.147% on mandible. No significant gender difference according to shape was detected on the images of cranium in PC analysis (Figure 5).

Dorsal images of consensus graphs are shown in Figure 6. No evident difference was observed between groups in

consensus graphs. In Relative Warp Analysis, RW1, RW2, and RW3 values in females were determined as %45.51, %19.31, %11.76, respectively. For males, these values were determined as %35.53, %30.45, %10.91, respectively.

Ventral images of consensus graphs were shown in Figure 6 according to gender. The angle at the LM2 (lateral protrusion of facies facialis) in female rabbits was more comprehensive than in male rabbits on ventral images of consensus graphs. In Relative Warp Analysis RW1, RW2, and RW3 values in females were determined as 70.44%, 12.13%, 6.65%, respectively. For males, these values were determined as 39.37%, 32.99%, 10.25%, respectively.

Lateral consensus graphs are shown in Figure 6. According to the consensus graph, it was determined that the distance between the caudal of the processus nasalis of os incisivum (LM2) and the dorsal of the orbita (LM3) in females was larger than in male rabbits. In the Relative Warp analysis, RW1, RW2, and RW3 values were determined as 41.41%, 18.81%, and 12.00% in females, while it was 50.55%, 16.24%, and 13.97% in males, respectively.

The consensus graph of the mandible according to gender is shown in Figure 6. According to Relative Warp analysis, RW1, RW2, and RW3 values in females were determined as 32.96%, 27.19%, and 13.34% while it was calculated as 48.20%, 23.53%, and 17.17% in males, respectively. Accordingly, the mandibles of male rabbits showed more variation in shape.

The lollipop graph of the dorsal images of PC1 is shown in Figure 7 in MorphoJ program. The most significant shape differences on the skull were at the levels of LM14, LM13, LM4, LM7, and LM5, and there was no change in other

Table 1. Values obtained as a result of principal component analysis in dorsal and ventral images of skull.

Dorsal			Ventral		
PC	Eigenvalue	%Variation	PC	Eigenvalue	%Variation
1	0.000756026	34.813	1	0.00198286	57.225
2	0.000400653	18.449	2	0.000477659	13.785
3	0.000400653	11.752	3	0.000330734	9.5449
4	0.000212493	9.7846	4	0.000255298	7.3678
5	0.000151737	6.987	5	0.000104652	3.0202
6	0.000125615	5.7842	6	7.84149E-05	2.263
7	6.13189E-05	2.8235	7	6.15645E-05	1.7767
8	4.85338E-05	2.2348	8	5.15237E-05	1.487
9	4.39307E-05	2.0229	9	3.59177E-05	1.0366
10	3.12824E-05	1.4405	10	2.79973E-05	0.80799
11	2.97296E-05	1.369	11	1.72693E-05	0.49839
12	1.48024E-05	0.68161	12	1.38285E-05	0.39909
13	1.14935E-05	0.52924	13	8.00428E-06	0.231
14	1.04518E-05	0.48127	14	6.42042E-06	0.18529
15	7.12679E-06	0.32817	15	4.69381E-06	0.13546
16	4.98594E-06	0.22959	16	4.14185E-06	0.11953

Table 2. Values obtained as a result of principal component analysis in lateral images of skull and mandible.

Lateral			Mandible		
PC	Eigenvalue	%Variation	PC	Eigenvalue	%Variation
1	0.00116693	42.427	1	0.000737687	31.147
2	0.000535391	19.466	2	0.0005561	23.48
3	0.000237603	8.6388	3	0.000327111	13.812
4	0.000178557	6.492	4	0.000223374	9.4314
5	0.000149407	5.4322	5	0.000162846	6.8758
6	0.000111646	4.0592	6	0.000103333	4.363
7	0.000102641	3.7318	7	8.80964E-05	3.7197
8	7.62102E-05	2.7709	8	5.42671E-05	2.2913
9	5.12679E-05	1.864	9	4.13815E-05	1.7472
10	3.84636E-05	1.3985	10	2.93863E-05	1.2408
11	2.92237E-05	1.0625	11	1.90679E-05	0.8051
12	1.84826E-05	0.67199	12	9.23555E-06	0.38995
13	1.75771E-05	0.63907	13	7.01224E-06	0.29608
14	1.11656E-05	0.40596	14	4.97431E-06	0.21003
15	7.94422E-06	0.28884	15	2.52123E-06	0.10645
16	6.03891E-06	0.21956	16	1.98749E-06	0.083917

Table 3. "p values" in terms of coordinate values of landmarks on images.

Landmark	Dorsal images		Ventral images		Lateral images		Mandible images	
	x coordinate	y coordinate	x coordinate	y coordinate	x coordinate	y coordinate	x coordinate	y coordinate
LM1	0.9946	0.5458	0.09037	0.2435	0.006952*	0.7329	0.7757	0.1145
LM2	0.04355*	0.6738	0.0001838*	0.02729*	0.0801	0.01667*	0.1526	0.6855
LM3	0.3778	0.9298	0.1774	0.7697	0.6545	0.8376	0.002772*	0.128
LM4	0.02386*	7.907E-05	0.1673	0.348	0.4977	0.9956	0.0002159*	0.003718*
LM5	0.9743	0.9319	0.3624	0.5166	0.727	0.1354	0.8977	0.9296
LM6	0.5194	0.06281	0.9681	0.3081	0.963	0.5439	0.575	0.8135
LM7	0.5529	0.8109	0.3422	0.3345	0.7748	0.9061	0.003816*	0.8783
LM8	0.339	0.7789	0.6815	0.1238	0.2197	0.9523	0.6027	0.4958
LM9	0.03639*	0.7803	0.3091	0.439	0.09262	0.02086*	0.1166	0.6723
LM10	0.3157	0.5699	0.7505	0.558	0.6758	0.9723	0.9297	0.5214
LM11	0.004593*	0.4387	0.3192	0.2468	0.2884	0.8869		
LM12	0.435	0.9797	0.3919	0.8367	0.6352	0.4245		
LM13	0.4968	0.2872	0.03711*	0.3648	0.5978	0.2724		
LM14	0.1624	0.4372	0.3464	0.02249*	0.2344	0.02622*		
LM15			0.3981	0.003332*				

*: p < 0.05

landmarks according to PC1. It was seen that LM4, LM13, and LM14 were in the craniodorsal direction, and LM5, LM7 were in the cranioventral direction in the PC1 graph.

The difference in the shape of the skull between individuals was more at the LM2 (lateral protrusion of facies

facialis) level on the ventral images in the MorphoJ program. It was determined that LM2 was caudolaterally directed (Figure 7).

On the lateral images, the greatest difference in shape of the skull between individuals was observed at the LM2

level and the LM1, LM3, LM4, LM6, LM7, LM10, LM11, LM12, LM13, and LM14 levels. No shape differences were observed at the LM5, LM8, and LM9 levels in PC1 according to the MorphoJ program (Figure 7).

The lollipop graph obtained according to PC1 on the mandible in the MorphoJ program was shown in Figure 7. It was observed that the shape differences between mandibles were more at the LM5, LM7 levels, and less at the LM3, LM4, LM8, LM9, LM6, LM2 and LM10 levels. In the PC1 graph, it was determined that LM5 was in the craniodorsal direction, LM7 was in the cranioventral direction, and LM8 and LM9 were in the cranial direction. No shape difference was observed at the LM1 level.

Comparison of LMs between genders according to coordinate value and p values are presented in Table 3. A statistically significant difference was determined in some landmarks ($p < 0.05$).

Discussion and Conclusion

In the study, the shape of the New Zealand rabbit skull was determined according to gender using the geometric morphometric method. It was observed that there was no significant separation between male and female rabbits in PC analysis. The highest variation among PCs belonged to the PC1 (57.225%) value determined in ventral images. In the analysis performed in the MorphoJ program, it was observed that the shape difference on the skull mainly was on viscerocranium in the lollipop graphics in PC1 between individuals. In the mandible, the difference in shape was most remarkable in the ramus mandible.

Böhmer and Böhmer, (2017) compared the shape of 12 European rabbit and domestic rabbit skulls and determined high variance in the consensus graph at the level of the craniomedial of the os nasale and the caudal of the os occipitale. In the study, unlike the literature (Böhmer and Böhmer, 2017), it was determined that the most variation was at the LM2 (Lateral view, processus nasalis of incisive bone) level.

Cranial shape is affected by genetic and environmental factors as well as different feeding behaviors (Figueirido et al., 2012). In feeding, chewing muscles determine the direction of movement of the jaw and the chewing force (Gürbüz et al., 2020). Böhmer and Böhmer (2017) stated that the shape difference is mainly in the area where the chewing muscles attach. Chewing muscles that help form mandibular movements and break down food have been examined as masseter, temporal and pterygoideus muscles (Schmolke, 1994; Velasco, 1993). Kabak et al. (2007) reported that the masseter muscles start from the medioventral edge of the maxilla and zygomatic arc, and it connects to the mandibular ramus in the rabbit. The lateral part of the temporal muscles starts from the pars squamosa of the parietal and temporal bone, and it connects to the dorsal end of the coronoid process (Kabak ve ark., 2007). In the study, consistent with the literature (Böhmer and Böhmer, 2017), formal differences were observed in the zygomatic arc and parietal bone, where the chewing muscles are attached. It is thought that the reason for these shape differences between

individuals where the chewing muscles are located is due to mandibular movements.

Casanova et al. (2019) used the geometric morphometry method to determine the shape difference between genders in the skulls of wild rabbits ($n = 22$) and toy rabbits ($n = 21$). In this study, a difference in skull shape between genders was observed in toy rabbits ($p = 0.034$) and it was stated that this difference was on the splanchnocranium (viscerocranium). Researchers (Casanova et al., 2019) suggested that this difference is because genetic structure affects the change between genders in the developmental process. In this study, consistent with the literature (Casanova et al., 2019), it was observed that the shape differences on lateral images were mostly on viscerocranium.

Casanova and Miquel (2021) examined cranial asymmetry in toy rabbits according to gender. For this purpose, 46 adult (9, male; 37, female) rabbit skulls were photographed from the dorsal aspect and 13 LMs were marked on them. Researchers (Casanova and Miquel, 2021) reported that the shape differences were mostly on the viscerocranium (LM3, LM4, LM13) on dorsal images of the skull. These differences were mostly on the maxilla (cranial of the zygomatic arc) and the lateral protrusions of the nasal bone (Casanova and Miquel, 2021). This study, consistent with the literature (Casanova and Miquel, 2021), it was observed that the shape differences on dorsal images were mostly on viscerocranium. However, unlike the literature, no difference was observed in LM2 determined on the lateral protrusion of the nasal bone on dorsal images. In particular, the difference in the levels of LM14 (medial of the nasofrontal suture) and LM5 (cranial of the zygomatic arc) was evident. Researchers (Casanova and Miquel, 2021) stated that this difference may be related to the growing process.

Although sexual dimorphism varies greatly in populations, the region on the skeleton that best provides gender discrimination is the cranium and pelvis. According to researchers, while gender determination through morphological observations is estimated at 80% using the skull alone, this rate increases to 90% using the skull and mandible together (Güleç et al., 2003; Scheuer, 2002). In the literature, there are some studies on determining sexual dimorphism using geometric morphometric methods on different animal species (Demircioğlu et al., 2021; Duro et al., 2021; Gündemir et al., 2020; Szara et al., 2022).

Gürbüz et al. (2015) examined the differences according to gender in the New Zealand Rabbit skull with the traditional morphometry method. Researchers (Gürbüz et al., 2015) measured 19 different craniometric values in dorsal and ventral aspects of 20 New Zealand Rabbits, 10 males and 10 females. Gürbüz et al. (2015) found the difference between genders statistically insignificant in their study. In the study, no significant gender difference was detected on skull shape images, which is consistent with the literature (Gürbüz et al., 2015).

In conclusion, the shape of the New Zealand rabbit cranium was analyzed using geometric morphometric procedures. According to principal component analysis, male

and female craniums were not concentrated in a particular region in the ventral, dorsal, and lateral images of skull and mandible. Among the principal component analyzes performed in the study, the highest variation belonged to the PC1 (57.225%) determined in the ventral images. As a result of the Relative Warp Analysis, the variation among females (RWA1: 70.44%) was determined most on ventral images, while the variation among males (RWA1: 50.55%) was determined most on lateral images. According to the first principal component on the ventral, dorsal and lateral images, it was observed that the shape difference in the lollipop graphics in the MorphoJ program was higher in the viscerocranium than in the neurocranium. The shape difference in the mandible was on the mandibular ramus. It is thought that the reason for the shape changes in viscerocranium may be due to the difference in chewing function. As a result, we believe that the data obtained will contribute to geometric morphometric studies on the skulls of other rabbit species. It is also essential to provide formal information on the craniums found in zooarchaeological studies.

Acknowledgement

We sincerely thank the Burdur Mehmet Akif Ersoy University Scientific Research Projects -Coordinator (Project number: 0788-YL-21) for supporting of this research work. This study is summarized from the Master Thesis titled "Geometric morphometric analysis of New Zealand Rabbit Cranium" written by Havali AKKAYA.

Conflict of interest

The authors declare that they have no actual, potential or perceived conflicts of interest for this article.

Ethical permission

Permission was received for this study from Burdur Mehmet Akif Ersoy University HADYEK, dated 13.10.2021 and numbered 820. Additionally, the authors declared that Research and Publication Ethics were complied with.

Financial support

This research was supported by Burdur Mehmet Akif Ersoy University Scientific Research Projects Coordination Office (Project no: 0788-YL-21). This study is summarized from the Master's Thesis titled "Geometric Morphometric Analysis of New Zealand Rabbit Skull" written by Havali AKKAYA.

Similarity Rate

We declare that the similarity rate (excluding summary, abstract and references) of the article is 2% as stated in the report uploaded to the system.

Explanation

This study is summarized from the Master Thesis titled as "Geometric morphometric analysis of New Zealand Rabbit cranium" written by Havali AKKAYA. At the same time, this study was presented as an oral/abstract at the "ICAFVP 2nd International Conference on Agriculture, Food, Veterinary and Pharmacy Sciences, 2023".

Author Contributions

Idea/Concept: HA, IG
Design: HA
Supervision/Consultancy: IG
Data Collection and/or Processing: HA, IG
Analysis and/or Comment: HA, IG
Source Search: HA
Writing of the Article: HA, IG
Critical Review: IG

References

- Adams DC, Rohlf FJ, Slice DE, 2004: Geometric morphometrics: ten years of progress following the 'revolution'. *Ital J Zool*, 71, 5-16.
- Aytek Aİ, 2017: Geometrik Morfometri. *MASROP E-Dergi*, 11, 1-7.
- Bookstein FL, 1997: Morphometric tools for landmark data: Geometry and biology. Cambridge University Press.
- Boz İ, Manuta N, Özkan E, Kahvecioğlu O, Pazvant G, Ince N G, Gundemir O, 2023: Geometric morphometry in veterinary anatomy. *Veterinaria*, 72(1), 15-27.
- Böhmer C, Böhmer E, 2017: Shape variation in the craniomandibular system and prevalence of dental problems in domestic rabbits: a case study in evolutionary veterinary science. *Vet Sci*, 4(1), 5.
- Casanova P, Miquel P, 2021: Diferente Asimetría Craneal Según Sexo en el Conejo Toy. *Int J Morphol*, 39(3), 864-868.
- Casanova P, Pere M, Lloveras L, Nadal J, 2019: Skull sexual dimorphism appears in toy rabbits. *Commun Fac Sci Univ Ankara Series C Biology*, 28(2), 225-231.
- Demiraslan Y, Demircioğlu İ, Gürbüz İ, Aksünger Karaavcı F, Ortadeveci A, Özgel Ö, 2023: Could there be a relationship between feeding characteristics and the shape of condylus occipitalis of foramen magnum in mammals? *Turkish J Vet and Anim Sci*, 47, 386 - 486.
- Demircioğlu İ, Demiraslan Y, Gürbüz İ, Dayan MO, 2021: Geometric Morphometric Analysis of Skull and Mandible in Awassi Ewe and Ram. *Kafkas Univ Vet Fak Derg*, 27, 43-49.
- Duro S, Gundemir O, Sönmez B, Jashari T, Szara T, Pazvant G, Kambo A, 2021: A different perspective on sex dimorphism in the adult Hermann's tortoise: geometric morphometry. *Zool Stud*, 60.
- Erol AS, Aytek Aİ, 2016: Antik Anadolu toplumlarının geometrik morfometrik karşılaştırılmaları. Doctoral dissertation, Antropoloji (Paleoantropoloji) Anabilim Dalı, Ankara Üniv Enstitue of Sosial Science, Ankara/Türkiye.
- Farag FM, Daghsh SM, Khalifa EFM, Hussein MM, Hagrass S, 2012: Anatomical studies on the skull of the domestic rabbit (*Oryctolagus cuniculus*) with special reference to the hyoid apparatus. *J Vet Anat*, 5(2), 49-70.
- Figueirido B, Serrano AFJ, Palmqvist P, 2012: Geometric morphometrics shows differences and similarities in skull

- shape between the red and giant pandas. *J Zool*, 286 (4), 293-302.
- Güleç E, Sağır M, İsmail ÖZER, 2003: İnsan iskeletlerinde Foramen Magnum'dan Cinsiyet Tayini. *Ankara Üniv DTCF Derg*, 43(1), 1-9.
- Gündemir O, Özkan E, İnce NG, Pazvant G, Demircioğlu İ, Aydoğdu S, Dayan MO, 2020: Investigation of Os Coxae in Horses Using Geometric Morphometry Method. *Harran Üniv Vet Fak Derg*, 9, 170-176.
- Gündemir O, Szara T, Eravcı E, Karabağlı M, Mutlu Z, Yılmaz O, Büyükünäl SK, Blagojevic M, Parés-Casanova PM, 2023: Examination of Shape Variation of the Skull in British Shorthair Scottish Fold and Van Cats. *Animals*, 13 (614), 1-11.
- Gürbüz İ, Aytek A, Demiraslan Y, Onar V, Özgel Ö, 2020: Geometric morphometric analysis of cranium of wolf (*Canis lupus*) and German shepherd dog (*Canis lupus familiaris*). *Kafkas Univ Vet Fak Derg*, 26, 525-532.
- Gürbüz İ, Demiraslan Y, Aslan K, 2015: Morphometric analysis of the skull of New Zealand rabbit (*Oryctolagus cuniculus* L.) according to gender. *Arc J Anim Vet Sci*, 1(2), 27-32.
- Gürbüz İ, Demiraslan Y, Rajapakse C, Weerakoon DK, Fernando S, Spataru MC, Gündemir O, 2022: Skull of the Asian Paradoxurus Hermaphroditus and the golden Paradoxurus Zeylonensis palm civet Geometric morphometric analysis using palate tooth and frontal landmarks. *Anat Histol Embryol*, 51(6), 718-727.
- Hammer Ø, Harper DAT, Ryan PD, 2001: Past: Paleontological statistics software package for education and data analysis. *Palaeontol Electron*, 4(1), 1-9.
- Kabak M, Gültiken ME, Onuk B, 2007: Yeni Zelanda tavşanında (*Oryctolagus cuniculus* L.) articulatio temporomandibularis ve çiğneme kaslarının anatomisi. *Ankara Üniv Vet Fak Derg*, 54(3), 149-15.
- Klingenberg CP, 2011: MorphoJ: an integrated software package for geometrik morphometrics. *Mol Ecol Resour*, 11, 353-357.
- Kozma C, Macklin W, Cummins LM, Mauer R, 1974: Anatomy, physiology and biochemistry of the rabbit. *The biology of the laboratory rabbit*, 12(1), 55-58.
- Kraatz B, Sherratt E, 2016: Evolutionary morphology of the rabbit skull. *PeerJ*, 4, e2453.
- Mapara M, Thomas BS, Bhat KM, 2012: Rabbit as an animal model forexperimental research. *Dent Res J*, 9(1), 111-118.
- McLaughlin CA, Chiasson RB, 1979: Laboratory Anatomy of the Rabbit. Wm C Brown Publishers, USA.
- Mitteroecker P, Gunz P, 2009: Advances in Geometric Morphometrics. *Evol Biol*, 36, 235-247.
- Rohlf FJ, 2017: TpsSmall Version 1.34. Ecology & Evolution, SUNY at Stone Brook, USA.
- Rohlf FJ, 2018: TpsDig Version 2.31. Ecology & Evolution, SUNY at Stone Brook, USA.
- Rohlf FJ, 2019: TpsUtil program Version 1.79. Ecology & Evolution, State University of New York, Stony Brook, NY.
- Scheuer L, 2002: Application of Osteology to Forensic Medicine. *Clin Anat*, 15, 297-312.
- Schmolke C, 1994: The relationship between the temporomandibular joint capsule, articular disc and jaw muscles. *J Anat*, 184(2), 335.
- Slice DE, 2007: Geometrik morphometrics. *Annu Rev Anthropol*, 36, 261-281.
- Szara T, Duro S, Gündemir O, Demircioğlu İ, 2022: Sex determination in Japanese Quails (*Coturnix japonica*) using geometric morphometrics of the skull. *Animals*, 12(3), 302.
- Taibo A, 2014: Veterinary Medical Terminology Guide and Workbook. 2nd ed., WILEY.
- Velasco JM, Vazquez JR, Collado JJ, 1993: The relationships between the temporomandibular joint disc and related masticatory muscles in humans. *J Maxillofac Surg*, 51 (4), 390-395.
- Yalçın H, Kaya MA, 2009: Anadolu yaban koyunu ve Akkaraman koyununun kafa kemikleri üzerinde karşılaştırılmalı geometrik morfometri. *Atatürk Üniv Vet Bil Derg*, 2, 105-116.
- Yaprak A, Özgel Ö, Demiraslan Y, 2023: Geometric Morphometric Analysis of Skull in Honamlı, Hair, Kilis and Saanen Goat Using Dorsal Landmarks. *Kocatepe Vet J*, 16(1), 86-92.
- Zelditch ML, Swiderski DL, Sheets HD, Fink WL, 2004: Geometric morphometrics for biologists: A primer. *Elsevier Academic Press*.



Investigation of Etiological Prevalence of Neonatal Calves with Acute Diarrhea in Şanlıurfa Province with Immunochromatographic Test

Canberk BALIKÇI^{1,a,*}, Erdem GÜLERSOY^{1,b}, Adem ŞAHAN^{1,c}, İsmail GÜNAL^{1,d}, Fatma AKDAĞ^{1,e}, Esmâ KİSMET^{1,f}, Bilal İLGİNOĞLU^{1,g}

¹Department of Internal Medicine, Faculty of Veterinary Medicine, Harran University, Şanlıurfa, Türkiye.

^aORCID: 0000-0001-7473-5163;

^bORCID: 0000-0001-8511-0150;

^cORCID: 0000-0002-4779-0893;

^dORCID: 0000-0003-3679-4132;

^eORCID: 0009-0000-4815-2562;

^fORCID: 0000-0002-2906-074X;

^gORCID: 0009-0001-1510-9194;

Received: 18.12.2023

Accepted: 19.02.2024

How to cite this article: Balıkçı C, Gülersoy E, Şahan A, Günal I, Akdağ F, Kismet E, İlginoğlu B. (2024).

Investigation of Etiological Prevalence of Neonatal Calves with Acute Diarrhea in Şanlıurfa Province with Immunochromatographic Test. Harran Üniversitesi Veteriner Fakültesi Dergisi, 13(1): 22-27.

DOI:10.31196/huvfd.1406507.

***Correspondence:** Canberk BALIKÇI

Department of Internal Medicine, Faculty of Veterinary Medicine, Harran University, Şanlıurfa, Türkiye.

e-mail: canberkbalicki@gmail.com

Available on-line at:

<https://dergipark.org.tr/tr/pub/huvfd>

Abstract: Neonatal calf diarrhea is a significant global concern, frequently causing morbidity and mortality and resulting in substantial economic losses. This study aimed to assess the prevalence of *E. coli* F5, *Clostridium perfringens*, *Cryptosporidium* spp., *Rotavirus*, *Coronavirus*, and *Giardia* spp. as contributors to diarrhea in neonatal calves in Şanlıurfa province. We also evaluated the clinical severity associated with these etiological agents. The study involved 123 neonatal calves (62 males, 61 females) aged 1-28 days from Şanlıurfa province with acute diarrhea. Calf Health Scores (CHS) were assigned based on clinical examination data. Rapid diagnostic tests were conducted on stool samples to identify *E. coli* F5, *Clostridium perfringens*, *Cryptosporidium* spp., *Rotavirus*, *Coronavirus*, and *Giardia* spp. regardless of mono or co-infection status, the rapid test results showed a prevalence of 9.76% for *E. coli* F5, 41.46% for *C. perfringens*, 30.89% for *Cryptosporidium* spp., 16.26% for *Rotavirus*, 13% for *Coronavirus*, and 27.64% for *Giardia* spp. CHS varied, with the highest score observed in *E. coli* F5 + *Giardia* spp. co-infection (CHS: 7) and the lowest in *Coronavirus* + *Rotavirus* co-infection (CHS: 4). In Şanlıurfa province, *C. perfringens* and *Cryptosporidium* spp. were identified as the most common agents. It has been determined that as the etiological factor diversity increases CHS may increase but there may be different variables that change CHS. These results are significant for developing effective diagnosis and control strategies for the prominent etiologies of diarrhea in calves.

Keywords: Calf, Clinical score, Diarrhea, Etiology, Neonatal, Prevalence.

Şanlıurfa İlindeki Akut İshalli Neonatal Buzağların İmmunokromatografik Test ile Etiyolojik Prevalanslarının Araştırılması

Özet: Neonatal buzağı ishalleri, yapılan tedavi masrafları, buzağların büyüme ve performans kayıpları (et ve süt verimi) ile buzağı ölümleri nedeniyle ciddi ekonomik kayıplara neden olduğundan dolayı, dünya çapında sık bildirilen, en önemli morbidite ve mortalite sebeplerindedir. Bu çalışmanın amacı; Şanlıurfa ilindeki akut ishalli neonatal buzağlarda görülebilen ishalin etiolojisinde rol oynayan *E. coli* F5, *Clostridium perfringens*, *Cryptosporidium* spp., *Rotavirus*, *Coronavirus* ve *Giardia* spp. etkenlerinin prevalansını tespit etmek ve etiyojik etkenlerin klinik şiddetini değerlendirmektir. Araştırmaya, Şanlıurfa ilinden 1-28 günlük yaşta, 62 adet erkek ve 61 adet dişi olmak üzere 123 adet akut ishalli neonatal buzağı dahil edildi. Dahil edilen buzağlar, yapılan klinik muayene neticesinde elde edilen veriler ile buzağı sağlık skorları (BSS) belirlendi. Takibinde, buzağlardan alınan dışkı örneklerinden *E. coli* F5, *C. perfringens*, *Cryptosporidium* spp., *Rotavirus*, *Coronavirus* ve *Giardia* spp. etkenlerinin belirlenmesi için hızlı tanı test kiti analizleri yapıldı. Dışkıdan yapılan hızlı test kiti sonuçları neticesinde mono ve ko-enfeksiyon durumlarına bakılmaksızın yaygınlıkları; %9,76 *E. coli* F5, %41,46 *C. perfringens*, %30,89 *Cryptosporidium* spp., %16,26 *Rotavirus*, %13 *Coronavirus* ve %27,64 *Giardia* spp. tespit edildi. Yapılan BSS'ye göre en yüksek skorun *E. coli* F5 + *Giardia* spp. koenfeksiyonuna (BSS: 7) ait olduğu, en düşük skorun ise *Coronavirus* + *Rotavirus* koenfeksiyonuna (BSS: 4) ait olduğu saptanmıştır. Şanlıurfa ilinde gerçekleştirilen bu çalışma ile bölgede en çok *C. perfringens* ve *Cryptosporidium* spp. etkenlerinin bulunduğu, etiyojik etken çeşitliliğinin arttıkça BSS'yi arttırabileceği fakat BSS'yi değiştiren farklı değişkenlerin de olabileceği tespit edilmiştir. Bu sonuçlar, buzağlarda ishalin öne çıkan etiyojilerine yönelik etkin tanı ve kontrol stratejileri geliştirme açısından önemlidir.

Anahtar Kelimeler: Buzağı, Etiyoloji, İshal, Klinik skor, Neonatal, Prevalans.

Introduction

The neonatal period in calves is a critical phase during which physiological functions develop and adapt to life after birth (Constable et al., 2017; Smith, 2015). Although calves have higher body fluids than adults, neonatal diarrhea is a significant health issue. This is attributed to the limited compensation and regulation ability, leading to rapid fluid-electrolyte losses, particularly in agammaglobulinemic births (Aydođdu and Güzelbekteř, 2018).

Neonatal calf diarrhea is caused by infectious agents and non-infectious factors (managerial, host factor, nutritional, and environmental factors, etc.) (Bendali et al., 1999; Blanchard, 2012). The most important etiological factors include bacterial (*C. perfringens*, *E. coli*), viral (*Coronavirus*, *Rotavirus*), and parasitic (*Cryptosporidium parvum*, *Eimeria* spp., *Giardia* spp.) factors (Aydođdu et al., 2018a; Güzelbekteř et al., 2007; Kaske and Kunz, 2003).

Diarrhea is recognized as the health problem with the highest mortality and morbidity in neonatal calves (Aygün and Yıldız, 2018; Yıldız et al., 2018). Consequently, treatment costs, the negative impact of diarrhea on calf growth and productivity, and deaths contribute to economic losses (Aydođdu et al., 2018a; Aydođdu et al., 2018b). Rapid identification of the causes of diarrhea in calves and appropriate treatment are reported to reduce losses in the neonatal period (Kalinbacak, 2003).

The aim of this study was to determine the etiology of diarrhea in neonatal calves with acute diarrhea in řanlıurfa province. This provides etiological prevalence data for future studies on neonatal calves with diarrhea and contributes to the scientific literature. Additionally, the study aimed to assist in developing treatment and prophylaxis strategies by providing etiological prevalence information to veterinarians working in the region. Furthermore, the severity of clinical findings in calves with neonatal diarrhea, which may vary according to etiological diversity, was determined using the Calf Health Scores (CHS), a scoring system that indicates the degree of severity of clinical findings in calves.

Material and Methods

Ethics committee approval: This study was carried out with the approval of Harran University Animal Experiments Local Ethics Committee, Session No. 2022/002, Decision No. 01-13.

Animal material: The animal material of the study comprised 123 Holstein and Simmental breed calves in the neonatal period (1-28 days of age) brought to Harran University Faculty of Veterinary Medicine, Animal Hospital, Department of Internal Medicine with diarrhea from August 2022 to November 2023.

Inclusion/Exclusion criteria: The study did not include calves that had previously received any medical intervention for diarrhea (such as fluid therapy, antibiotics, vitamin-mineral supplements, and positive inotrope applications), which may lead to errors in making etiological determinations.

Clinical and laboratory examinations: Clinical examinations were performed on each calf meeting the study criteria, including the evaluation of palpable lymph nodes, auscultation of the heart and lungs to measure pulse and respiration rates, and assessing the parameters included in the Calf Health Score (CHS) (McGuirk, 2013). The CHS of each calf was calculated and recorded as a result of clinical examinations.

After clinical examinations and CHS calculation, fecal samples taken from the rectum by massage and/or during spontaneous defecation were examined for six etiological agents (*C. perfringens*, *Cryptosporidium* spp., *Coronavirus*, *Rotavirus*, *E. coli* F5, and *Giardia* spp.) using immunochromatographic rapid diagnostic test kits (BIO K 306 - Rainbow Calf Scours 5, Belgium, and VET Diagnostix *Giardia* AG Test, China) according to the manufacturer's instructions.

Statistical analysis: The prevalence of both pathogens and co-infection diarrheal etiology among the calves with 95% confidence intervals was calculated by dividing the number of positive cases by the total number of the enrolled calves with diarrhea. All data were summarized using a statistical software (SPSS 25.00 for Windows, IBM).

Results

Etiological prevalence, CHS, age, and sex data of the 123 neonatal calves with diarrhea evaluated in the study are summarized in Table 1. In 87.8% of the 123 neonatal calves with acute diarrhea included in the study, at least one agent was found positive in the test kits. The percentages of positive cases by at least 2, 3, and 4 etiologic agents were 38.21%, 11.38%, and 4.07%, respectively. Positivity by 5 or more etiologic agents was not observed in the cases evaluated within the scope of the study. The mean CHS score and mean daily age of the positive cases were 5.02 and 12.55, respectively. Out of the 123 calves, 62 were male, and 61 were female. The percentage distributions of the etiological agents of the present study were presented in Figure 1.

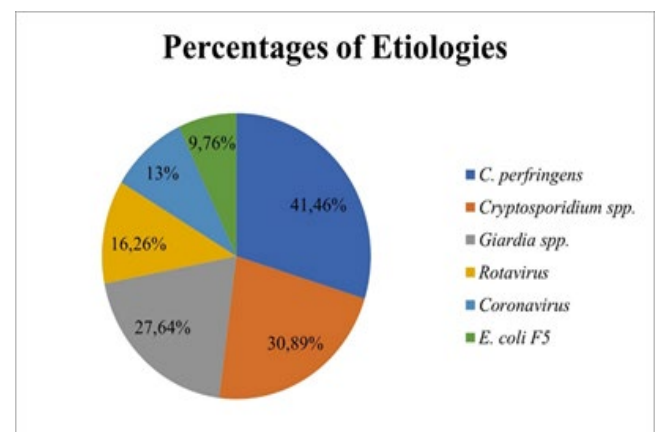


Figure 1. Percentage distribution of etiologies.

Discussion and Conclusion

Diarrhea is recognized as a significant health issue in neonatal calves (Uhde et al., 2008). Rapid identification of diarrhea etiology during the neonatal period and the implementation of effective treatments are reported to

reduce economic, yield, and life losses in this critical period (Kalinbacak, 2003). Our study conducted in Şanlıurfa province, we determined the prevalence of etiological agents causing neonatal acute diarrhea in calves, regardless of mono or coinfection. The identified agents and their respective prevalence rates were as follows: *C. perfringens*

Table 1. Etiological prevalence, CHS, age and sex data in neonatal calves with acute diarrhea.

Etiology	Number of calves (n=123)	Prevalence (%)	CHS Mean (Min-Max)	Age (Day) Mean (Min-Max)	Sex (M/F)
Negative	15	12,2	4,67 (2-8)	11 (1-25)	10/5
<i>C. perfringens</i>	51	41,46	4,92 (2-9)	10,82 (2-28)	26/25
<i>E. coli</i> F5	12	9,76	5,75 (3-8)	3,67 (1-7)	6/6
Rotavirus	20	16,26	4,4 (2-9)	10,45 (2-28)	10/10
Coronavirus	16	13	5 (2-8)	13,69 (3-28)	8/8
<i>Cryptosporidium</i> spp.	38	30,89	5,16 (3-9)	14,71 (7-28)	22/16
<i>Giardia</i> spp.	34	27,64	3,88 (1-6)	16,82 (2-28)	18/16
<i>C. perfringens</i> + <i>Cryptosporidium</i> spp.	12	9,76	5,67 (3-9)	14,17 (7-28)	9/3
<i>C. perfringens</i> + <i>E. coli</i> F5	6	4,88	5,67 (3-8)	3,67 (3-7)	3/3
<i>C. perfringens</i> + Coronavirus	10	8,13	5,17 (2-8)	15,5 (6-28)	7/3
<i>C. perfringens</i> + Rotavirus	7	5,69	4,29 (2-9)	7,86 (2-14)	5/2
<i>C. perfringens</i> + <i>Giardia</i> spp.	12	9,76	4,75 (2-8)	18,17 (13-28)	7/5
<i>E. coli</i> F5 + Rotavirus	2	1,63	6 (5-7)	4,5 (2-7)	1/1
<i>E. coli</i> F5 + <i>Giardia</i> spp.	1	0,81	7 (7-7)	5 (5-5)	1/0
<i>Cryptosporidium</i> spp. + Rotavirus	3	2,44	5,67 (3-9)	9,33 (8-10)	1/2
<i>Cryptosporidium</i> spp. + Coronavirus	6	4,88	5,83 (3-8)	14,17 (7-28)	3/3
<i>Cryptosporidium</i> spp. + <i>Giardia</i> spp.	10	8,13	4,6 (3-6)	15,3 (10-28)	8/2
Coronavirus + Rotavirus	4	3,25	3 (2-5)	9,25 (3-14)	2/2
Coronavirus + <i>Giardia</i> spp.	6	4,88	5,33 (2-8)	17 (10-28)	4/2
Rotavirus + <i>Giardia</i> spp.	4	3,25	3,5 (2-5)	13,5 (2-28)	1/3
<i>C. perfringens</i> + Coronavirus + <i>Giardia</i> spp.	6	4,88	5,17 (2-8)	17,83 (10-28)	4/2
<i>C. perfringens</i> + <i>Cryptosporidium</i> spp. + <i>Giardia</i> spp.	4	3,25	5,5 (4-6)	18,25 (10-28)	4/0
<i>C. perfringens</i> + <i>Cryptosporidium</i> spp. + Coronavirus	4	3,25	5,5 (3-7)	13,75 (7-28)	3/1
<i>C. perfringens</i> + <i>E. coli</i> F5 + Rotavirus	1	0,81	7 (7-7)	2 (2-2)	1/0
<i>Cryptosporidium</i> spp. + Rotavirus + Coronavirus + <i>Giardia</i> spp.	1	0,81	5 (5-5)	10 (10-10)	0/1
<i>C. perfringens</i> + Rotavirus + Coronavirus + <i>Giardia</i> spp.	1	0,81	2 (2-2)	14 (14-14)	0/1
<i>C. perfringens</i> + <i>Cryptosporidium</i> spp. + Rotavirus + Coronavirus	1	0,81	3 (3-3)	10 (10-10)	1/0
<i>C. perfringens</i> + <i>Cryptosporidium</i> spp. + Coronavirus + <i>Giardia</i> spp.	2	1,63	6 (6-6)	19 (10-28)	2/0

*M: Male, F: Female

(41.46%), *Cryptosporidium* spp. (30.89%), *Giardia* spp. (27.64%), *Rotavirus* (16.26%), *Coronavirus* (13%), and *E. coli* F5 (9.76%). Among co-infections, the most common combinations were *C. perfringens* + *Cryptosporidium* spp. and *C. perfringens* + *Giardia* spp. (both 9.76%).

We observed significant differences when comparing our findings with studies conducted in Aydın province, In a study involving 198 calves in Aydın, the prevalence of *Giardia duodenalis* was reported as 17.67% (Gültekin et al., 2017). Another study in the same region reported a prevalence of 7.19% (Balıkçı et al., 2023). The disparity between these

studies can be attributed to variations in the age distribution of cases (0-3 months and 1-28 days age, respectively). It was observed that *Giardia* spp. was detected at a lower intensity in calves in the neonatal period compared to calves in the post-neonatal period. In our study, where calves up to 28 days were included, all positive cases for *Giardia* spp. accounted for 27.64%, indicating a higher prevalence compared to Aydın province.

A study conducted on 71 calves in Van province reported a high prevalence of *Giardia duodenalis*, detected using both rapid test kits (38 cases positive) and PCR (46 cases positive) (Ayan et al., 2019). However, the prevalence found in our study (27.64%) suggests that the high prevalence in Van province might be influenced by the inclusion of calves up to 90 days of age. Contrarily, a study in Aydın province (Gültekin et al., 2017) focusing on calves up to 3 months reported a lower prevalence compared to Van province. These regional differences indicate that Van province may have a higher prevalence of *Giardia* spp. than Şanlıurfa province. Notably, our study's *Giardia* spp. prevalence (27.64%) was considerably higher than reported levels in Siirt (4%) (Kozat and Tuncay, 2018), Sivas (4.13%) (Değerli et al., 2005), and Tokat (16.82%) (Coşkun and Kaya, 2018).

In a study investigating the impact of various etiological factors on haemogram parameters in neonatal calf diarrhea in 44 calves aged 1-20 days in Burdur province, the prevalence of *C. perfringens*, *E. coli*, *Cryptosporidium* spp., *Rotavirus*, and *Coronavirus* were determined to be 43.2%, 9.1%, 38.6%, 22.7%, and 11.4%, respectively, with 22.7% of cases showing no positivity of these agents (Atcalı and Yıldız, 2020). In another study conducted in 50 calves aged 1-30 days in Burdur province, it was reported that *Cryptosporidium* spp., *Rotavirus*, *E. coli*, *Giardia* spp., *Coronavirus* were detected at rates of 24%, 12%, 6%, 6% and 2%, respectively (Mamak et al., 2023). The results of two studies conducted in Burdur province show that even a change in the 10-day age distribution of calves in the same region can change the prevalence of etiology. The observed disparities in etiological agent-based prevalences between this study and others may be attributed to varying distributions in different regions and/or differences in calf age distribution (Atcalı and Yıldız, 2020, Mamak et al., 2023) compared to this study (1-28 days age).

Another study in Uşak province, involving 100 neonatal calves with diarrhea aged 1-28 days, reported the prevalence of *C. perfringens*, *E. coli*, *Cryptosporidium* spp., *Rotavirus*, and *Coronavirus* as 21%, 15%, 18%, 31%, and 10%,

respectively, with 10% of cases were negative (Sezer and Akgül, 2022). Given the consistent age distribution in both this study and the Uşak study, differences in the prevalence of the etiological factor (*C. perfringens*) may be attributed to regional variations. Comparing this study with the Uşak study, a proportional similarity was observed in the prevalence of *E. coli*, *Rotavirus*, *Cryptosporidium* spp., and *Coronavirus* (9.76%, 16.26%, 30.89%, and 13%, respectively), suggesting a consistent intensity of neonatal calf diarrhea caused by these agents in the two regions.

In a study conducted on 192 calves with diarrhea aged 2-40 days in the South-Eastern region of Turkey, the prevalence of *E. coli* K99, *Cryptosporidium* spp., *Rotavirus*, and *Coronavirus* etiologies were investigated and found to be 26%, 47.7%, 55.2%, and 5.1%, respectively, with 7.3% reported as negative (İçen et al., 2013). Despite both studies being conducted in similar geographical regions, a divergence in etiological prevalence was observed, indicating changes in regional prevalences over the 10-years gap between the two studies. In an another study, *Coronavirus* prevalence (5.32%) was found in <3 months old calves with diarrhea in Şanlıurfa province, located in the same region (Abikoğlu and Özgünlük, 2022). It was reported that the prevalence found in this study was low, but also the coronavirus tends to spread rapidly. Although the study was published in 2022, it is noteworthy that the faecal samples are primarily from 2016. Therefore, similar to the comparison in the other study (İçen et al., 2013), time elapsed (7 years) between our study and the aforementioned study (Abikoğlu and Özgünlük, 2022) cannot negligible. In summary, it can be said that the prevalence of *Coronavirus* in the region has increased over the years.

In Sivas province, a study on 138 calves with diarrhea aged 1-30 days reported the prevalence of *E. coli*, *C. perfringens*, *Cryptosporidium* spp., *Rotavirus*, and *Coronavirus* agents as 26%, 38%, 7%, 22%, and 9%, respectively, with a 20% negative rate (Kuliğ and Coşkun, 2019). Although both studies shared a similar age distribution range for calves with diarrhea and observed a high prevalence of the causative agent (*C. perfringens*), the prevalence of other etiological agents differed between the two studies.

In Elazığ province, a study on 30 calves with diarrhea aged 1-28 days reported the prevalence of *E. coli*, *Cryptosporidium* spp., *Rotavirus*, and *Coronavirus* agents as 17%, 0%, 30%, and 13%, respectively (Al and Balıkçı, 2012). *Cryptosporidium* spp., absent in the study, may account for the lower case count compared to other studies. Another study reported a *Cryptosporidium* spp. prevalence of 7.2% in Elazığ province (Özer et al., 1990). *Rotavirus* prevalence in the Al and Balıkçı (2012) study aligns with those in Burdur (Atcalı and Yıldız, 2020), Uşak (Sezer and Akgül, 2022), Elazığ (Al and Balıkçı, 2012) and our study, indicating *Rotavirus* as a common agent.

A study in Siirt province, examining 100 calves with diarrhea aged 0-90 days, reported the prevalence of *E. coli* K99, *Cryptosporidium* spp., *Rotavirus*, *Coronavirus*, and *Giardia lamblia* agents as 18%, 22%, 25%, 7%, and 4%, respectively, with 52% of cases were negative results (Kozat

and Tuncay, 2018). In our study, the prevalence of *Giardia* spp. (27.64%) was notably high, and the prevalence of *E. coli* was almost double (9.76%) compared to the Siirt study, consistent with the other etiological factors.

In Tokat province, a study on 107 calves with diarrhea aged 3-28 days reported the prevalence of *E. coli* K99, *Cryptosporidium* spp., *Rotavirus*, *Coronavirus*, and *Giardia lamblia* agents as 7.48%, 11.21%, 44.86%, 9.35%, and 16.82%, respectively (Coşkun and Kaya, 2018). *Rotavirus* had the highest prevalence, aligning with studies in Burdur (Atcalı and Yıldız, 2020), Uşak (Sezer and Akgül, 2022), and Elazığ (Al and Balıkçı, 2012). In our study, *Rotavirus* was found to have the fourth highest prevalence after *C. perfringens*, *Cryptosporidium* spp. and *Giardia* spp.

An investigation encompassing 175 diarrheic calves aged 1-34 days in Kayseri and its adjacent provinces (Sivas, Nevşehir, Yozgat, Niğde, Kırşehir) revealed prevalence rates of 37.7% for *Coronavirus*, 34.9% for *Cryptosporidium* spp., 30.3% for *Rotavirus*, 15.4% for *E. coli*, and 0.6% for *Giardia* spp. (Ekinci et al., 2021). When the aforementioned study is compared with this study, it is noteworthy that the prevalence of *Rotavirus* is similar. Compared to the aforementioned study, *Giardia* spp. had high prevalence in this study. These findings support that the prevalence of etiology of calves with diarrhea may vary depending on geographical region differences.

In a study conducted in 30 calves aged 1-10 years in Kars province, it was reported that *E. coli*, *Rotavirus*, *Coronavirus* and *Cryptosporidium* spp. were detected at the rates of 63.33%, 43.33%, 26.66%, 3.33% respectively (Akyüz et al. 2022). It is noteworthy that *E. coli*, which exhibited the highest prevalence in the aforementioned study, demonstrated the lowest prevalence in this study (9.76%). *E. coli* is commonly implicated as the etiological agent of diarrhea in calves within the initial four days of life (Foster and Smith, 2009). Thus, the disparity in prevalence is likely attributable to variations in the age range of the calves utilized across the two studies, rather than differences in geographical regions.

In this study, 12.2% of the calves were identified as negative. Diarrhea in neonatal calves may be due to non-infectious causes such as managerial, host factor, nutritional, and environmental factors, in addition to infectious causes including bacterial (*C. perfringens*, *E. coli*), viral (*Coronavirus*, *Rotavirus*), and parasitic (*Cryptosporidium parvum*, *Eimeria* spp., *Giardia* spp.) (Aydoğdu et al., 2018a; Güzelbekteş et al., 2007; Kaske and Kunz, 2003). Other infectious agents like *Salmonella* spp., *Adenovirus*, Bovine Viral Diarrhea Virus, *Torovirus*, *Calicivirus*, *Nebovirus*, *Norovirus*, and *Candida* spp. may also contribute to neonatal calf diarrhea (Cho and Yoon, 2014). The negative cases in this study may arise from both non-infectious and other etiological agents.

Limited data exist on the severity of clinical findings based on etiology in neonatal calves with diarrhea. In a study in Siirt province, cases were classified into mild, moderate, and severe classes based on dehydration severity, revealing that 28.6% of cases with mild dehydration were monoinfections and 71.4% were negative, 60% of cases with moderate dehydration were co-infections, and 40% were

negative, and 64.3% of cases with severe dehydration were coinfections, with 35.7% being negative (Kozat and Tuncay, 2018). In another prevalence study with 167 calves with neonatal acute diarrhea aged between 1-28 days, a scoring system (CHS) was used (Balıkçı et al., 2023). The highest score was observed in calves positive for *E. coli* K99 (6.29), and a similarly high score was noted in calves positive for *Cryptosporidium* spp. + *Rotavirus* (6.28). In our study, the most severe findings (high score) belonged to *E. coli* F5 + *Giardia* spp. (7), while the lowest score belonged to *Coronavirus* + *Rotavirus* (4). *E. coli* appeared to induce severe clinical outcomes in both studies. These findings suggest that co-infections may lead to more severe clinical manifestations than monoinfections, but the severity may vary based on the etiological agent causing monoinfection, emphasizing the need for further studies with larger sample sizes to determine variations in clinical outcomes based on etiological agents.

In conclusion, this study sheds light on the etiology of neonatal calf diarrhea in Şanlıurfa province, providing valuable data for future studies and aiding veterinarians in developing effective treatment and prophylaxis strategies. The prevalence of *C. perfringens*, *E. coli* F5, *Cryptosporidium* spp., *Rotavirus*, *Coronavirus*, and *Giardia* spp. was determined as 41.46%, 9.76%, 30.89%, 16.26%, 13%, and 27.64%, respectively, in calves with acute diarrhea. Notably, 12.2% of the cases tested negative for these investigated agents, suggesting the involvement of other infectious agents and non-infectious causes. *C. perfringens* and *Cryptosporidium* spp. emerged as the most common agents in the region. The findings contribute to the scientific understanding of calf diarrhea etiology, emphasizing the need for tailored treatment and preventive measures. Additionally, the study provides essential information for future research and supports veterinarians in the region. Furthermore, CHS that has a significant place in the health controls of calves, was determined according to the etiologies of neonatal calves with acute diarrhea and a contribution was made to the current literature.

Conflict of Interest

The authors stated that they did not have any real, potential or perceived conflict of interest.

Ethical Approval

This study was approved by the Harran University Animal Experiments Local Ethics Committee (28.03.2022, 2022/002 – 01-13 Number Ethics Committee Decision). In addition, the authors declared that Research and Publication Ethical rules were followed.

Funding

This study was supported by the HÜBAP, (Project Number: 22093).

Similarity Rate

We declare that the similarity rate of the article is 2% as stated in the report uploaded to the system.

Author Contributions

Motivation / Concept: CB

Design: CB, EG, AŞ, İG

Control/Supervision: CB, EG

Data Collection and/or Processing: CB, EG, AŞ, İG, FA, EK, Bİ

Analysis and / or Interpretation: CB, EG, AŞ, İG

Literature Review: CB, EG, AŞ, İG

Writing the Article: CB, EG, AŞ, İG

Critical Review: CB, EG, AŞ, İG

References

- Abikoğlu R, Özgünlük İ, 2022: Şanlıurfa İlindeki İshalli Buzağılarda Bovine Coronavirus Varlığının ELISA Yöntemi ile Araştırılması. *Harran Üniv Vet Fak Derg*, 11 (1), 120-127.
- Akyüz E, Sezer M, Kuru M, Naseri, A. 2022: Changes in hematology, some clinical biochemical parameters and mineral levels in neonatal calves with sepsis due to diarrhea. *Van Vet J*, 33 (1), 26-30.
- Al M, Balıkçı E, 2012: Neonatal İshalli Buzağılarda *Rotavirus*, *Coronavirus*, *E. coli* K99 ve *Cryptosporidium parvum*'un Hızlı Test Kitleri ile Teşhisi ve Enteropatojen ile Maternal İmmünite İlişkisi. *FÜ Sağ Bil Vet Derg*, 26 (2), 73-78.
- Atcalı T, Yıldız R, 2020: Neonatal Buzağı İshallerinde Farklı Etiyolojik Faktörlerin Hemogram Parametreleri Üzerine Etkisi. *MAKU J Health Sci Inst*, 8 (3), 119-127.
- Ayan A, Alıç Ural D, Erdoğan H, Oruç Kılıncı Ö, Gültekin M, Ural K, 2019: Prevalance and Molecular Characterization of *Giardia Duodenalis* in Livestock in Van, Turkey. *IJEES*, 9 (2), 289-296.
- Aydoğdu U, Gülersoy E, Şen İ, 2018b: Buzağı ishalleri ve oral sıvı takviyeleri. *Türkiye Klinikleri J Anim Nutr&Nutr Dis-Special Topics*, 4, 56-64.
- Aydoğdu U, Güzelbekteş H, 2018: Effect of colostrum composition on passive calf immunity in primiparous and multiparous dairy cows. *Vet Med (Praha)*, 63, 1-11.
- Aydoğdu U, Işık N, Ekici ÖD, Yıldız R, Şen İ, Coşkun A, 2018a: Comparison of the effectiveness of halofuginone lactate and paromomycin in the treatment of calves naturally infected with *Cryptosporidium parvum*. *Acta Sci Vet*, 46, 1-9.
- Aygün O, Yıldız R, 2018: Evaluation of thrombomodulin and pentraxin-3 as diagnostic biomarkers in calves with sepsis. *Vet Med (Praha)*, 63, 313-320.
- Balıkçı C, Ural K, Erdoğan H, Gönülveren G, Gültekin M, 2023: Aydın İlinde Akut İshalli Neonatal Buzağılarda Enteropatojenlerin Prevalansının Araştırılması. *Kocatepe Vet J*, 16 (3), 410-419.
- Bendali F, Bichet H, Schelcher F, Sana M, 1999: Pattern of diarrhoe in newborn calves in South-West France. *Vet Res*, 30, 61-74.
- Blanchard PC, 2012: Diagnostics of dairy and beef cattle diarrhea. *Vet Clin North Am Food Anim Pract*, 28, 443-464.
- Cho YI, Yoon KJ, 2014: An overview of calf diarrhea-infectious etiology, diagnosis, and intervention. *J Vet Sci*, 15 (1), 1-17.
- Constable PD, Hinchcliff KW, Done SH, Grünberg W, 2017: Veterinary medicine a textbook of the diseases of cattle, horses, sheep, pigs, and goats. Elsevier, St. Louis Missouri, USA.
- Coşkun A, Kaya K, 2018: Tokat Bölgesindeki Neonatal Buzağı İshallerinin Etiyolojisinin Belirlenmesi. *Manas J Agric Vet Life Sci*, 8 (1), 75-80.
- Değerli S, Çeliksöz A, Kalkan K, Özçelik S, 2005: Prevalence of *Cryptosporidium* spp. and *Giardia* spp. in cows and calves in Sivas. *Turkish J Vet Anim Sci*, 29 (4), 995-999.
- Ekinci G, Tüfekçi E, Onmaz AC, Çitil M, Keleş İ, Güneş V, 2022: Investigation of the Prevalence of Major Enteropathogens in Neonatal Diarrheic Calves Brought to Erciyes University Animal Hospital between 2019-2021 years. *Erciyes Üniv Vet Faki Derg*, 19 (2), 113-122.
- Foster DM, Smith GW, 2009: Pathophysiology of diarrhea in calves. *Vet Clin North Am Food Anim Pract*, 25 (1), 13-36.
- Gültekin M, Ural K, Aysul N, Ayan A, Balıkçı C, Toplu S, Akyıldız G, 2017: Prevalence and Molecular Characterization of *Giardia duodenalis* in Calves in Turkey. *Acta Sci Vet*, 45, 1450.
- Güzelbekteş H, Coşkun A, Şen İ, 2007: Relationship between the degree of dehydration and the balance of acid-based changes in dehydrated calves with diarrhoea. *Bull Vet Inst Pulawy*, 51, 83-87.
- İçen H, Arserim NB, Işık N, Özkan C, Kaya A, 2013: Prevalence of Four Enteropathogens with Immunochromatographic Rapid Test in the Feces of Diarrheic Calves in East and Southeast of Turkey. *Pak Vet J*, 33 (4).
- Kalınbacak A, 2003: İshalli Buzağuların Sıvı Sağaltımında Hipertonik Salin-Dextran ve Oral Elektrolit Solüsyonunun Kullanımı. *Ankara Üniv Vet Fak Derg*, 50, 113-118.
- Kaske M, Kunz HJ, 2003: In: Manual of diarrheal diseases in calves, 15-140. Kamlage Werlag, Auflage Stuttgart.
- Kozat S, Tuncay İ, 2018: Siirt yöresindeki yenidoğan ishalleri buzağılarda *Rotavirus*, *Coronavirus*, *Cryptosporidium* spp., *Escherichia coli* K 99 ve *Giardia lamblia* etkenlerinin prevalansı. *Van Vet J*, 29 (1), 17-22.
- Kulığ CC, Coşkun A, 2019: Sivas ve ilçelerindeki neonatal ishalleri buzağılarda *E. coli*, *Cryptosporidium*, *Clostridium perfringens*, *Rotavirus* ve *Coronavirus* Prevalansı. *Turkish Vet J*, 1 (2), 69-73.
- Mamak N, Kiyıcı, R, Şahinduran Ş, Şensoy S, Akkan HA, Karaca M, Yıldız R, Musabeşoğlu Y, Gökçe Hİ, 2023: Etiological examination of neonatal calf diarrhea cases detected in Burdur region. *MAE Vet Fak Derg*, 8 (2), 55-60.
- McGuirk S, 2013: Calf Health Scoring Chart. University of Wisconsin, School of Veterinary Medicine. https://fyi.extension.wisc.edu/heifermgmt/files/2015/02/calf_health_scoring_chart.pdf, Erişim Tarihi; 01.12.2023
- Özer E, Erdoğan SZ, Köroğlu E, 1990: Elazığ çevresinde buzağı ve kuzularda bulunan *Cryptosporidium*'un yaygınlığı üzerinde araştırmalar. *Turk J Vet Anim Sci*, 14, 439-445.
- Sezer S, Akgül G, 2022: Rapid etiological diagnosis of neonatal calf diarrhea with immunochromatographic test kits in Esme district of Uşak. *Assiut Vet Med J*, 68 (173), 10-15.
- Smith BP, 2015: In: Large Animal Internal Medicine, 221-339. Elsevier Press, Missouri, USA.
- Uhde FL, Kaufmann T, Sager H, Albini S, Zanoni R, Schelling E, Meylan M, 2008: Prevalence of four enteropathogens in the faeces of young diarrhoeic dairy calves in Switzerland. *Vet Rec*, 163, 362-366.
- Yıldız R, Beslek M, Beydilli Y, Özçelik MM, Biçici, Ö., 2018: Evaluation of platelet activating factor in neonatal calves with sepsis. *Vet Hekim Der Derg*, 89, 66-73.



The effect of Hydroxytyrosol on Spexin immunoreactivity in pancreatic islets and serum insulin levels in a Streptozotocin-induced experimental diabetes model in rats

Tuba YALÇIN^{1,a,*}, Sercan KAYA^{1,b}

¹Batman University, Vocational School of Healthcare Studies, Batman, Türkiye.

^aORCID: ^aORCID: 0000-0002-2359-9832;

^bORCID: 0000-0001-9014-2448

Received: 26.12.2023

Accepted: 26.04.2024

How to cite this article: Yalçın T, Kaya S. (2024). The effect of Hydroxytyrosol on Spexin immunoreactivity in pancreatic islets and serum insulin levels in a Streptozotocin-induced experimental diabetes model in rats. Harran Üniversitesi Veteriner Fakültesi Dergisi, 13(1): 28-33. DOI:10.31196/huvfd.1410288.

***Correspondence:** Tuba YALÇIN

Batman University, Vocational School of Healthcare Studies, Batman, Türkiye.

e-mail: tuba.yalcin@batman.edu.tr

Available on-line at: <https://dergipark.org.tr/tr/pub/huvfd>

Abstract: Diabetes (DM), a major health problem worldwide, is associated with the loss of β cells in the pancreatic islets and decreased insulin secretion. Hydroxytyrosol (HxT) is a phenol found in high concentrations in olive oil. Spexin (SPX) plays a role in regulating many metabolisms such as glucose and energy. This study aimed to determine the effects of HxT on circulating insulin levels, histopathological changes in pancreatic islets, and SPX immunoreactivity in a Streptozotocin-induced experimental diabetes model (eDM) in rats.

The 32 male rats used in the study were randomly divided into 4 groups (n: 8): Control, eDM, eDM+HxT, and HxT. After completing all applications in the experiment, the blood and pancreas tissues of the sacrificed rats were taken. Insulin levels were determined from the serum samples obtained. Histopathological changes and SPX immunoreactivities were evaluated in pancreatic tissues.

While serum insulin levels decreased in eDM, histopathological changes in pancreatic islets increased. Additionally, SPX immunoreactivity in pancreatic islets was significantly reduced in eDM. On the other hand, HxT supplementation (eDM+HxT group) regulated eDM-related adverse effects. While HxT supplementation may have a curative and therapeutic effect in DM, it was concluded that SPX may be effective in regulating the endocrine functions of the pancreas.

Keywords: Diabetes, Hydroxytyrosol, Pancreas, Spexin, Streptozotocin.

Sıçanlarda Streptozotocin ile İndüklenen Deneysel Diyabet Modelinde Hidroksitirozol'ün Pankreas Adacıklarında Speksin İmmünoreaktivitesi ve Serum İnsülin Düzeyleri Üzerine Etkisi

Özet: Dünya çapında önemli bir sağlık sorunu olan diyabet (DM), pankreas adacıklarındaki β hücrelerinin kaybı ve insülin sekresyonunun azalmasıyla ilişkilidir. Hidroksitirozol (HxT), zeytinyağında yüksek konsantrasyonda bulunan bir fenoldür. Spexin (SPX), glikoz ve enerji gibi birçok metabolizmanın düzenlenmesinde rol oynar. Bu çalışma, sıçanlarda Streptozotocin ile indüklenen deneysel diyabet modelinde (eDM) HxT'nin dolaşımdaki insülin düzeyleri, pankreas adacıklarındaki histopatolojik değişiklikler ve SPX immünoreaktivitesi üzerindeki etkilerini belirlemeyi amaçladı.

Çalışmada kullanılan 32 adet erkek sıçan, Kontrol, eDM, eDM+HxT ve HxT olmak üzere rastgele 4 gruba (n:8) ayrıldı. Deneyde tüm uygulamaların tamamlanmasıyla kurban edilen sıçanların, kan ve pankreas dokuları alındı. Elde edilen serum örneklerinden insülin düzeyleri tespit edildi. Pankreas dokularında ise histopatolojik değişiklikler ve SPX immünreaktivite değerleri değerlendirildi.

Serum insülin düzeyleri eDM'de azalırken pankreas adacıklarında histopatolojik değişikliklerin arttığı görüldü. Ayrıca eDM'de pankreas adacıklarında SPX immünreaktivitesi önemli ölçüde azaldığı tespit edildi. Buna karşın HxT takviyesinin (eDM+HxT grup), eDM'ye bağlı olumsuzlukları ortadan kaldırdığı görüldü.

DM'de HxT takviyesi iyileştirici ve tedavi edici etki gösterebilirken, SPX'in pankreasın endokrin fonksiyonlarını düzenlemede etkili olabileceği kanaatine varıldı.

Anahtar Kelimeler: Diyabet, Hidroksitirozol, Pankreas, Spexin, Streptozotocin.

Introduction

Over half a billion people globally have been diagnosed with diabetes (DM), a severe health issue whose prevalence is alarmingly high. Type 2 DM (T2DM), the most prevalent kind, is distinguished by persistent hyperglycemia. This is the primary pathological mechanism causing tissue damage and long-term complications (Binou et al., 2023). At the beginning of T1DM, there is a noticeable lack of β -cells. Similar circumstances are seen in the latter stages of T2DM (Lytrivi et al., 2020).

Among various nutritional models, the Mediterranean diet has been reported to positively affect DM and its complications (Estruch et al., 2018). Bioactive substances found in abundance in the Mediterranean diet include polyphenols, monounsaturated fatty acids, and olive oil (Vlavcheski et al., 2019). As a byproduct of the body's metabolism of oleuropein, hydroxytyrosol (HxT) is the phenol present in olive oil at the highest concentration (Vlavcheski et al., 2019). Research indicates that HxT influences lipid and glucose homeostasis, has antioxidant qualities, and may be protective against DM (Alkhatib et al., 2018; Wani et al., 2018).

SPX is a recently identified peptide hormone (Yalcin et al., 2024). Along with promoting glucose and lipid metabolism, SPX has various pleiotropic metabolic effects, such as modulating insulin secretion and energy homeostasis (Kaya et al., 2023). It has been proposed that only mammalian metabolically active organs and tissues, such as the pancreas, liver, stomach, and adipose tissue, secrete SPX (Lv et al., 2019). Furthermore, it is known that hormones like insulin, glucagon, estradiol, and adrenocorticotrophic can alter the secretion of SPX in rodents (Wang et al., 2020). Notably, prior research has shown that SPX and insulin co-localize in the secretory vesicles of pancreatic β cells (Gallagher et al., 2024; Gowdu and Dayanand, 2021). This suggests that there is a connection between SPX and insulin and that they may interact (Kaya, 2023a).

This study aimed to examine the effects of HxT on histopathological and SPX immunoreactivity in pancreatic islets and to determine circulating insulin levels in a streptozotocin (STZ)-induced experimental diabetes model (eDM) in rats.

Material and Method

Design of Experiments: This study was carried out with the approval of the Firat University Experimental Animals Local Ethics Committee, with its decision dated 13.11.2023 and numbered 19739. The experimental design and applications of the study were carried out within the scope of ARRIVE guidelines. The 32 Sprague-Dawley rats (male, 200-230 g, 8-10 weeks old) used in the study were kept under optimal conditions (22-25 °C temperature, 12-hour light cycle, ad-libitum water, and pellet feed). With eight rats per group, the rats were split into four groups at random. No app was made to the control group (n:8) during the experiment. To the eDM group (n: 8), a single dose of 50 mg/kg STZ (dissolved in phosphate-citrate buffer (pH4.5),

Sigma Chemical) was administered intraperitoneally to create experimental DM. 72 hours after STZ administration, blood samples (tail vein) were taken from fasted rats for 12 hours, and blood glucose levels were measured. eDM was diagnosed in rats with fasting blood glucose levels over 250 mg/dL. To the eDM+HxT group (n:8), 5 mg/kg/day HxT (Sigma Chemical) was administered via an orogastric tube for six weeks after experimental DM was created with STZ. To the HxT group (n: 8), 5 mg/kg/day HxT was administered via an orogastric tube during the 6-week experiment. The STZ and HxT doses and applications used in the experimental design were determined, taking into account previous studies (Rodriguez-Pérez et al., 2022; Rodriguez-Pérez et al., 2023). After all applications were completed in the trial, the rats were sacrificed by decapitation method under anesthesia (xylazine 10 mg/kg + ketamine 75 mg/kg intraperitoneally), and blood and pancreatic tissues were received.

Histopathological and Immunohistochemical evaluations: Pancreatic tissues taken at the end of the experiment were fixed in 10% formalin solution and subjected to a histological follow-up series. Pancreatic tissue sections were stained using Hematoxylin Eosin (HE) for histopathological analyses. The degeneration of pancreatic islets was taken into account during the histopathological evaluation of pancreatic tissues. Histopathological histoscorography was created by evaluating 10 separate, non-overlapping areas at X20 magnification from 2 HE-stained pancreatic tissue sections prepared for each rat. In the histopathological evaluation of pancreatic tissue, a 3-grade scoring system was used according to the presence of degeneration of pancreatic islets (none; 0, mild; 1, moderate; 2 and severe; 3) (Lee et al., 2016; Uyar and Abdulrahman, 2020). The avidin-biotin-peroxidase complex method (Kaya, 2023b) was used to determine SPX (1:200, Boster Bio-Tech, A04088-1, USA) immunoreactivity in pancreatic tissues. Counterstaining was performed with Mayer Hematoxylin. SPX immunoreactivities in pancreatic tissue were calculated with 3-grade scoring (none; 0, mild; 1, moderate; 2 and severe; 3) (Lee et al., 2016; Uyar and Abdulrahman, 2020). Histopathological and immunoreactivity evaluations of all prepared preparations were made under a light microscope and microphotographs were taken (Leica, DM 2500, Germany).

Biochemical analysis: Blood samples taken after the experiment were centrifuged, and serum was taken. The enzyme-linked immunosorbent assay (ELISA) was used to measure Insulin levels using blood serum samples. Insulin (ER1113, FineTest, Wuhan, China) ELISA kit purchased from the commercial company was studied considering the manufacturer's instructions. The sensitivity of the insulin ELISA kit was 46.875 pg/ml and the test range was 78.125-5000 pg/ml. Additionally, an automatic biochemical analyzer (ADVIA-2400, Siemens) was used to measure the amount of glucose in blood serum.

Statistical analysis: The study data was analyzed using the SPSS 22.0 package program. Data showing homogeneous

distribution according to the Shapiro-Wilk test were statistically analyzed using Oneway ANOVA posthoc TUKEY tests. For a p-value <0.05, statistical significance was considered. The statistical analysis results of the study data were presented in graphs created using Graph Pad Prism 9.3 software.

Results

Effect of eDM and/or HxT on histopathological and SPX immunoreactivity in pancreatic tissue: Pancreatic tissue and islets were observed to have typical histological structures in

the control and HxT groups. Atrophic degenerate islets were found to be more common in the pancreatic islets in the eDM group compared to the control group (P<0.05). In the eDM+HxT group, HxT administration significantly reduced the degenerated pancreatic islets observed in the eDM model compared to the eDM group (P<0.05) (Figure 1).

SPX immunoreactivities in pancreatic islets were at similar levels in the control and HxT groups (P>0.05). SPX immunoreactivity in pancreatic islets was decreased in the eDM group compared to the control group (P<0.05). On the other hand, SPX immunoreactivity in pancreatic islets augmented in the eDM+HxT group compared to the eDM group (P<0.05) (Figure 2).

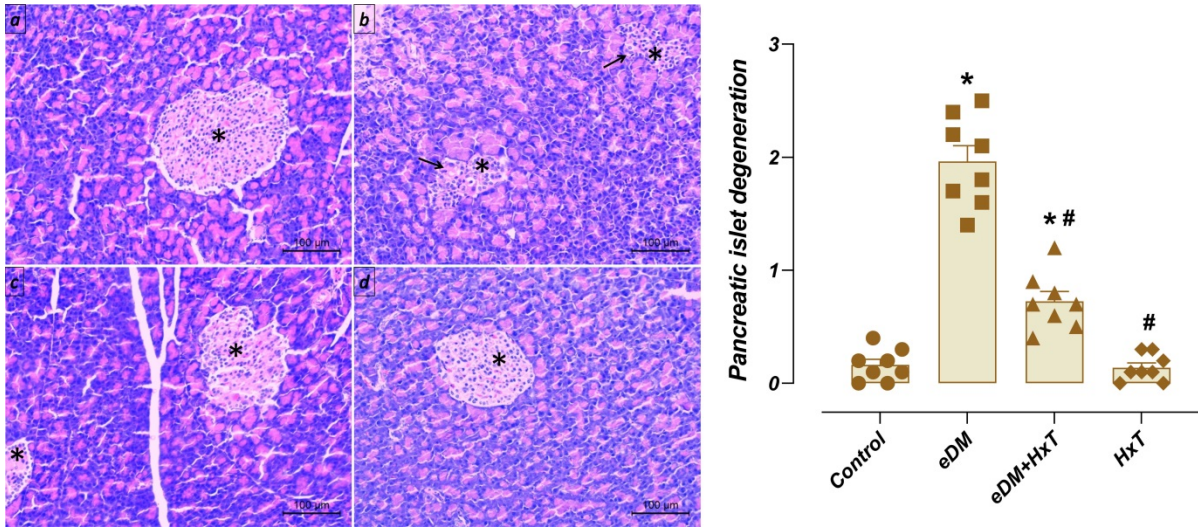


Figure 1. Microphotographs and histopathological histoscore graph of the histopathological effects of eDM and/or HxT on pancreatic islets. Control (a) and HxT (d) groups had normal histological pancreatic tissue. Widespread degeneration was observed in the pancreatic islets of the eDM (b) group compared to the control group (P<0.05). In the eDM+HxT (c) group, it was determined that the degeneration observed in the pancreatic islets was significantly reduced compared to the eDM group (P<0.05). Hematoxylin Eosin staining, scale bar; 100µm. Star; pancreatic islets, arrow; pancreatic islet degeneration. Histopathological histoscore graph: *, compared to control (P<0.05), #; Compared to eDM (P<0.05). eDM; experimental diabetes model, HxT; Hydroxytyrosol.

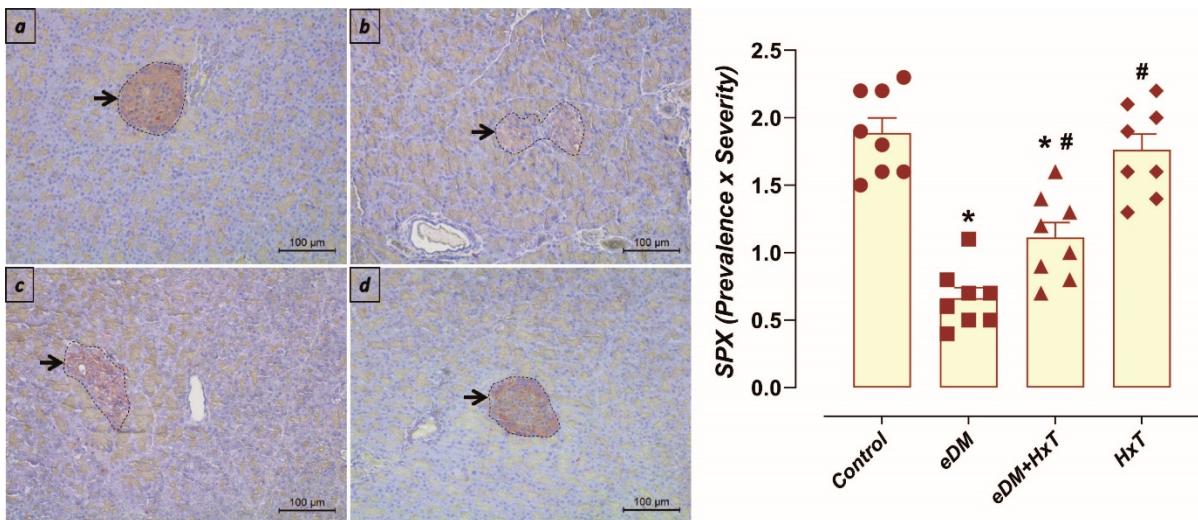


Figure 2. Microphotographs and immunoreactivity graph of the effects of eDM and/or HxT on pancreatic islets SPX immunoreactivity. SPX immunoreactivity was similar in pancreatic islets in the control (a) and HxT (d) groups. It was observed that SPX immunoreactivity decreased in the pancreatic islets of the eDM (b) group compared to the control group (p<0.05). In the eDM+HxT (c) group, it was determined that SPX immunoreactivity increased in the pancreatic islets compared to the eDM group (P<0.05). SPX immunohistochemical staining, scale bar; 100µm. Arrow; SPX immunoreactivity in pancreatic islets. Immunoreactivity graph: *, compared to control (P<0.05), #; compared to eDM (P<0.05). eDM; experimental diabetes model, HxT; Hydroxytyrosol, SPX; Spexin.

Effect of eDM and/or HxT on serum insulin and glucose levels: There was no difference between the insulin levels of the control and HxT groups in blood serum samples ($P>0.05$). It was detected that insulin levels in the eDM group were reduced compared to the control group ($P<0.05$). Insulin levels were found to be increased in the eDM+HxT group compared to the eDM group ($P<0.05$) (Figure 3).

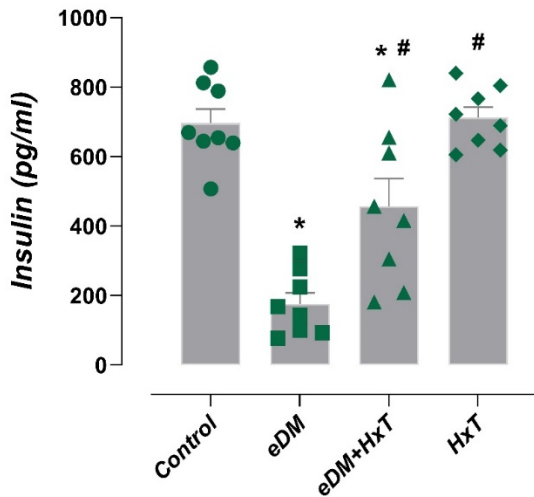


Figure 3. Effects of eDM and/or HxT on serum insulin levels. Serum insulin levels were similar in the control and HxT groups. It was determined that serum insulin levels decreased in the eDM group compared to the control group ($P<0.05$). Serum insulin levels increased in the eDM+HxT group compared to the eDM group ($P<0.05$). *, compared to control ($P<0.05$), #, compared to eDM ($P<0.05$). eDM; experimental diabetes model, HxT; Hydroxytyrosol.

Blood glucose levels were similar between the control and HT groups ($P>0.05$). When the eDM group was compared with the eDM+HxT group, glucose levels were observed to increase ($P<0.05$). It was determined that glucose levels decreased in the eDM+HxT group compared to the DM group ($P<0.05$) (Figure 4).

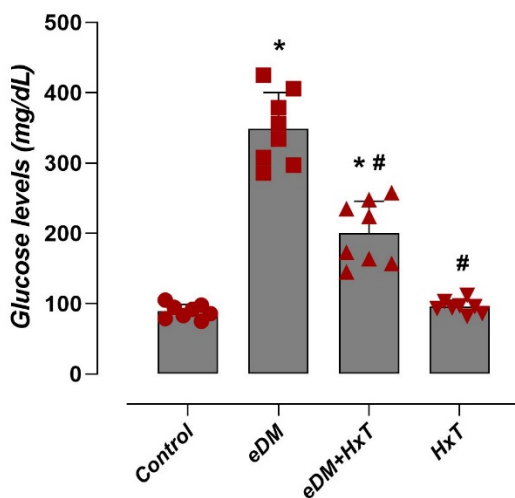


Figure 4. Effects of eDM and/or HxT on serum glucose levels. Serum glucose levels were similar in the control and HxT groups. It was determined that serum glucose levels increased in the eDM group compared to the control group ($P<0.05$). Serum glucose levels were found to decrease in the eDM+HxT group compared to the eDM group ($P<0.05$). *, compared to control ($P<0.05$), #, compared to eDM ($P<0.05$). eDM; experimental diabetes model, HxT; Hydroxytyrosol.

Discussion and Conclusion

This study investigated the effects of HxT in eDM on circulating insulin levels, SPX immunoreactivity, and histopathological changes in pancreatic islets. HxT administration to eDM rats increased SPX immunoreactivity while reducing histopathological changes compared to the eDM group. Additionally, HxT administration to rats with eDM increased circulating insulin levels in parallel with this increase in SPX immunoreactivity in pancreatic islets compared to the eDM group.

One study found that oral administration of 5, 50, and 500 mg/kg/day HxT to rats for 13 weeks had no negative effects on micro/macro-organ changes, morbidity, or mortality (Auñon-Calles et al., 2013). HxT is crucial in preventing DM (Bertelli et al., 2020). This study determined that pancreatic islets underwent STZ-induced atrophic degeneration and largely lost their cellular structure. However, HxT supplementation in eDM significantly reduced atrophy/degeneration in pancreatic islets. Consistent with these results, it has been reported that HxT supplementation has a protective effect on pancreatic tissue and prevents the damage of β cells (Xie et al., 2018). It has also been reported that HxT stimulates the proliferation of pancreatic β cells (Marrano et al., 2021).

In the development of DM, controlling blood glucose levels not only regulates disease-altered metabolic profiles but also reduces the incidence of complications (Rodríguez-Pérez et al., 2022). The high blood glucose levels observed in eDM in rats may result from insulin deficiency due to STZ-induced depletion of pancreatic β cells or an increased rate of gluconeogenesis and glycogenolysis (Sukanya et al., 2020). Similarly, current study observed that insulin levels decreased and glucose levels increased in the eDM group. These results were consistent with studies reporting that blood glucose levels increased in an eDM model induced by STZ injection in rats (Soylu and Karacor, 2023; Jafari-Rastegar et al., 2023). However, it has been reported that tyrosol, which is also found in olive oil, increases insulin secretion from remaining pancreatic β cells in rats with STZ-induced eDM, which may increase glucose utilization in peripheral tissues (Chandramohan et al., 2017; Jafari-Rastegar et al., 2023). Similarly, this study determined that insulin levels increased and glucose levels decreased in the eDM+HxT group compared to the eDM group.

Insulin biosynthesis and secretion are inhibited by STZ-induced NAD⁺ depletion in β cells (Lenzen, 2008). Additionally, STZ causes cytotoxicity and death in β cells (Soylu and Karacor, 2023). Similarly, this study detected that circulating insulin levels were reduced in the STZ-induced eDM and eDM+HxT groups compared to the control group. However, it has been reported that HxT plays an important role in insulin signaling (Wang et al., 2018). When HxT was applied to rat pancreatic tissue, the decrease in insulin secretion caused by hyperglycemia was suppressed. This suggests that HxT can increase pancreatic insulin secretion in hyperglycemic states (Hamden et al., 2009). It has been demonstrated that in β cells (rat INS-1E), HxT promotes proliferation and raises the amount of insulin protein

(Marrano et al., 2021). Consistent with these results, it was determined in this study that HxT significantly increased insulin levels, which decreased eDM. Similarly, a recent study showed that HxT increased STZ-induced decreased insulin expression (Soylu and Karacor, 2023). An another study has shown that insulin and SPX immunopositive cell numbers are significantly reduced after the onset of DM (Adeghate et al., 2022). Similarly, in this study, SPX immunoreactivity was reduced in eDM pancreatic islets. Another immunohistochemistry analysis reported that SPX has the same localization as insulin in the pancreas and that islet β cells can produce SPX (Sassek et al., 2019). Therefore, it is conceivable that circulating SPX levels are closely related to SPX expression in islet β cells. In this context, studies conducted on patients with DM have reported that there is a decrease in serum SPX levels (Dai et al., 2023; Gu et al., 2022). A study reported that the decrease in serum SPX levels due to DM may be due to the decrease in β cell mass (Dai et al., 2023). In this study, histopathological evaluation results revealed that pancreatic islets degenerate with DM, and therefore SPX immunoreactivity decreases. However, HxT treatment not only increased serum insulin levels, which decreased due to DM, but also had a regulatory effect on histopathological changes in pancreatic islets and SPX immunoreactivity.

In conclusion, STZ-induced eDM in rats increased histopathological changes in pancreatic islets and also reduced SPX immunoreactivity. Additionally, serum insulin levels were observed to decrease and glucose levels to increase in eDM. On the other hand, it has been determined that HxT supplementation regulates eDM-induced changes. These results are essential for the development of new strategies to prevent and/or treat DM, which continues to be a global health problem. Additionally, it has been suggested that SPX plays a role in the regulation of endocrine pancreatic functions.

Similarity ratio

We declare that the similarity rate of the article is 14% as stated in the report uploaded to the system.

Conflict of Interest

The authors did not report any conflict of interest or financial support.

Funding

This research received support within the scope of Batman University Scientific Research Projects (BTÜBAP-2023-SHMYO-02).

Ethical Approval

This study was conducted with the approval of the Firat University Animal Experiments Ethics Committee dated 13/11/2023-19739.

Author Contributions

Motivation / Concept: TY, SK
 Design: TY
 Control/Supervision: SK
 Data Collection and/or Processing: TY, SK
 Analysis and/or Interpretation: SK, TY
 Literature Review: TY
 Writing the Article: TY, SK
 Critical Review: SK, TY

References

- Adeghate E, D'Souza C, Ali II, Saeed Z, Alharthi SH, Alhadhrami ZK, & Tariq S, 2022: Spexin co-localizes with insulin in pancreatic islet cells of normal and diabetic rats. *The FASEB J*, 36 (1).
- Alkhatib A, Tsang C, Tuomilehto J, 2018: Olive oil nutraceuticals in the prevention and management of diabetes: From molecules to lifestyle. *Int J Mol Sci*, 19 (7), 2-15.
- Auñon-Calles D, Canut L, Visioli F, 2013: Toxicological evaluation of pure hydroxytyrosol. *Food Chem Toxicol*, 55, 498-504.
- Bertelli M, Kiani AK, Paolacci S, Manara E, Kurti D, Dhuli K, Michelini S, 2020: Hydroxytyrosol: A natural compound with promising pharmacological activities. *J Biotechnol*, 10 (309), 29-33.
- Binou P, Stergiou A, Kosta O, Tentolouris N, Karathanos VT, 2023: Positive contribution of hydroxytyrosol-enriched wheat bread to HbA1c levels, lipid profile, markers of inflammation, and body weight in subjects with overweight/obesity and type 2 diabetes mellitus. *Eur J Nutr*, 62 (5), 2165-2176.
- Chandramohan R, Saravanan S, Pari L, 2017: Beneficial effects of tyrosol on altered glycoprotein components in streptozotocin-induced diabetic rats. *Pharm Biol*, 55 (1), 1631-7.
- Dai J, Ni Y, Wu D, Jiang Y, Jin S, Zhang S, Liu R, 2023: Circulating spexin levels are influenced by the glycemic status and correlated with pancreatic β -cell function in Chinese subjects. *Acta Diabetol*, 60 (2), 305-313.
- Estruch R, Ros E, Salas-Salvadó J, Covas MI, Corella D, Arós F, Martínez-González MA, 2018: Primary prevention of cardiovascular disease with a Mediterranean diet supplemented with extra-virgin olive oil or nuts. *N Engl J Med*, 21, 378 (25), e34.
- Gallagher DM, O'Harte FP, Irwin N, 2024: An update on galanin and spexin and their potential for the treatment of type 2 diabetes and related metabolic disorders. *Peptides*, 171, 171096.
- Gowdu T, Dayanand CD, 2021: Spexin in metabolic syndrome-an overview. *SAS J Med*, 7, 15-25.
- Gu L, Yan S, Huang Y, Yang J, Peng Y, Wang Y, 2022: Serum spexin differed in newly diagnosed type 2 diabetes patients according to body mass index and increased with the improvement of metabolic status. *Front Endocrinol (Lausanne)*, 13, 1086497.
- Hamden K, Allouche N, Damak M, and Elfeki A, 2009: Hypoglycemic and antioxidant effects of phenolic extracts and purified hydroxytyrosol from olive mill waste in vitro and rats. *Chem Biol Interact*, 14, 180 (3), 421-32.
- Jafari-Rastegar N, Hosseininia HS, Jalilvand E, Naseroleslami M, Khakpai F, Mousavi-Niri N, 2023: Oral administration of nano-tyrosol reversed the diabetes-induced liver damage in streptozotocin-induced diabetic rats. *J Diabetes Metab Disord*, 22 (1), 297-305.
- Kaya S, 2023a: Speksin'in metabolizmayı düzenlemedeki potansiyel rolü. International Congress on Health Sciences and Technologies Research Anatolia, Ankara, Turkey, 6-8.

- Kaya S, 2023b: The effect of n-acetylcysteine administration on trpm2 ion channels in aluminum chloride-induced cardiotoxic rat model. *FÜ Sağ Bil Tip Derg*, 37 (2), 105 – 112.
- Kaya S, Yalçın T, Boydak M, Dönmez HH, 2023: Protective effect of N-acetylcysteine against aluminum-induced kidney tissue damage in rats. *Biol Trace Elem Res*, 201 (4), 1806-1815.
- Lee H, Im SW, Jung CH, Jang YJ, Ha TY, Ahn J, 2016: Tyrosol, an olive oil polyphenol, inhibits ER stress-induced apoptosis in pancreatic β -cell through JNK signaling. *Biochem Biophys Res Commun*, 469 (3), 748-752.
- Lenzen S, 2008: The mechanisms of alloxan-and streptozotocin-induced diabetes. *Diabetologia*, 51 (2), 216-26.
- Lv SY, Zhou YC, Zhang XM, Chen WD, Wang YD, 2019: Emerging roles of NPQ/spexin in physiology and pathology. *Front Pharmacol*, 10, 457.
- Lytrivi M, Castell AL, Poitout V, Cnop M, 2020: Recent insights into mechanisms of β -cell lipo- and glucolipotoxicity in type 2 diabetes. *J Mol Biol*, 6, 432 (5), 1514-1534.
- Marrano N, Spagnuolo R, Biondi G, Cignarelli A, Perrini S, Vincenti L, Natalicchio A, 2021: Effects of extra virgin olive oil polyphenols on beta-cell function and survival. *Plants (Basel)*, 3, 10 (2), 286.
- Rodríguez-Pérez MD, Pérez de Algaba I, Martín-Aurioles E, Arrebola MM, Ortega-Hombrados L, Verdugo C., González-Correa JA, 2022: Neuroprotective Effect of 3', 4'-Dihydroxyphenylglycol in Type-1-like Diabetic Rats—Influence of the Hydroxytyrosol/3', 4'-dihydroxyphenylglycol Ratio. *Nutrients*, 14 (6), 1146.
- Rodríguez-Pérez MD, Santiago-Corral L, Ortega-Hombrados L, Verdugo C, Arrebola MM, Martín-Aurioles E, González-Correa JA, 2023: The Effect of the Extra Virgin Olive Oil Minor Phenolic Compound 3', 4'-Dihydroxyphenylglycol in Experimental Diabetic Kidney Disease. *Nutrients*, 15 (2), 377.
- Sassek M, Kolodziejewski PA, Szczepankiewicz D, and Pruszyńska-Oszmalek E, 2019: Spexin in the physiology of pancreatic islets—mutual interactions with insulin. *Endocrine*, 63, 513-519.
- Soylu H, Karacor K, 2023: The effects of hydroxytyrosol on Prdx6 and insulin expression in diabetic rat pancreases. *Histochem Cell Biol*, 160 (2), 127-134.
- Sukanya V, Pandiyan V, Vijayarani K, Padmanath K, 2020: A study on insulin levels and the expression of glut 4 in streptozotocin (STZ) induced diabetic rats treated with mustard oil diet. *Indian J Clin Biochem*, 35, 488–496.
- Uyar A, Abdulrahman NT, 2020: A histopathological, immunohistochemical and biochemical investigation of the antidiabetic effects of the Pistacia terebinthus in diabetic rats. *Biotech Histochem*, 95 (2), 92-104.
- Vlavcheski F, Young M, Tsiani E, 2019: Antidiabetic effects of hydroxytyrosol: In vitro and in vivo evidence. *Antioxidants*, 8 (6), 188.
- Wang L, Tran A, Lee J, Belsham DD, 2020: Palmitate differentially regulates Spexin, and its receptors Galr2 and Galr3, in GnRH neurons through mechanisms involving PKC, MAPKs, and TLR4. *Mol Cell Endocrinol*, 518, 110991.
- Wang N, Liu Y, Ma Y, Wen D, 2018: Hydroxytyrosol ameliorates insulin resistance by modulating endoplasmic reticulum stress and prevents hepatic steatosis in diet-induced obesity mice. *J Nutr Biochem*, 57, 180-188.
- Wani TA, Masoodi FA, Gani A, Baba WN, Rahmanian N, Akhter R, Ahmad M, 2018: Olive oil and its principal bioactive compound: Hydroxytyrosol—A review of the recent literature. *Trends Food Sci Technol*, 77, 77-90.
- Xie YD, Chen ZZ, Shao LH, Wang QT, Li N, Lu WF, Bian XL, 2018: A new multifunctional hydroxytyrosol-clofibrate with hypolipidemic, antioxidant, and hepatoprotective effects. *Bioorg Med Chem Lett*, 1, 28 (18), 3119-3122.
- Yalçın T, Kuloglu T, Kaya Tektemur N, Tektemur A, Ozan İE, 2024: Effects of N-acetylcysteine on spexin immunoreactivity in kidney tissues of rats treated with adriamycin. *Iran J Basic Med Sci*, 27, 233-240.



A Bibliometric Analysis of Thromboelastography in Veterinary Clinical Use

Oya ERALP INAN^{1.a,*}

¹Eskisehir Osmangazi University, Faculty of Agriculture,
department of Animal Science, Eskisehir, TURKIYE

^aORCID: 0000-0002-4242-8609

Received: 12.01.2024

Accepted: 02.04.2024

How to cite this article: Eralp Inan O. (2024). A
Bibliometric Analysis of Thromboelastography in
Veterinary Clinical Use. Harran Üniversitesi Veteriner
Fakültesi Dergisi, 13(1): 34-41.
DOI:10.31196/huvfd.1418588.

***Correspondence:** Oya ERALP INAN

Eskisehir Osmangazi University, Faculty of Agriculture,
department of Animal Science, Eskisehir, Turkey.

e-mail: oeralp@ogu.edu.tr

Available on-line at: <https://dergipark.org.tr/tr/pub/huvfd>

Abstract: The evaluation of coagulation with thromboelastography (TEG) has been of high interest for the last two decades in veterinary medicine. The main cause is the ability to detect hypo-, normo- and hypercoagulative states in a single TEG analysis. In clinical veterinary medicine, the importance of coagulation in terms of course and outcome in many diseases had been realized through research over time. TEG studies had gained importance as traditional coagulation tests were inadequate, especially in cases complicated with hypercoagulation. The bibliometric analysis determined topics, researchers and countries of studies in veterinary clinical use of TEG. According to the Web of Science database, a total of 371 documents in this research field were identified between 1998 and 2023. In 2012, with 39 articles, the highest number of studies were published. The most relevant author was Kristensen A.T. with 39 articles. In the list of corresponding authors' countries, the first country with 189 authors was determined as the USA. Trend topics and their distribution over time have shown that dogs were the most studied animal species in this field. A high number of studies on the topic hypercoagulability and immune-mediated hemolytic anemia were detected, but in the last 3 years new topics like antithrombotics and rational use were involved. The bibliometric analysis carried out showed the changes over time and the currentness of the subject. The results of the present study could be used in planning future studies in the field of veterinary clinical use of TEG.

Keywords: Bibliometrics, Clinic, Thromboelastography, Veterinary.

Veteriner Klinik Kullanımında Tromboelastografinin Bibliyometrik Analizi

Özet: Tromboelastografi (TEG) ile pıhtılaşmanın değerlendirilmesi, son yirmi yıl içerisinde veteriner hekimlikte büyük ilgi görmüştür. Bu ilginin temel nedeni, tek bir TEG analizinde hipo-, normo- ve hiperkoagülatif durumları tespit edebilmesidir. Klinik veteriner hekimliği açısından, birçok hastalığın seyri ve sonucu üzerinde pıhtılaşmanın önemi, zamanla yapılan araştırmalarla fark edilmiştir. Özellikle hiperkoagülasyonla komplike olan durumlarda, geleneksel pıhtılaşma testlerinin yetersiz olduğu durumlarda, TEG çalışmaları önem kazanmıştır. Bibliyometrik analiz, TEG'nin veteriner hekimliği klinik kullanımı alanındaki konuları, araştırmacıları ve ülkeler hakkında bilgi vermiştir. Web of Science veritabanına göre, 1998 ile 2023 arasında bu araştırma alanında toplam 371 belge tanımlanmıştır. İki bin on iki yılında, 39 makale ile en yüksek sayıda çalışma yayımlanmıştır. Yazarlardan Kristensen A.T. 39 makale ile bu alanda en yüksek sayıda araştırmayla karşımıza çıkmıştır. Sorumlu yazarların ülkeleri sıralamasında 189 yazar ile birinci sırada yer alan ülke ABD olarak belirlenmiştir. Öne çıkan konular ve bunların zaman içindeki dağılımları, köpeklerin bu alandaki en çok çalışılan hayvan türü olduğunu göstermiştir. Hiperkoagülabilité ve immün ilişkili hemolitik anemi konusunda çok sayıda çalışma saptanmasına rağmen, son 3 yılda antitrombotikler ve rasyonel kullanım gibi yeni konular da dahil edildiği tespit edilmiştir. Yapılan bibliyometrik analiz, bu alanda zaman içerisindeki değişiklikleri ve konunun güncelliğini göstermiştir. Bu çalışma, TEG'nin veteriner klinik kullanımına dair araştırmalarının gelişim ve değişiminin ve bu konuyla ilgili gelecekteki araştırmaları yönlendirmeye yardımcı olacak kapsamlı bir bibliyometrik analizini göstermektedir.

Anahtar Kelimeler: Bibliyometri, Klinik, Tromboelastografi, Veteriner.

Introduction

Thromboelastography (TEG) is a method developed in 1948 by Helmut Hartet (Hartet, 1948). Some modifications of the method occurred over years and its first use in animal experiments began in the 1960s (Wiinberg and Kristensen, 2010). It is reported that TEG analysis is superior to standard coagulation tests performed with plasma as it is performed with whole blood and thus includes all components that contribute to coagulation in the blood (Wiinberg and Kristensen, 2010). Based on the same technique two different machines are available TEG (Heamometrics, USA) and rotational thromboelastometry (ROTEM, Pentapharm GmbH, Germany). The ability of TEG to detect hypo- and hypercoagulable states has led to its use in clinical studies. Species-specific validation for the assessment of coagulation abnormalities with the TEG in experimental studies in human disease modelling in laboratory animals were performed in rats by Cam et al. (2015), Cruz et al. (2017), in mice by Kaur et al. (2019), Schroeder et al. (2021), in pigs by Strandberg et al. (2016), in rabbits by Studer et al. (2021) and in ovine by Johnson et al. (2018). In addition to these studies, interest in the clinical use of TEG in animals has increased over time (Wiinberg and Kristensen, 2010). Many TEG and/or ROTEM reference value studies have been published in horses by Honore et al. (2021), Scruggs et al. (2016), in cattle by Sommerey et al. (2014), in calves by Borreli et al. (2017), in dogs by Bauer et al. (2009), Pereira et al. (2020), in cats by Alwood et al. (2014), Doderlein and Mischke, (2015), Engelen et al. (2017) and pet rabbits by Bassan et al. (2023). Different clinical studies in dogs for the establishment of coagulation abnormalities via TEG were reported in immune-mediated hemolytic anemia by Fenty et al., (2011), Goggs et al. (2012), Sinnot et al. (2009), in different cancer types by Kristensen et al. (2008), in chronic enteropathy by Dixon et al. (2021), in dilated cardiomyopathy by Yilmaz et al. (2017), in monitoring transfusion by Langhorn et al. (2019), in hyperadrenocorticism by Kol et al. (2013), in critical illness by Han et al. (2022), Majoy et al. (2015) and assessment of DIC by Wiinberg et al. (2008). TEG evaluations in obese horses were studied by Lovett et al. (2022) and horses with gastrointestinal diseases by Mendez-Angulo et al. (2010). Coagulation abnormalities in cats with cholestatic liver disease were reported by Kakar et al. (2021) and factor-XII deficiency by Blois et al. (2015). A study in cats with hypertrophic cardiomyopathy and TEG evaluation of hemostatic status is still in progress (Wilkinson and Menciotti, Virginia Maryland, College of Veterinary Medicine, USA). At the same time, due to the cost of TEG analyzes, some clinical studies have sought an alternative assessment of coagulation by comparing TEG results with conventional coagulation tests (Corda et al., 2023; Rubanick et al., 2017). When the mentioned studies are assessed, it appears that TEG studies will remain popular due to the complexity of the coagulation mechanism and its interaction with diseases.

Bibliometric analysis is a statistical method that helps to reveal the relationship and impact mechanisms of the sociometric and networks of a scientific study (Kaplan and

Altay, 2023; Önder and Tirink, 2022). Thanks to this method, the bibliographies of scientific studies are evaluated, and detailed information is provided about the past and present situation, its changes over time, scientists and institutes working in the field under study, and their collaboration status (Ergin et al., 2023a). Bibliometric analysis is a statistical method that can be performed before carrying out a scientific study in the relevant field, allowing researchers to avoid wastage by providing researchers with features that need to be examined, time, labor and up-to-date information (Altay and Kaplan, 2023).

In this context, the bibliometric analysis of veterinary clinical use of TEG aims to determine how this field of study has developed over time and to determine which areas within this field are open to research and will be beneficial. The results of this analysis will identify researchers, institutions and countries with which collaboration would be appropriate. In this way the present study could be a resource, summarizing information for planning a TEG study in clinical veterinary medicine.

Material and Methods

This study enrolled 371 documents between the years 1998 – 2023 (September) which were indexed in the Web of Science (WoS) database. The determination of studies specifically reported for veterinary clinical use and not for human medicine models in laboratory animals, for this, keywords and journals were carefully chosen.

For the statistical analysis the data set from the Web of Science (WoS) database was downloaded in a format suitable for statistical analysis, using the keywords "thromboelastography" and "veterinary" and year ranges (1980-2023). The prepared data set was edited with the help of the R software "bibliometrix" package and data analysis was performed (Aria and Cuccurullo, 2017). Tables and graphs were organized in a meaningful way to better understand the bibliometric features and were interpreted (Ergin et al., 2023b). Bibliometric analysis was materialized by the bibliometric properties of 371 documents. Ethics committee approval was not required for the present study.

Results

The results of primary data showed that the majority of 371 documents were 321 articles (plus 4 early access articles and 7 proceeding papers), followed by 23 meeting abstracts, 3 editorial materials, 1 letter, 1 correction and 1 early access correction.

Annual scientific production results show that the highest number of articles, 39 articles, were published in 2012 and the number of articles first increased above 10 in 2008. After 2012, according to the WoS database, the number of articles published in this field did not exceed 30. Whereas the average citations per year results showed that articles from the year 2000 got a maximum mean total

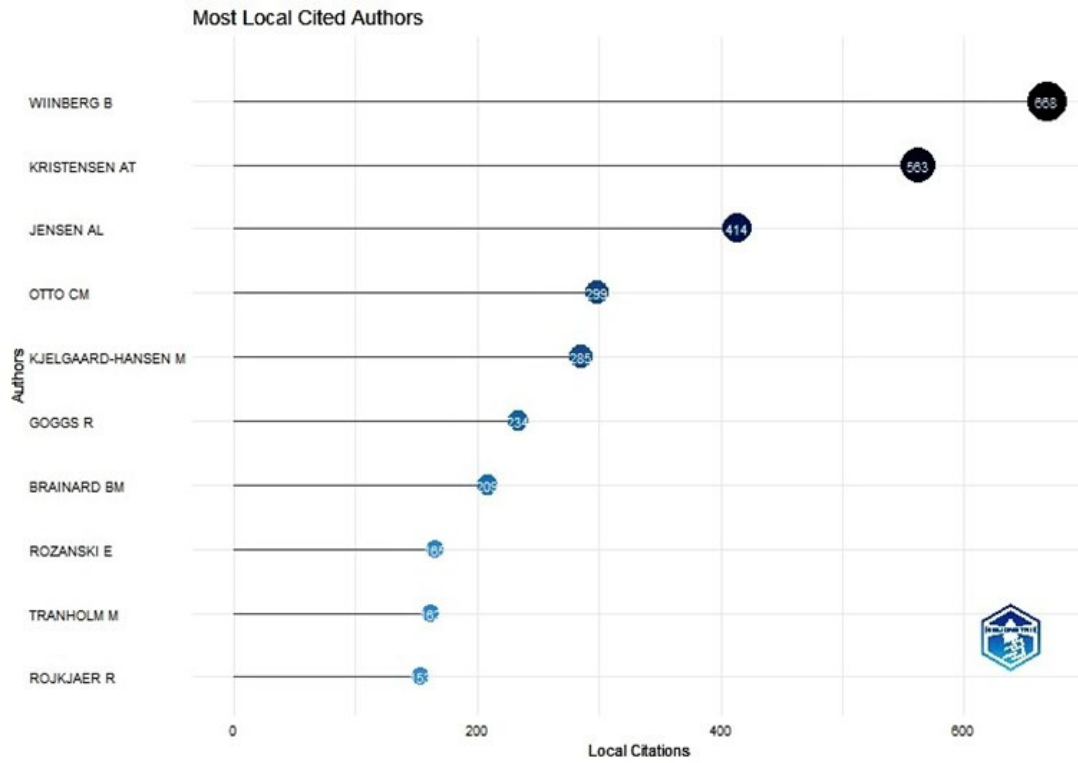


Figure 1. Most Local Cited Authors.

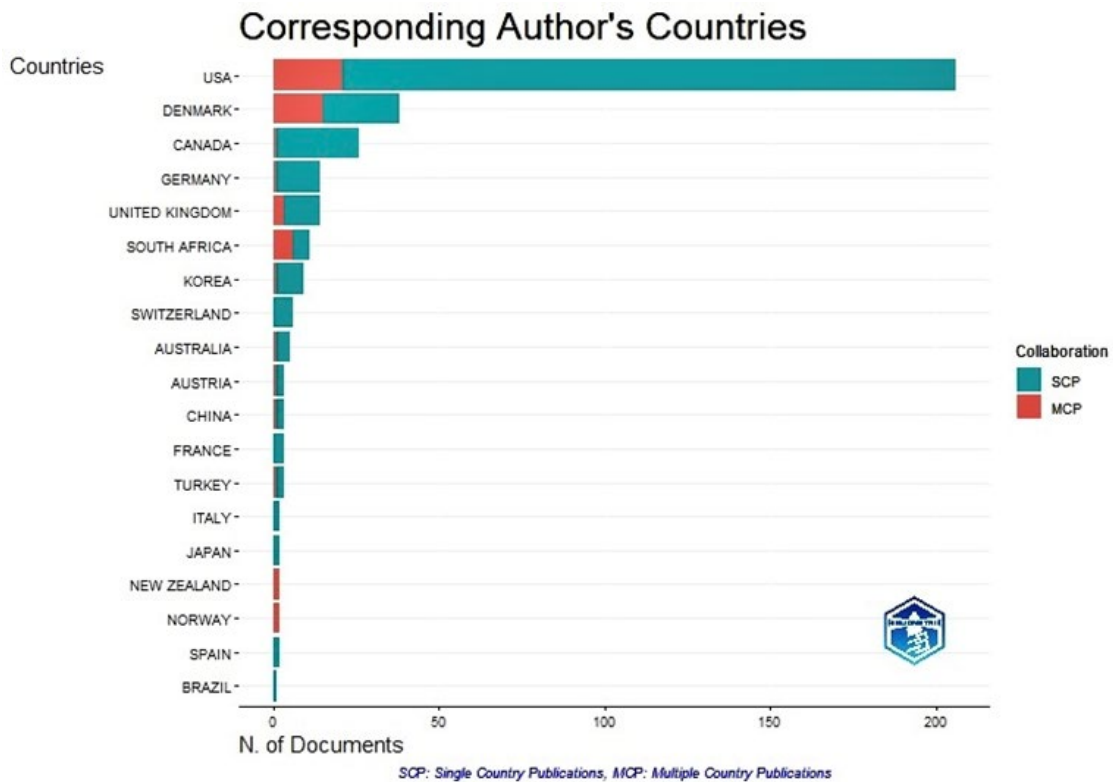


Figure 2. Corresponding Author's Countries.

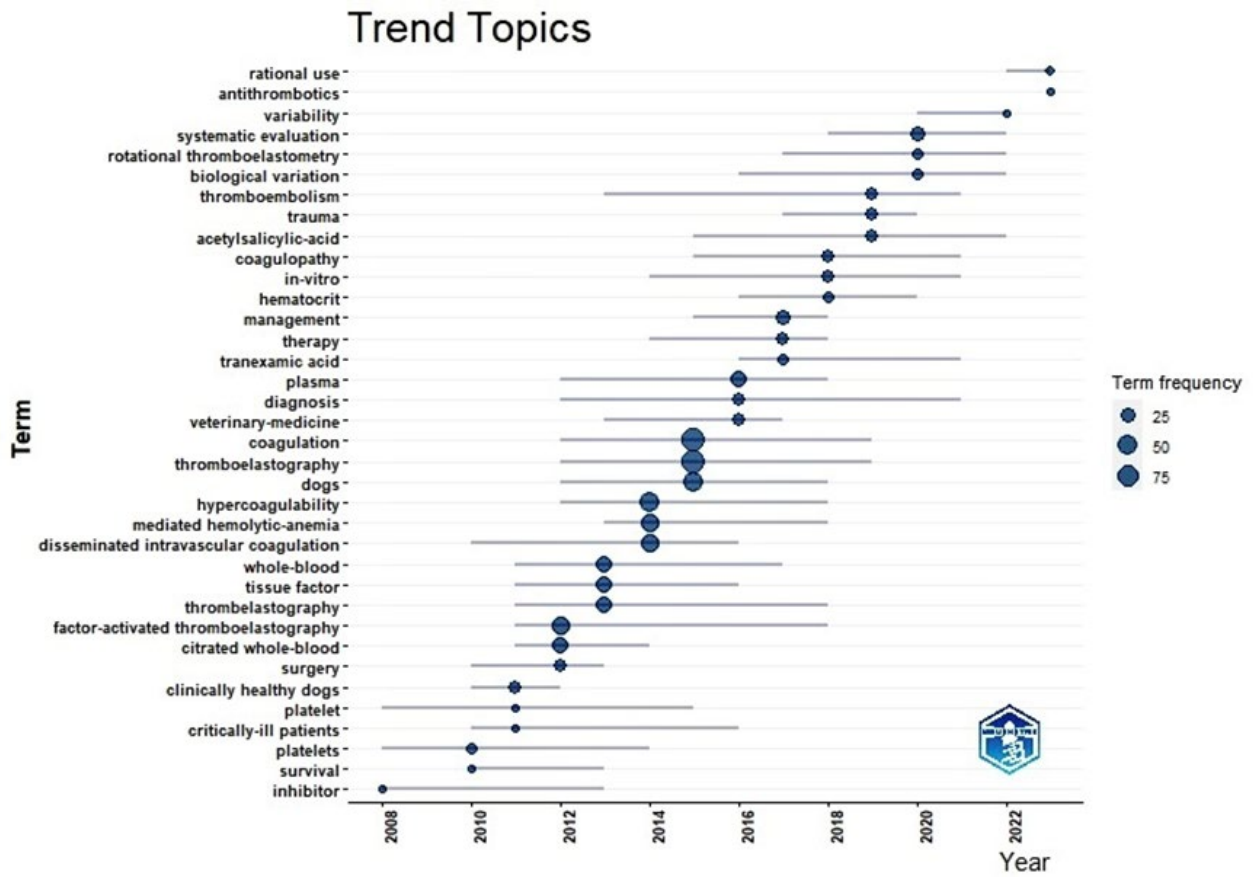


Figure 3. Mostly used keywords and their timespan.

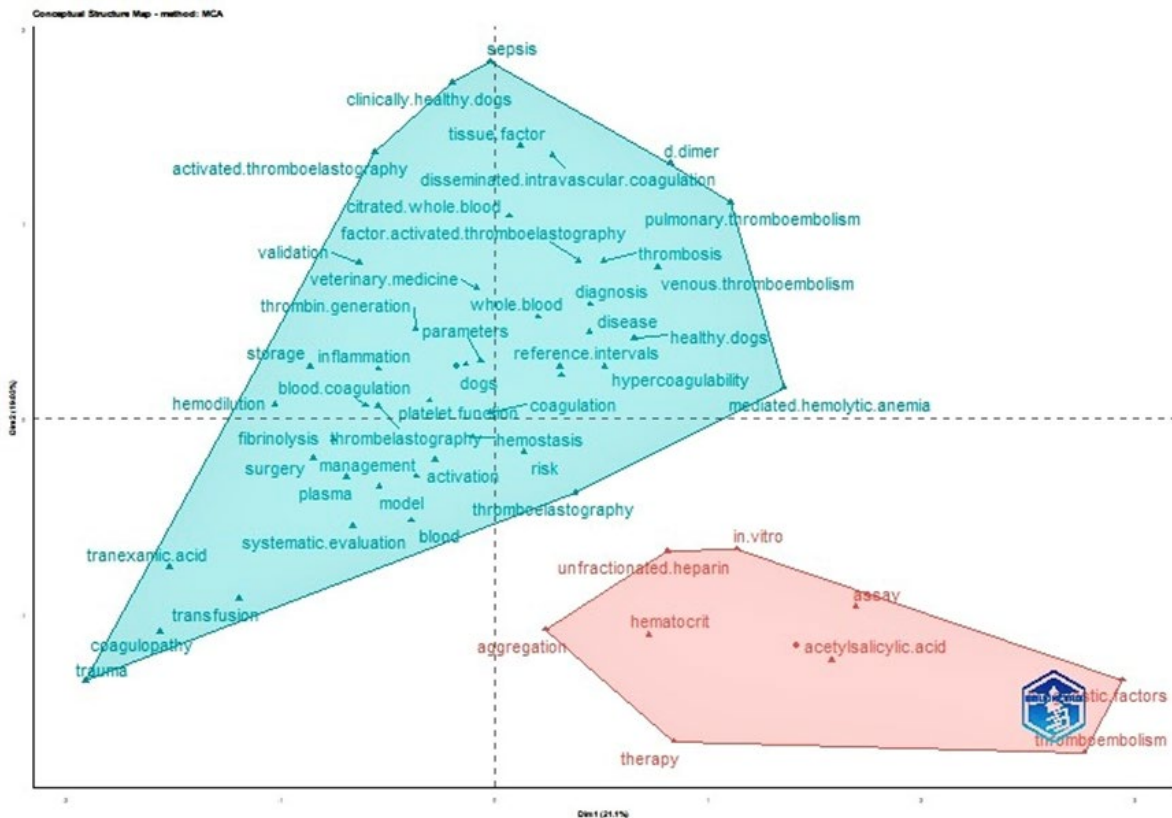


Figure 4. Conceptual structure map

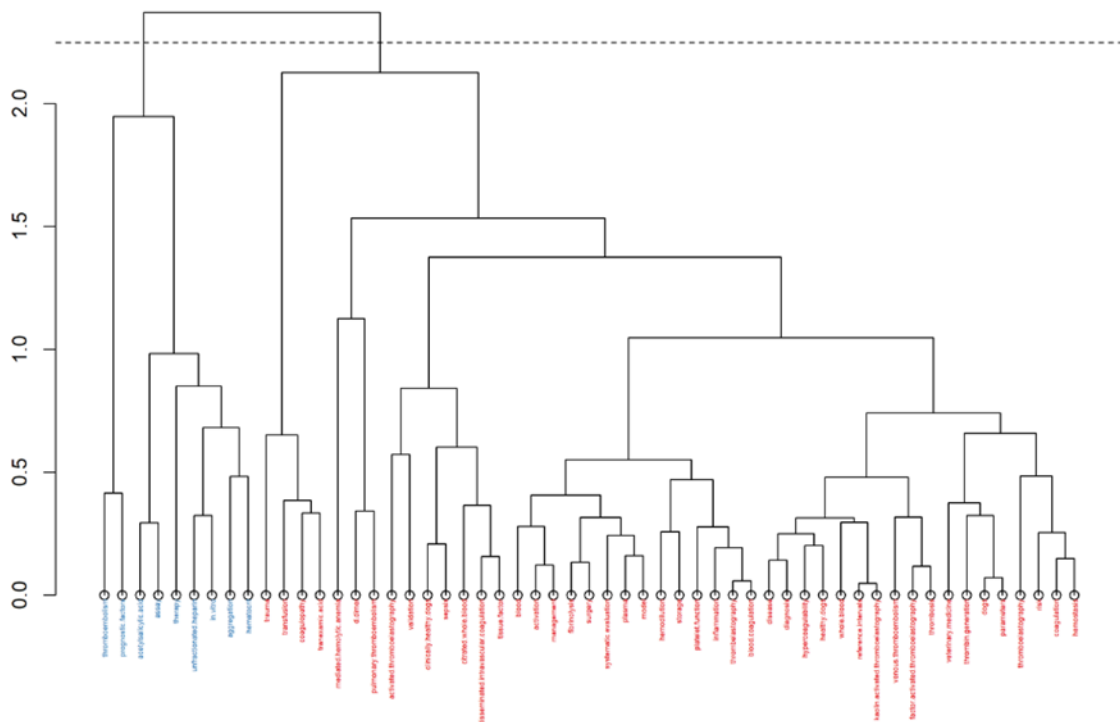


Figure 5. Word dendrogram

citation of 125.5 per article, which was only 2, in 24 years and followed by 65.8 mean total citations per article of 5 articles in 2005. In the time span of 25 years the most articles in this topic were published in the Journal of Veterinary Emergency and Critical Care with 75 articles. Followed by the Journal of Veterinary Internal Medicine, American Journal of Veterinary Research and Veterinary Clinical Pathology with 58, 34 and 28 articles, respectively. A total number of 87 journals were listed with studies about TEG in clinical veterinary science. The first articles on this topic in these journals were generally published in 2005 or 2006. The author Kristensen A.T. is the most relevant author on the subject with 39 articles followed by Wiinberg B. and Brainard B.M. with 38 and 21 articles, respectively. Whereas the contribution of Wiinberg B. to a published set of articles (fractionalize articles) is about 7.54, this contribution is about 6.97 by Kristensen A.T. Twelve authors, out of 1152, got 10 or more articles on this topic based on the WoS database, according to the bibliometric analysis. Wiinberg B. got the most local citations with 668, followed by Kristensen A.T. and Jensen A.L. with 563 and 414 local citations, respectively (Figure 1). Nine-teen authors’ local citations were above 100 and about 70% of the listed 675 authors’ local citation times were ten or below. The results of the corresponding author’s countries had shown the highest number of multiple country publications (MCP) and single country publications (SCP), with 21 and 185, respectively, which were originated from the USA (Figure 2). However, MCP were relatively low in contrast to the total article number of the USA. Denmark was analyzed with a MCP ratio

with 15 out of 38 publications. The analysis of scientific production based on countries included 28 countries.

The high difference in country based scientific production between USA, which ranks first with 549, and Denmark, which ranks 2nd with 115 articles, is noteworthy. The countries ranked between 3rd and 11th had between 100 and 10 publications. The first 5 most productive countries, USA, Denmark, Canada, United Kingdom (UK) and Germany, respectively, were also the most total cited countries (total citation numbers 3404, 1076, 480, 308 and 303, respectively) in the same ranking. However, although South Africa had more publications and 103 total citations, China had taken precedence in the analysis of countries receiving 225 total citations. Likewise, Australia, with 52 total citations, and Switzerland, with 22 total citations, were ahead of South Korea with 20 total citations. Apart from this, China ranks first with the average number of citations to a publication with a number of 75. This value is followed by Denmark, United Kingdom and Germany with 28.3, 22 and 21.6, respectively. The first two most local cited articles were written by Wiinberg B. et al. (2005) with 107 and again Wiinberg B. et al. (2008) with 91 local citations. The ranking of the most occurring words had shown that dogs were the most studied animals in the clinical use of TEG. Apart from the words dog, thromboelastography and coagulation, hypercoagulation stands out in the fourth place. The terms factor-activated thromboelastography, mediated-hemolytic anemia, disseminated intravascular coagulation and tissue factor follow, respectively. However, in the distribution of trend topics over time, the keyword antithrombotics showed up 5 times in the last year (Figure 3). The words in the top

ten have the highest frequency of occurrence in the years 2013-2015 and later. Besides the keyword antithrombotics, in the last 3 years, the term rational use and variability were included in studies.

The factorial analysis, worked out by the multiple correspondence analysis (MCA) method, of study concepts based on keywords, resulted in two clusters (Figure 4). The clusters had shown that TEG's veterinary clinical use studies were examined in two different concepts. The bigger blue cluster 1 demonstrated keywords, which were generally used together in articles and the distance between the words determines the frequency of the use together. The closer the words are, the more often they are used together and the further apart they are, the frequency of use together is low. It can be observed that the topics of dogs, coagulation, reference intervals, thromboelastography and hemostasis had been used together in studies. The red cluster 2 appeared with 9 words, which were including and generally about the topics therapy and assay. The word dendrogram made it easier to identify which words are close or far to each other (Figure 5). The words in blue color in the word dendrogram in Figure 4 reflect the words in cluster 2 from Figure 3 and the red ones are the words from cluster 1. The height of the dendrogram measures the distance between word clusters, and the distance between words on the horizontal axis determines different concepts. Words that are close to each other explain concepts that are close or similar to each other. In this case, factor activated thromboelastography and acetyl salicylic acid were not used together frequently enough to describe a study concept. Whereas it can be suggested that disease, diagnosis and hypercoagulability were topics of a study design. The change of topics in veterinary clinical use of TEG in future studies could change the factorial analysis.

The collaboration of studies based on countries had shown the USA with the highest number of collaborative scientific studies and an outstanding collaboration with Denmark. Followed by the scientific partnership between Denmark and South Africa.

Discussion and Conclusion

The low number of documents based on WoS database, despite a time span of 25 years, was remarkable. The costs of TEG evaluations mentioned by Corda et al. (2023), could have been a contributing factor to this result. The annual increase of documents in veterinary clinical use of TEG was analyzed as %11.73 regarding an increasing trend of scientific research. Only 7 single authored documents were detected, whereas 1152 authors were included in scientific documents in this field. Co authorship is notably high and could be called a need. One of the articles in 2000 titled "Evidence of hypercoagulability in dogs with parvoviral enteritis" by Otto et al. was the first publication of hypercoagulation detection via thromboelastography in clinical ill dogs. It is possible to assume that the studies published in these years contain basic and valuable information about the clinical use of thromboelastography in veterinary medicine. While the number of articles identified

in this field was 19 between 2000 and 2007, at least 10 or more studies were identified every year after 2007.

The most relevant author Kristensen A.T. with 39 articles, was ranked in second place in the contribution of published set of articles, assumably due to collaboration with more authors.

The country-based collaboration results showed a cooperation triangle between the USA, Canada and Europe (Denmark, United Kingdom and Germany). It is also detectable that the USA worked cross-continental with Australia and New Zealand. The co-authorship in this field between countries hadn't shown a strong impact on the total number of publications as seen in Figure 2. The USA got the first place with 206 articles in country-based scientific production ranking, mostly without any other country collaboration.

The first publication regarding the use of TEG in clinical veterinary medicine by Otto et al. (2000) originated from the USA, and in accordance with the present study results, it seems that studies on this subject continue to be carried out with great interest in the USA.

Despite the high difference in the number of publications and total citations on a country basis, the impact of the studies, based on average article citation numbers, of China, Denmark, UK and Germany is quite high in contrast to USA. However, these total citation numbers include global and local citations. Local citations were documents in the field of veterinary clinical use of TEG, whereas global citations involve the whole WoS database without any study field limitations. The number of citations of the top 10 most local cited publications was determined to be over 47. Four of these articles are documents with content regarding the use of TEG in veterinary medicine and especially in dogs. Six of them are related to the evaluation of coagulation by TEG in dogs depending on disease, symptoms or breed.

In fact, TEG research in the veterinary field started with the possibility of diagnosing hypercoagulation with a single analysis, and this showed itself in the keyword rankings with "hypercoagulation" on the fourth place. Here it can be determined that a study on treatment is not among the top ten topics but in the last year "antithrombotics" was used 5 times as seen in Figure 3 and it can be concluded that studies including treatment may attract interest in the future. Topics appeared in the last 5 years have shown studies on the routine use of TEG and the variability of analysis results, which might be a sign that efforts are being made to use TEG safely as a diagnostic tool in routine veterinary use.

This study showed that TEG in veterinary clinical use is a relevant research area with topics changing and making progress over time. The low number of studies in some animal species such as horses and cats show that more information is needed in this field and points to an area that is open to study. Likewise, although monitoring patients with TEG in the treatment of coagulopathy in the veterinary clinical field is very important and one of the target purposes of the analyzer, there are deficiencies in the literature. It is undeniable that future studies planned in this field will contribute significantly to the literature in order to ensure

safe clinical use on a routine basis. The information obtained as a result of bibliometric analysis could help in the design of future studies related to TEG in veterinary clinical use.

Conflict of Interest

The authors stated that they did not have any real, potential or perceived conflict of interest.

Ethical Approval

This study is not subject to HADYEK permission in accordance with Article 8 (k) of the "Regulation on Working Procedures and Principles of Animal Experiments Ethics Committees"

Funding

This study wasn't supported.

Similarity Rate

I declare that the similarity rate of the article is 4% as stated in the report uploaded to the system.

Acknowledgment

I would like to thank Assoc.Prof.Dr. Yasin ALTAY for his support in this study.

Explanation

Any result of this study wasn't used before.

Author Contributions

Motivation / Concept: OEI

Design: OEI

Control/Supervision: OEI

Data Collection and / or Processing: OEI

Analysis and / or Interpretation: OEI

Literature Review: OEI

Writing the Article: OEI

Critical Review: OEI

References

Altay Y, Kaplan S, 2023: Bibliometric Analyzes of Some Major Effect Genes Associated with Meat Yield Traits in Livestock. *Selcuk J Agr Food Sci*, 37 (3), 608-617.

Alwood AJ, Downend AB, Slensky KA, et al., 2004: Resident forum abstracts: evaluation of thrombelastography (TEG) in normal cats. *J Vet Emerg Crit Care*, 14, 1–17.

Anonim (1): <https://www.webofscience.com/wos/woscc/basic-search>, Access date; 02.10.2023.

Aria M, Cuccurullo C, 2017: Bibliometrix: An R-tool for comprehensive science mapping analysis. *J Informetr*, 11 (4), 959-975.

Bassan T, Pastor J, Agulla B, et al., 2023: Reference Range of Kaolin-Activated Thromboelastography (TEG) Values in Healthy Pet Rabbits (*Oryctolagus cuniculus*). *Animals*, 13 (14), 2389.

Bauer N, Eralp O, Moritz A, 2009: Establishment of reference intervals for kaolin-activated thromboelastography in dogs including an assessment of the effects of sex and anticoagulant use. *J Vet Diagn Invest*, 21 (5), 641–648.

Blois SL, Holowaychuk MK, Wood RD, 2015: Evaluation of thromboelastography in two factor XII-deficient cats. *JFMS Open Rep*, 1 (1), 2055116915585025.

Borrelli A, Botto A, Maurella C, et al., 2017: Thromboelastometric assessment of hemostasis in newborn Piemontese calves. *J Vet Diagn Invest*, 29 (3), 293–297.

Cam B, Sagdilek E, Yildirim N, et al., 2015: Cytidine 5'-diphosphocholine differentially affects hemostatic parameters in diverse conditions in rats: an investigation via thromboelastography. *Shock*, 43 (4), 387–394.

Corda F, Ballocco I, Corda A, et al., 2023: Coagulation Abnormalities in Dogs with Parvoviral Enteritis. *Vet Sci*, 10 (1), 41.

Cruz MV, Luker JN, Carney BC, et al., 2017: Reference ranges for rotational thromboelastometry in male Sprague Dawley rats. *Thrombosis J*, 28, 15-31.

Dixon A, Hall EJ, Adamantos S, et al., 2021: Hypercoagulability in dogs with chronic enteropathy and association with serum albumin concentration. *J Vet Intern Med*, 35 (2), 860–866.

Döderlein E, Mischke R, 2015: Reference intervals for thromboelastometry with the ROTEM delta in cats. *Res Vet Sci*, 100, 271–276.

Engelen C, Moritz A, Barthel F, et al., 2017: Preliminary reference intervals and the impact of citrate storage time for thrombelastography in cats including delta and the velocity curve. *BMC Vet Res*, 13 (1), 366.

Ergin M, Albayrak Delialioğlu R, Altay Y, Koşkan Ö, 2023a: Bibliometric analysis of the studies determined by the monte carlo simulation technique of the power of the test. *BSJ Eng Sci*, 6(4), 414-420.

Ergin M, Albayrak Delialioğlu R, Altay Y, Koşkan Ö, 2023b: Bibliometric Analysis of Lactation Curves in Livestock. *Turk Tarim Doga Bilim Derg*, 10 (4), 1009-1016.

Fenty RK, Delaforcade AM, Shaw SE, et al., 2011: Identification of hypercoagulability in dogs with primary immune-mediated hemolytic anemia by means of thromboelastography. *J Am Vet Med Assoc*, 238 (4), 463–467.

Goggs R, Wiinberg B, Kjelgaard-Hansen M, et al., 2012: Serial assessment of the coagulation status of dogs with immune-mediated haemolytic anaemia using thromboelastography. *Vet J*, 191 (3), 347–353.

Han HJ, Kim JH, 2022: Correlation Between D-Dimer Concentrations and Thromboelastography in Dogs With Critical Illness: A Retrospective, Cross-Sectional Study. *Front Vet Sci*, 14 (9), 844022.

Hartert H, 1948: Blood clotting studies with thrombus stressography; a new investigation procedure. *Klin Wochenschr*, 26, 577–583.

Honoré ML, Pihl TH, Nielsen LN, 2021: A pilot study evaluating the Calibrated Automated Thrombogram assay and application of plasma-thromboelastography for detection of hemostatic aberrations in horses with gastrointestinal disease. *BMC Vet Res*, 17 (1), 346.

Johnson CA Jr, Woolley JR, Snyder TA, et al., 2018: Assessment of Thrombelastography and Platelet Life Span in Ovines. *Artif Organs*, 42 (12): 427-434.

Kakar N, Daniel G, Fellman C, et al., 2021: Thromboelastography in cats with cholestatic liver disease. *J. Feline Med. Surg*, 23 (2), 160–167.

- Kaplan S, Altay Y, 2023: Bibliometric analysis of next-generation sequence applications in livestock. *BSJ Agri*, 6 (5), 485-491.
- Kaur H, Fisher K, Othman M, 2019: Thromboelastography testing in mice following blood collection from facial vein and cardiac puncture. *Blood Coagul. Fibrinolysis*, 30 (7), 366–369.
- Kol A, Nelson RW, Gosselin RC, et al., 2013: Characterization of thrombelastography over time in dogs with hyperadrenocorticism. *Vet J*, 197 (3), 675-81.
- Kristensen AT, Wiinberg B, Jessen LR, et al., 2008: Evaluation of human recombinant tissue factor-activated thromboelastography in 49 dogs with neoplasia. *J Vet Intern Med*, 22 (1), 140–147.
- Langhorn R, Bochsén L, Willesen JL, et al., 2019: Thromboelastography-guided transfusion in dogs with hypocoagulable disorders: a case series. *Acta Vet*, 61 (1), 35.
- Lovett AL, Gilliam LL, Sykes BW, McFarlane D, 2022: Thromboelastography in obese horses with insulin dysregulation compared to healthy controls. *J Vet Intern Med*, 36 (3), 1131-1138.
- Majoy SB, de Laforcade AM, Barnard MR, et al., 2015: Platelet activation in a population of critically ill dogs as measured with whole blood flow cytometry and thromboelastography. *Am J Vet Res*, 76 (4), 328–337.
- Mendez-Angulo JL, Mudge MC, Vilar-Saavedra P, et al., 2010: Thromboelastography in healthy horses and horses with inflammatory gastrointestinal disorders and suspected coagulopathies. *J Vet Emerg Crit Care*, 20 (5), 488–493.
- Önder H, Tirink C, 2022: Bibliometric analysis for genomic selection studies in animal science. *J Inst Sci Tech*, 12(3), 1849-1856.
- Otto CM, Rieser TM, Brooks MB, Russell MW, 2000: Evidence of hypercoagulability in dogs with parvoviral enteritis. *J Am Vet Med Assoc*, 217 (10), 1500-1504.
- Pereira JM, Rohn K, Mischke R, 2020: Reference intervals for rotational thromboelastometry measurements using the ROTEM® delta device in dogs. *Res Vet Sci*, 130, 26–32.
- Rubanick JV, Pashmakova MB, Bishop MA, et al., 2017: Correlation between thromboelastography and traditional coagulation test parameters in hospitalized dogs. *Vet Med*, 8 (8), 21-26.
- Schroeder JA, Kuether EA, Fang J, et al., 2021: Thromboelastometry assessment of hemostatic properties in various murine models with coagulopathy and the effect of factor VIII therapeutics. *J Thromb Haemost*, 19, 2417–2427.
- Scruggs JL, Flatland B, McCormick KA, et al., 2016: Biological variation of thromboelastography variables in 10 clinically healthy horses. *J Vet Emerg Crit Care*, 26 (1), 80–84.
- Sinnott VB, Otto CM, 2009: Use of thromboelastography in dogs with immune-mediated hemolytic anemia: 39 cases (2000-2008). *J Vet Emerg Crit Care*, 19 (5), 484–488.
- Sommerey CC, Williams TL, McCrone I, et al., 2014: Thromboelastography in healthy dairy cows. *J Dairy Sci*, 97 (9), 5474-80.
- Strandberg G, Lipcsey M, Eriksson M, et al., 2016: Analysis of thromboelastography, PT, APTT and fibrinogen in intraosseous and venous samples-an experimental study. *Scand J Trauma Resusc*, 24 (1), 131.
- Studer KA, Hanzlicek A, Di Girolamo N, et al., 2021: Effect of rest temperature on rotational thromboelastometry in New Zealand White rabbits. *J Vet Diagn Invest*, 33(1), 47-51.
- Wiinberg B, Jensen AL, Johansson PI, et al., 2008: Thromboelastographic evaluation of hemostatic function in dogs with disseminated intravascular coagulation. *J Vet Intern Med*, 22, 357-365.
- Wiinberg B, Jensen AL, Rojkaer R, Johansson P, Kjølgaard-Hansen M, Kristensen AT, 2005: Validation of human recombinant tissue factor-activated thromboelastography on citrated whole blood from clinically healthy dogs. *Vet Clin Pathol*, 34 (4), 389-93.
- Wiinberg B, Kristensen AT, 2010: Thromboelastography in veterinary medicine. *Semin Thromb Hemost*, 36 (7), 747-56.
- Wilkinson A, Mencioti G. Thromboelastography in cats with hypertrophic cardiomyopathy. Access via: <https://research.vetmed.vt.edu/clinical-trials/current-studies/hcm-feline.html>. Access date: 06.12.2023
- Yilmaz Z, Kocatürk M, Inan OE, et al., 2017: Thromboelastographic evaluation of hemostatic functioning dogs with dilated cardiomyopathy. *Turkish J Vet Anim Sci*, 41 (3), 372-379.



Sıcak İklim Koşullarında Linda Kazları ve Yerli Kazların (*Anserinae sp.*) Yumurta Verimi ve Doğal Kuluçka Performansı Üzerine Bir Araştırma

Sabri YURTSEVEN^{1,a,*}, Zeliha KAYA^{1,b}, Mehmet ÇETİN^{1,c}

¹Harran Üniversitesi Ziraat Fakültesi Zootekni Bölümü,
Osmanbey Kampüsü-63050, Şanlıurfa, Türkiye

^aORCID: 0000-0002-6600-8772;

^bORCID: 0000-0001-7039703X;

^cORCID: 0000-0002-2895-3618;

Geliş Tarihi: 16.01.2024

Kabul Tarihi: 16.04.2024

Bu makale Nasıl kaynak gösterilir: Yurtseven S, Kaya Z, Çetin M. (2024). Sıcak iklim koşullarında Linda Kazları ve Yerli Kazların (*Anserinae sp.*) Yumurta Verimi ve Doğal Kuluçka Performansı Üzerine Bir Araştırma. Harran Üniversitesi Veteriner Fakültesi Dergisi, 13(1): 42-47. DOI:10.31196/huvfd.1420104.

***Yazışma adresi:** Sabri YURTSEVEN

Harran Üniversitesi Ziraat Fakültesi Zootekni Bl. Osmanbey Kampüsü-63050, Şanlıurfa, Türkiye.

e-mail: syurtseven@harran.edu.tr,

Online erişim adresi: <https://dergipark.org.tr/tr/pub/huvfd>

Özet: Bu çalışma, Türk yerli kazları ve Linda kazlarının yumurta verimi, yumurtlama periyodu, bazı yumurta özellikleri ve doğal kuluçka yeteneklerinin belirlenmesi amacıyla yapılmıştır. Çalışmada, Linda kazları bir yumurtlama periyodu boyunca Yerli kazlara oranla daha fazla yumurta üretmişlerdir. Ancak, bazı yumurta kalite özellikleri açısından Yerel kazların daha üstün olduğu görülmüştür. Farklı iki genotip, doğal kuluçka özellikleri açısından da incelenmiştir. Yerli kazlar, Linda kazlarına göre daha ağır yumurtalar üretmişler ve yumurta kabuk kalınlığı, yumurta uzunluğu ve yumurta hacmi gibi özellikler bakımından daha üstün özellikler göstermişlerdir. Yerli kazların, doğal kuluçka özellikleri açısından diğer genotipten daha iyi olduğu tespit edilmiştir. Ancak, Yerel kazların yumurtlama dönemi Linda kazlarına göre bir ay daha kısa olmuş ve yaklaşık olarak iki ay sürmüştür. Yumurta verimi bakımından, Yerli genotip Linda kazlarıyla rekabet edemese de Linda kazının, bazı doğal kaz davranışları, annelik içgüdüleri, kuluçka esnasında yumurtalarına sahip çıkma ve kuluçkaya yatma (gurk olma) vb. gibi özellikler bakımından Yerli kazlardan daha geri olduğu gözlenmiştir.

Anahtar Kelimeler: Doğal kuluçka, Linda kazı, Yerli kaz, Yumurta özellikleri, Yumurta verimi.

A Study on Egg Productivity and Natural Hatching Performance of Linda Geese and Domestic Geese (*Anserinae Sp.*) Under Hot Climate Conditions

Abstract: This study aimed to determine the egg production, laying period, some egg characteristics, and natural incubation abilities of Turkish native and Linda geese. In the study, Linda geese produced more eggs during a laying period than native geese. However, native geese were found to be superior in some egg quality characteristics. Two different genotypes were also investigated in terms of natural incubation traits. Native geese produced heavier eggs than Linda geese and exhibited superior characteristics in terms of eggshell thickness, egg length, and egg volume. It was determined that native geese were better in terms of natural incubation traits compared to the other genotype. However, the laying period of native geese was one month shorter than that of Linda geese and lasted approximately two months. In terms of egg production, while the native genotype cannot compete with the Linda geese, it has been observed that the Linda goose is inferior to the native geese in certain natural goose behaviors, such as maternal instincts, guarding eggs during incubation, and brooding.

Keywords: Domestic local geese, Egg quality, Egg traits, Linda geese, Natural hatching, Turkish local geese.

Giriş

Kazlar, soğuk iklim koşullarına olduğu kadar sıcak ve kuru iklim koşullarına da uyum sağlayabilen kanatlı hayvanlardır (El-Hanoun ve ark., 2017a; Guo ve ark., 2020; Liu ve Zhou, 2013). Türkiye'deki toplam kaz sayısı bir milyon dört yüz binin biraz üzerindedir ve bu kazların % 0.6 kadarı Şanlıurfa bölgesindedir (TÜİK, 2022). Kazlar fazla yem tüketirler ve iyi otlayıcılar olarak bilinirler. Kazların meradan çok iyi yararlanması ekonomik açıdan yem maliyetini önemli ölçüde azaltmaktadır. Kazlar hareketli hayvanlardır, bu nedenle kazları barınakta sadece konsantre yemle beslemek ekonomik değildir ve doğalarına aykırıdır (El-Hanoun ve ark., 2012). Kazların üreme döngüsü yüksek derecede mevsimseldir (Şubat-Mayıs dönemi). Yumurtlama sezonu yılda iki veya üç ay kadar sürer. Kaz yumurtaları, insan tüketimi için kullanılmaz ve daha ziyade civciv üretimi için değerlidir. Bu nedenle, tüm yumurtalar kuluçka için kullanılır ve döllü yumurta sayısı ile kuluçka randımanı kaz üretimi için son derece önemlidir (El-Hanoun ve ark., 2017b).

Linda kazları son 10 yılda Türkiye'de en çok tercih edilen hibrit kazlar arasındadır. Yumurta verimi (yılda 40-50 adet, yerli kazların yaklaşık 2.5 katı) ve elde edilen canlı palaz oranının yüksek olması ve beyaz renkli olmaları Linda kazlarının önemli tercih sebepleri arasındadır. Ancak, yüksek yumurta üretimi dışında bazı dezavantajlara da sahiptirler (Kaya ve Yurtseven, 2021). Yerli kazların yıllık ürettiği yumurta sayısı ise yaklaşık olarak 15 adet kadardır (Anonim, 1987). Yerli bir kaz, doğal olarak yumurta üretimi bakımından hibrit bir genotiple rekabet edemez. Son yıllarda, düşük yumurta verimi ileri sürülerek Yerli kaz yetiştiriciliği azalmakta ve yerini hibrit kazlara bırakmaktadır. Ancak, Linda kazı gibi hibrit kazların yumurta verimlerinin artırılması amacıyla yapılan seleksiyon sonucunda doğal kuluçka özelliklerini gittikçe kaybettikleri gözlenmiştir. Ancak, Yerli kazlar doğal kuluçka özelliklerini büyük ölçüde sürdürmektedirler. Bu durum, Yerli kaz üreticiliği yapan kişilerin köylerde kuluçka makinesine ihtiyaç duymadan üretim yapmalarını mümkün kılmaktadır. Dolayısıyla, ülkemiz için endemik tür olan kaz genotiplerinin korunması ve hibrit kazlara göre avantajlı yanlarının öne çıkarılması büyük önem arz etmektedir.

Genel olarak kazların kuluçka verimliliği yüksek varyasyona sahiptir (%50-90) ve bu yüksek varyasyonun nedeni tam olarak bilinmemektedir (Tilki ve İnal, 2004). Yerli kaz yumurtasının ortalama ağırlığı 123-185 g arasında iken (Saatçi ve ark., 2005), Linda kazı yumurtası 119-125 g aralığındadır (Sarı ve ark., 2019). Yumurta ağırlığı, yumurtadan çıkan palazların ilk iki haftada hayatta kalma oranını, yürüme, yüzme ve büyüme performanslarını etkilemektedir (Dawson ve Clark, 2000; Kucharska-Gaca ve ark., 2022). Ancak, yumurta ağırlığının yanı sıra, yumurtaların şekil indeksi ve özgül ağırlığı gibi kriterler de kuluçka için önemlidir. Yerli kazlar ile, yüksek yumurta verimine sahip ve serin iklimle uyum sağlamış olan Linda kazlarının (Reuter, 2012) yumurtlama performansları ve kuluçka randımanları Şanlıurfa gibi sıcak bir bölgede henüz araştırılmamıştır. Bu çalışmada, Şanlıurfa ilinde sıcak şartlarında yetiştirilen Linda kazları ve Yerli kazların, cinsi olgunluk yaşı, yumurtlama yaşı,

yumurta verimi, yumurta özellikleri, yumurtlama periyodu ve doğal kuluçka özelliklerinin karşılaştırmalı olarak incelenmesi amaçlanmıştır.

Materyal ve Metot

Bu çalışma, Harran Üniversitesine ait Osmanbey kampüsü Ziraat Fakültesinin Tarımsal Araştırma ve Uygulama Merkezine ait bir kaz üretim çiftliğinde gerçekleştirilmiştir. Bölge 37° 9' 32.9364 enlem ve 38° 47' 48.8724 boylamda bulunmaktadır. Hayvanlar üzerinde çalışma yapma izni, Harran Üniversitesi yerel etik komitesinden alınmıştır (Etik Onay Numarası: HRÜ-HADYEK-2020/001-01/07). Çalışmada, 200 adet Yerli kaz ve 90 adet Linda kazı kullanılmış olup, çalışma 15 Ocak-01 Mayıs 2020 tarihleri arasındaki dönemde yürütülmüştür. Her iki kaz genotipi de, henüz yumurtlamaya başlamadan izlenmeye alınmıştır. Kazların ilk yumurtlama tarihi, yumurta verimi, yumurtlama süresi, bir dönem boyunca üretilen yumurta sayısı, kuluçkaya yatma (gürk olma) ve kuluçka özellikleri dikkatlice takip edilmiştir. Hayvanlar kendi doğal ortamlarında bırakıldığı için yem tüketim davranışları incelenmemiştir. Yumurtlama dönemi başladığında Mart ayından itibaren Mayıs'ın sonuna kadar olan sıcaklık değişiklikleri Celsius cinsinden ölçülmüştür. Sıcaklıklar, yumurtlama döneminin başında 15 °C iken dönem sonunda 35 °C'ye kadar yükselmiştir. Çalışmaya konu olan Yerli ve Linda kazlarının yumurtlama performansları ve davranışlarının incelenmesi ve kuluçka performansının ortaya konulması yaklaşık 105 gün sürmüştür.

Yerli ve Linda kazları ayrı bölmelerde olacak şekilde, kaz başına 1.43 m² alan tahsis edilmiş ve yarı-entansif sistem uygulanmıştır. Vaktinin çoğunu merada geçiren kazlara akşam mera dönüşü sınırlı düzeyde ıslak arpa ve mısır ile seyreltilmiş kesif yem takviyesiyle akşam yemlemesi yapılmıştır. Uzun süre merada kalan kazlarda yem tüketiminin kontrolü mümkün olmadığından ve sadece yumurtlama davranışları takip edildiği için yem tüketim performansları incelenmemiştir. Otlatma için, her 1 m²'ye bir yetişkin kaz olacak şekilde İtalyan çimi (Çayır otu - *Lolium multiflorum*) merası hazırlanmıştır. Meranın ekim işlemi yaz ortasında yapılmış ve kış aylarına kadar yeşil kalmıştır. Kazlar, barınak içinde ticari yumurta yemi (%15.8 HP ve 2850 kcal/kg ME, %4 Ca) ve 1/5 oranında seyreltilmiş arpa ve mısır ile beslenmişlerdir. Bu uygulamanın nedeni, kazların yem tüketiminin yüksek olması ve sadece ticari kaz yemi ile beslemenin ekonomik olmamasıdır.

Yumurtlama döneminin yaklaşması ile (Şubat başı) erkek-dişi oranı benzer (1:1), 200 adet Yerli kazdan (100 erkek, 100 dişi) ve 90 adet Linda (45 erkek, 45 dişi) kazının yumurtlama davranışları izlenmeye başlamıştır. Kazların yumurtlama dönemi başladığında, her genotip için başlangıç tarihi kaydedilmiştir. Yumurtaların toplanması akşam saatlerinde yapılmış ve toplanan yumurtalar sayılarak tartılmışlardır. Ağırlıkları alınan yumurtalar, kazların doğal gürk davranışları başlayınca veya kuluçka makinesine konuluncaya kadar serin bir yerde muhafaza edilmiştir. Yumurta toplama işlemi, yumurtlama dönemi bitinceye

kadar yapılmış ve her iki genotip için yumurtlama periyodu ve bu süre içerisindeki yumurta verimi belirlenmiştir. Toplam elde edilen yumurta sayısının o genotipin dişi sayısına bölünmesiyle bir dişi kazın sezon boyunca ürettiği yumurta miktarı ortaya çıkmıştır. Yumurtlama sürerken gurka yatma eğiliminde olan kazlar her genotip için sayılmış ve gurka yatan kazların altına 13'er adet yumurta konulmuştur. Gurka yatmayan kazların yumurtaları ise kuluçka makinesine konulana kadar bekletilmiştir. Yerli kazların neredeyse tamamı doğal gurka yattığı için kuluçka makinesine konulacak yumurta kalmamıştır. Linda kazlarının gurk olayı çok az olduğundan tüm yumurtalar kuluçka makinesine konulmuştur. Her iki genotipten gurka yatanlardan geriye kalan 45 adet yumurta, 15'erli olarak 3 tekerrür halinde kuluçka makinesine konularak kuluçka randımanına belirlenmiştir. Her genotipten 15 yumurtanın bazı özelliklerine bakılmış ve bu yumurtalar inkübe edilmemiştir. Kaz yumurtaları insan tüketimine arz edilmediğinden iç kalite özellikleri incelenmemiş ve sadece dış kalite özelliklerine bakılmıştır. Yumurta özelliklerinden yumurta ağırlığı, kabuğu kalınlığı (kırık ve kuluçka sonrası dölsüz olan yumurtalardan) incelenmiş, şekil indeksi, yumurta hacmi ve özgül ağırlıkları hesapla bulunmuştur.

$$\text{Yumurta şekil indeksi (\%)} = \frac{\text{yumurtanın eni (mm)}}{\text{yumurtanın boyu (mm)}}$$

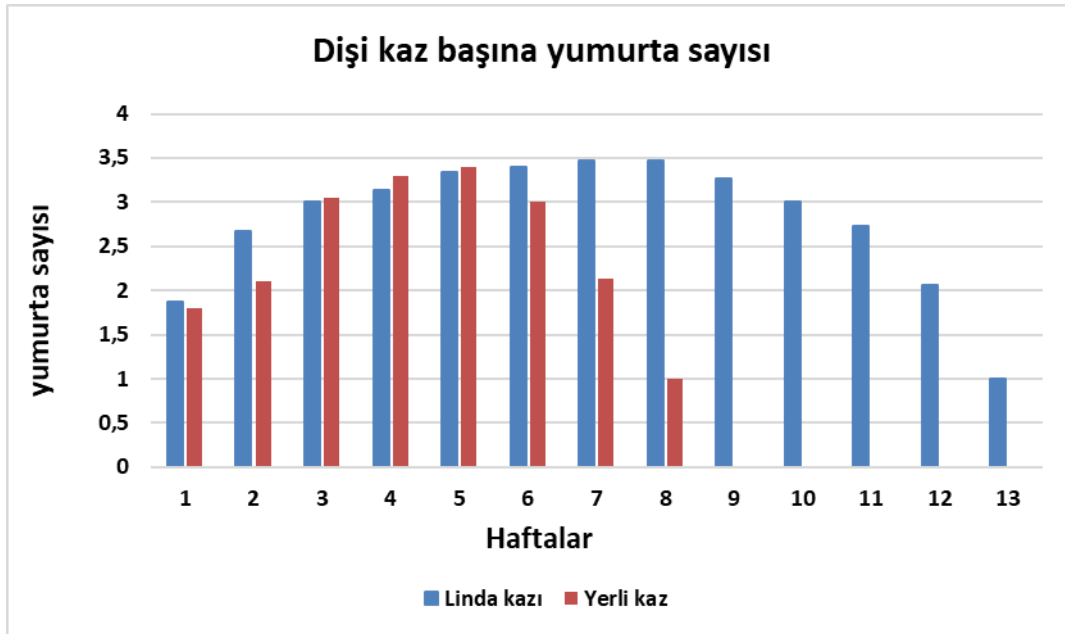
$$\text{Yumurta hacmi (mm}^3\text{)} = 0.507 \times \text{yumurta en (mm)} \times \text{yumurta boy}^2 / 1000$$

$$\text{Yumurta özgül ağırlığı (g/cm}^3\text{)} = \frac{\text{yumurta ağırlığı (g)}}{\text{yumurta hacmi}}$$

İstatistiksel analiz: Araştırma modeli iki yönlü tesadüf parselleri deneme desenine göre düzenlenmiştir. Yumurta verimi, kuluçka randımanı ve yumurta kalite özelliklerine ait ortalamalar, iki gruplu denemelerin analizinde kullanılan "Independent Sample-t" testine göre yapılmıştır. İstatistiksel olarak, gruplar arasındaki farklılıklar aynı modelde %0.05 anlamlılık düzeyinde test edilmiştir. Verilerin istatistiksel analizinde SPSS (2000) yazılımı kullanılmıştır.

Bulgular

Yumurtlamaya başlama ve yumurtlama süresi: Yerli kazlar yumurtlamaya daha erken başlamış ve bu 16 Şubat 2020 tarihine tekabül etmiştir. Linda kazları ise daha geç yumurtlamaya başlamış, ilk yumurtalar 10 Mart 2020'de görülmüş ve yumurtlama 13. haftaya kadar devam etmiştir (Şekil 1).



Şekil 1. Yumurta üretiminin zamana bağlı değişimi (adet).

Tablo 1. Linda ve Yerli kazlara ait yumurta verimi, yumurta ağırlığı ve kuluçka randımanlarına ilişkin değerler.

Özellikler		Ortalama ± Std. Sapma	SEM*	P=**
Toplam yumurta sayısı, adet	Linda	36.4 ± 1.28	0.44	0.01
	Yerli	15.4 ± 2.28		
Kaz başına düşen yumurta sayısı/hafta, adet	Linda	2.84 ± 0.72	0.20	0.81
	Yerli	2.18 ± 0.71		
Ortalama yumurta ağırlığı, g	Linda	114.44 ± 5.80	4.87	0.01
	Yerli	133.58 ± 19.39		
Doğal kuluçka randımanı, %	Linda	61.00 ± 4.07	2.19	0.01
	Yerli	94.00 ± 6.12		
Kuluçka makine randımanı, %	Linda	81.00 ± 5.13		

*: SEM: standard error mean (standart hataların ortalaması), P: Önemlilik düzeyi

Tablo 2. Linda ve Yerli kazların bazı yumurta özelliklerine ilişkin değerler.

Özellikler		Ortalama ± Std. Sapma	SEM*	P=**
Yumurtanın eni, mm	Linda	53.89 ± 1.42	0.64	0.01
	Yerli	56.59 ± 2.26		
Yumurtanın boyu, mm	Linda	79.22 ± 2.86	1.30	0.01
	Yerli	84.12 ± 4.66		
Kabuk kalınlığı (küt kısım), mm	Linda	0.55 ± 0.04	0.02	0.01
	Yerli	0.63 ± 0.07		
Kabuk kalınlığı (sivri kısım), mm	Linda	0.59 ± 0.04	0.02	0.01
	Yerli	0.64 ± 0.08		
Kabuk kalınlığı (yan kısım), mm	Linda	0.60 ± 0.04	0.03	0.01
	Yerli	0.79 ± 0.10		
Şekil indeksi	Linda	0.68 ± 0.03	0.01	0.62
	Yerli	0.67 ± 0.03		
Yumurta hacmi, cm ³	Linda	116.70 ± 6.73	4.36	0.02
	Yerli	137.09 ± 16.75		
Özgül ağırlık, g/cm ³	Linda	0.98 ± 0.05	0.02	0.69
	Yerli	0.97 ± 0.05		

Tablo 1’de, 100 adet Yerli dişi ve 45 adet Linda dişi kazlarının yumurtlama dönemlerinde her gruptaki toplam ve haftalık yumurta sayısı, yumurta ağırlıkları ve kaz başına haftalık yumurta adedi verilmiştir. Yumurtlama sezonu boyunca, kaz başına elde edilen yumurta sayısı bakımından genotipler arasındaki farklılığın önemli olmadığı görülmüş ($P>0.05$) ve kaz başına haftada ortalama yerli kazlar 2.18; Linda kazları 2.84 adet yumurta üretimi gerçekleştirmiştir (Tablo 1).

Doğal Gurk Davranışları: Çalışma sırasında doğal kuluçka özellikleri de takip edilmiş ve gurka oturan Linda kazlarının sayısı çok az düzeyde (7 adet) olmuş ve oran olarak %15’i geçmemiştir. Doğal olarak kuluçkaya oturan yerli kazların sayısı, Linda kazlarına göre çok daha yüksek düzeyde gerçekleşmiştir. Ayrıca, kazlardan elde edilen civcivler sayılarak her kaz bir tekerrür kabul edilmiş ve istatistiksel analiz yapılmıştır (7 adet Linda kazı, 90 adet Yerli kaz). Doğal kuluçka ile, Yerli kazların bazılarının üzerine oturdukları yumurtaların büyük bir kısmından civciv çıktığı gözlenmiştir (%94). Daha düzensiz gurka yatan Linda kazlarında ise, çıkış oranı daha düşük (%61) gerçekleşmiştir ($P<0.01$, Tablo 1).

Yumurta Kalite Özellikleri: Tablo 2’de görüldüğü gibi bazı yumurta özellikleri Linda ve Yerli kazlarda önemli düzeyde farklılıklar göstermiştir. Yerli kazların yumurtalarının daha ağır, kabuk kalınlığının ise daha fazla olduğu belirlenmiştir. Şekil indeksi ve özgül ağırlıkları genotipler arasında farklılık göstermemiş, yumurta hacmi ise yerli kazlarda daha yüksek bulunmuştur.

Tartışma ve Sonuç

Yerli kazlarda yumurtlama süresi daha kısa sürmüş olup, Linda kazları ve Yerli kazlarda yumurta üretiminin haftalara göre değişimi Şekil 1’de verilmiştir. Şekil 1 incelendiğinde, Linda kazlarında yumurta üretiminin ilk 6 hafta boyunca sürekli artarak devam ettiği ve yedinci haftada pike ulaştığı görülmektedir. Bu dönemden sonra yumurta üretimi

azalarak yumurtlama döneminin 13. haftasında son bulmuştur. Yerli kazlarda ise, yumurta verimi ilk 4 hafta boyunca sürekli artarak devam etmiş ve beşinci haftada pike ulaşmıştır. Bu dönemden sonra yumurta verimi azalarak 8. haftada son bulmuştur. Toplanan yumurtalar akşamları sayılmış ve doğal gurktan arta kalanlar güneş almayan serin bir yerde bekletilmiştir. Bu işlem, yumurtlama döneminin sonuna kadar devam ettirilmiştir. Toplam yumurta sayısı dişi kaz sayısına bölündüğünde bir dişi Linda kazının bir sezonda 36 yumurta üretirken bir dişi Yerli kazın 15 yumurta ürettiği görülmüştür (Tablo 1). Bu değer, Linda kazları için Sarı ve ark., (2019) tarafından bildirilen değer (40-50 adet) altındadır. Bunun nedeni, Linda kazlarında yumurta veriminin pik döneminin ikinci veya üçüncü yılda gerçekleşmesi olabilir. Bu çalışmada kullanılan Linda kazları, henüz ilk yumurtlama döneminde olduklarından verim düşüklüğü normal sayılabilir. Arslan ve Saatçi (2003), ikinci verim yaşında olan kazların yumurta verimlerinin birinci verim yılına göre önemli derecede yüksek olduğunu bildirmişlerdir.

Tablo 1’de kaz başına haftada 2.18-2.84 yumurta üretimi gerçekleştiği görülmektedir. Yumurta üretiminin pik seviyeye ulaştığı dönemde, Yerli kazlar için 5. hafta, Linda kazları için ise 7. haftada kaz başına en fazla 3 yumurta elde edilmiştir.

Deneme başında kazların ortalama yumurta ağırlıkları yaklaşık 125 g olup, Saatçi ve ark. (2005)’nin bildirişleriyle uyum içerisindedir. Yerli kazlara ait yumurta ağırlıklarının Sarı ve ark. (2019) ile Saatçi ve ark. (2005)’nin Yerli kazlar için bildirdiklerine göre benzer, Linda kazlarının yumurtalarından ise daha yüksek olduğu saptanmıştır. Bunun nedeni olarak, çalışmada kullanılan Linda kazlarının ilk yumurtlama yılında olmaları, Yerli kazların ise ikinci yumurtlama yılında olmaları nedeniyle yaşın etkili olması söylenebilir. Dawson ve Clark (2000), yumurta ağırlığının ilk 2 haftada kaz palazlarının yürüme, yüzme ve büyüme performanslarının yanı sıra canlı ağırlıklarını da etkilediğini bildirmişlerdir. Yapılan çalışmada,

daha ağır yumurtaya sahip olan Yerli kazların kuluçka randımanı daha yüksek (%80-90) bulunmuş ve çıkan civcivlerde ölüm oranı düşük olmuştur. Yerli kazların neredeyse tamamı doğal kuluçkaya yattığı için, bu genotipte kuluçka randımanı doğal kuluçka üzerinden verilmiştir. Linda kazlarında doğal kuluçka üzerinde bekleme çok düzensiz olup, sadece kuluçka makinesindeki randıman verilmiştir. Kuluçkaya yatan tüm Linda kazlarının barınağa yaklaşıldığında hemen ayağa kalktıkları ve follukları terk ettikleri gözlenmiştir. Yerli kazlar ise, yanlarına yaklaşılsa bile follukları terk etmedikleri ve yumurtalarını korudukları görülmüştür. Bu sonuç, Yerli kazların doğal kuluçkaya yatma özelliklerini büyük ölçüde sürdürdüklerini göstermektedir. Doğal kuluçka süresince, her iki genotipin de beslenmek için zaman zaman folluklardan ayrıldıkları gözlenmiştir.

Kazların yumurta verimleri düşük olduğundan, tamamı kuluçka edilmekte ve genelde insan tüketimi için kullanılmamaktadır (Tserveni-Goussi ve Fortomaris, 2011). Bu nedenle, yumurtaların iç kalite özellikleri incelenmemiş ve sadece dış özellikleri dikkate alınmıştır. Yerli kaz yumurtasının daha kalın ve sağlam bir yapıya sahip olduğu görülmüştür. Yumurta kabuk kalınlığı değerleri, Sarı ve ark. (2019)'nın Linda kazları için bildirdikleri değerden (0.48 mm) daha yüksek bulunmuştur. Ancak, bu farklılık, söz konusu araştırmacıların daha yaşlı (3 yaşında) Linda kazı kullanmalarına kaynaklanmış olabilir. Kanatlılarda, ilk yumurtaların daha hafif, yumurta kabuğunun ise daha kalın ve mukavim olduğu, yaş ilerledikçe yumurtaların daha ağır ve kabuklarının daha ince olduğu bildirilmiştir (Orhan ve ark., 2001). Çalışmamızda kullanılan kaz genotipleri, muhtemelen aynı yaşta olmadıklarından, kabuk kalınlığının farklılaşmasında ırk özelliklerinin yanında yaşın da etkili olduğu düşünülmektedir. Çalışmada kullanılan Yerli kazlar Linda kazlarına göre bir yaş daha büyük oldukları için, kabuk kalınlığının ilk yumurtlama döneminde olan Lindalarda daha ince olabileceği değerlendirilmiştir. Kazlarda, yumurtlama döneminin başında belirlenen kabuk kalınlığının, yumurtlama dönemi sonunda belirlenen değerden daha yüksek olduğu bildirilmiştir (Biesiada-Drzazga ve ark., 2015). Dolayısıyla, yumurtlamanın daha ileri dönemlerinde bulunan Yerli kazların azalan yumurta kalınlıklarının bile Linda'lardan daha fazla olduğu ve Yerli kaz yumurtasının mukavemet açısından daha sağlam olduğu belirlenmiştir.

Çalışmamızda, kuluçkalık yumurta özellikleri açısından, yumurta ağırlığının yanı sıra yumurtaların özgül ağırlığı ve şekil indeksi de saptanmıştır. Afrika, Çin, Toulouse ve Embden kazlarının yumurtalarında özgül ağırlıklar sırasıyla; 1.079, 1.08, 1.08 ve 1.079 olarak hesaplamıştır (Arroyo, 1990). Çalışmamızdaki özgül ağırlık değerleri bunlardan daha düşük (1'e yakın) bulunmuş ve Linda ile Yerli kazlarda önemli bir farklılık göstermemiştir. Özgül ağırlığın diğer çalışmalara göre düşük bulunması, bekletilen yumurtalardaki ağırlık kaybından kaynaklanmış olabilir. Bölge nispeten sıcak ve kuru iklime sahip olduğu için kuluçka öncesi bekletilen yumurtalarda sezon başında ortalama 125 gram olan yumurta ağırlığı sezonu sonunda özellikle Linda kazlarında 114.4 grama kadar gerilemiştir. Ancak, Yerli kaz yumurtalarının bu açıdan daha stabil olduğu ve sezon sonuna kadar daha iyi ağırlıklarını korudukları görülmüştür. Diğer

tarafından, kuluçkalık yumurtalar için önemli bir özellik olan şekil indeksinin de her 2 genotip de önemli bir farklılık göstermemesi bu genotiplerde anormal şekilli yumurtaların görülmediğini ortaya çıkarmıştır. Ancak anormal şekilde yumurtaların görülmemesine rağmen her iki genotip de doğal gurktaki kuluçka randımanındaki önemli farklılık Linda kazlarının önemli düzeyde doğal gurku tercih etmelerinden kaynaklanmıştır.

Bu çalışmada, kuluçkalık yumurta özellikleri açısından, her iki genotipte de kuluçkalık özellikleri taşımayan yumurtalar tespit edilmemiştir. Gerek Yerli kazların doğal kuluçkasında gerekse Linda yumurtalarının makine kuluçkasında kuluçka randımanı %78-90 arasında bulunmuş olup, oldukça ideal sayılabilir.

Türkiye'de kaz varlığının ne kadarının Yerli kazlardan oluştuğu bilinmemekle birlikte bu oranın gittikçe azaldığı düşünülmektedir. Yerli kazların yumurta veriminin düşük olmasına (Gönül ve ark., 1995) karşılık, yabancı kaz özelliğini koruması ve doğal kuluçkaya yatma eğilimlerinin fazla olması onları korunması gereken endemik bir tür yapmaktadır. Ancak, Yerli kazların doğal kuluçkaya yatma eğilimlerinin yüksek olması nedeni ile yumurta veriminin düşük olduğunu ifade eden araştırmacılar da vardır (Arslan ve Saatçi, 2003). Linda kazları ile Yerli kazların yumurta özellikleri karşılaştırıldığında, Yerli kazların yumurta ağırlığı ve bazı kalite özellikleri bakımından daha iyi durumda olduğu görülmektedir (Tablo 2). Ancak, Linda kazları, bir yumurtlama periyodunda daha fazla yumurta verdiği (40 adet/yıl) ve makinede daha yüksek kuluçka randımanı (%78) gösterdiği için daha fazla rağbet görmektedir.

Sonuç

Yerli kazlar, Linda kazına oranla daha büyük ve daha kaliteli yumurtalar vermelerine rağmen, yılda ürettikleri yumurta sayısı bakımından Linda kazlarına göre oldukça geridedir. Bu nedenle, yapılacak seleksiyon çalışmaları ile Yerli kazlarımızın yumurta verimlerinin artırılması büyük önem taşımaktadır. Ancak, Yerli kazlar, doğal kuluçka özelliklerini kaybetmemiş olmaları nedeniyle, küçük çaplı yetiştiricilerin kuluçka makinesine ihtiyaç duymadan palaz üretmelerini mümkün kılmaktadır. Bunun dışında, Yerli kazlar kuluçka esnasında yumurtalarını koruma ve sahip çıkma özelliği, annelik vasfı, eş sadakati ve kuluçka süresi boyunca gerekli olmadığı sürece folluğu terk etmeme gibi birtakım arzu edilen özelliklere de sahiptirler. Kültür ırkı kazlarda, doğal kuluçka özelliği, yumurta veriminin artırılması amacıyla yapılan seleksiyonlarla giderek azalmış ve hatta bazılarında tamamen kaybolmuş durumdadır. Bu nedenle, büyük entansif işletmeler dışındaki küçük aile işletmeleri için Linda kazı yerine Yerli genotiplerin yetiştirilmesinin daha uygun olacağı söylenilebilir. Sonuç olarak, Yerli kaz genotiplerimizin ülkemiz için önemli bir değer olduğu ve korunması gerektiği kanaatine varılmıştır.

Çıkar çatışması

Yazarlar bu yazı için gerçek, potansiyel veya algılanan çıkar çatışması olmadığını beyan etmişlerdir.

Etik izin

Bu çalışma için HRU-HADYEK-2020/001-01/07 numara ile izin alınmıştır. Ayrıca yazarlar Araştırma ve Yayın Etiğine uyulduğunu beyan etmişlerdir.

Finansal destek

Bu çalışma, HUBAB tarafından HUBAB-D6-20052 proje numarası ile desteklenmiştir.

Benzerlik Oranı

Makalenin benzerlik oranının sisteme yüklenen raporda belirtildiği gibi kaynaklar hariç %3 olduğunu beyan ederiz.

Yazar Katkıları

Fikir/Kavram: SY, ZK

Tasarım: SY

Denetleme/Danışmanlık: SY, ZK, MÇ,

Veri Toplama ve/veya İşleme: ZK

Analiz ve/veya Yorum: SY, MÇ

Kaynak Taraması: SY, MÇ

Makalenin Yazımı: SY

Eleştirel İnceleme: MÇ

Kaynaklar

- Anonim, 1987: Tarım Bakanlığı: Kars, Erzurum, Ağrı illeri Kaz Yetiştiriciliğini Geliştirme Projesi. Tarım Bakanlığı, Proje ve Uygulama Genel Müdürlüğü, Ankara, Türkiye.
- Arroyo CL, 1990: Specific gravity, weight, and the percentage of shell, white and yolk in goose eggs. *Agronomia Costarricense*, 14 (1),99-102.
- Arslan C, Saatçi M, 2003: Egg yield and hatching characteristics of local Kars geese. *Turk J Vet Anim Sci*, 27, 1361-1365.
- Biesiada-Drzazga B, Banaszewska D, Koncerewicz A, Jozwik A, Horbanczuk J, 2015: Examination of changes in selected external and internal egg traits during the geese laying season and their effect on gosling hatching results. *Eur Poult Sci*, 79, 1-11.
- Dawson RD, Clark RG, 2000: Effects of hatching date and egg size on growth, recruitment and adult size of lesser scaup. *The Condor*, 102, 930- 935.
- Kucharska-Gaca J, Adamski M, Biesek J, 2022: Effect of parent flock age on hatching, growth rate, and features of both sexes goose carcasses. *Poult Sci*, 101: 101920

- El-Hanoun AM, Attia YA, AL-Harhi MA, Habiba HI, Oliveira MC, 2017a: Magnetized drinking water improves productivity and blood parameters in geese. *Rev Colomb Cienc Pecu*, 30, 209-218.
- El-Hanoun AM, Attia YA, Gad HAM, Abdella MM, 2012: Effect of different managerial systems on productive and reproductive traits, blood plasma hormones and biochemical constituents of geese. *Animal*, 6 (11), 1795-1802.
- El-Hanoun AM, Wesam AF, Attia YA. 2017b: Effect of magnetized wall water on Blood components, Immune indices and Semen quality of Egyptian male geese. *Egypt Poult Sci*, 37 (I), 91-103.
- Gönül T, Yücelyigit E, Aksu M, Kapucu A, 1995: Kars goose production station inspection report. *Turkish Development Foundation*. Ankara, Türkiye.
- Kaya Z, Yurtseven S, 2021: Effects of feeding systems on yield and performance of Linda geese *Anserinae sp.* in hot climatic conditions. *S Afr J Anim Sci*, 51 (5), 628-634.
- Liu HW, Zhou DW, 2013: Influence of pasture intake on meat quality, lipid oxidation, and fatty acid composition of geese. *J Anim Sci*, 91, 764-771.
- Guo B, Li D, Zhou B, Jiang Y, Bai H, Zhang Y, Xu Q, Yongzhang, Chen G, 2020: Effect of diet with different proportions of ryegrass on breast meat quality of broiler geese. *Poult Sci*, 99 (5), 2500-2507.
- Orhan H, Erensayın C, Aktan S, 2001: Japon bıldırcınlarında (*Coturnix coturnix japonica*) farklı yaş gruplarında yumurta kalite özelliklerinin belirlenmesi. *Hayvansal Üretim*, 42 (1), 44-49.
- Reuter YS, 2012: State and the main directions of work with the Lindsovlike geese. XVII International Conference, WPSA, Innovative Developments and Their Development in Industrial Poultry Farming P. 95-97; Sergiev Posad, Russia.
- Saatci M, Kırmızıbayrak T, Aksoy AR, Tilki M, 2005: Egg weight, shape index and hatching weight and interrelationships among these traits in Native Turkish geese with different coloured feathers. *Turk J Vet Anim Sci*, 29, 353-357.
- Sarı M, Buğdaycı KE, Akbaş AA, Saatci M, Oğuz MN, 2019: The effect of laying period on egg quality traits and chemical composition of Lindovskaya Linda geese reared under breeder conditions. *Turk J Vet Anim Sci*, 43, 662-669.
- Tilki M, İnal Ş, 2004: Quality traits of goose eggs. 1. Effects of goose age and storage time of eggs. *Eur Poult Sci*, 68, 182-186.
- Tserveni-Goussi A, Fortomaris P, 2011: Production and quality of quail, pheasant, goose and turkey eggs for uses other than human consumption. Improving the Safety and Quality of Eggs and Egg Products. *Woodhead Publishing Series in Food Science, Technology and Nutrition*, 509-537.
- TÜİK, 2022: Turkey Statistical Institute. <https://data.tuik.gov.tr/Bulten/Index?p=Hayvansal-%C3%9Cretim-%C4%B0statistikleri-Aral%C4%B1k-2021-45593&dil>, Erişim tarihi: 15.11.2022.



Morphological Comparison of Larynx, Syrinx and Trachea of Some Wild Birds

Funda AKSÜNGER KARAAVCI^{1,a,*}, Ali KOÇYİĞİT^{2,b}, Betül KANİK^{3,c}

¹Bingol University, Faculty of Veterinary Medicine,
Department of Anatomy, Bingol, Turkey.

²Harran University, Laboratory and Veterinary Health
Vocational School, Sanliurfa, Turkey.

³Ondokuz Mayıs University Graduate School of Education
Department of Veterinary Anatomy, Samsun, Turkey.

^aORCID: 0000-0001-8311-1723;

^bORCID: 0000-0002-9354-7480;

^cORCID: 0000-0001-7740-2268.

Received: 28.02.2024

Accepted: 20.05.2024

How to cite this article: Aksünger Karaavci F, Koçyiğit A,
Kanik B. (2024). Morphological Comparison of Larynx,
Syrinx, Trachea of Some Wild Birds. Harran Üniversitesi
Veteriner Fakültesi Dergisi, 13(1): 48-55.

DOI:10.31196/huvfd.1444521.

***Correspondence:** Funda AKSÜNGER KARAAVCI

¹Bingol University, Faculty of Veterinary Medicine,
Department of Anatomy, Bingol, Turkey
e-mail: fakaraavci@bingol.edu.tr

Available on-line at: <https://dergipark.org.tr/tr/pub/huvfd>

Abstract: The presence of both the larynx and syrinx in the respiratory system, the trachea consisting of long and complete cartilage rings, and the presence of air sacs are some of the important features that distinguish birds from mammals. There have been many studies on the larynx, trachea and syrinx as they are the distinguishing features of song and bird vocalizations in many avian species. In the present study, the purpose was to demonstrate the morphological structures of the larynx, trachea and syrinx, which is a sound organ, pigeon, sparrowhawk, falcon, eagle, goose, crow and stork. A total of 48 specimens, were used in the study. The materials were stained with methylene blue for better observation and counting of the tracheal rings. The staining procedure was performed by soaking the materials in alcohol, methylene blue solution and alcohol solutions of different concentrations, respectively. It was observed that the tracheal cartilages were a complete ring in all study species, but there were differences in tracheal length, number of cartilages and dorsoventral flattening. Syrinx was found to be tracheal type in storks and tracheobronchial type in others. As a result, the similarities and differences of the data obtained from pigeon, falcon, sparrowhawk, eagle, crow, goose and stork on larynx, trachea and syrinx due to different hunting, singing and vocal characteristics were revealed.

Keywords: Avian, Larynx, Macro-anatomy, Syrinx, Trachea.

Bazı Yabani Kuşların Larinks, Syrinx ve Trakealarının Morfolojik Karşılaştırması

Özet: Kanatlıları memelilerden ayıran önemli özelliklerden bazıları solunum sisteminde hem larinks hem de syrinx'in bulunması, trakeanın uzun ve tam kıkırdak halkalardan oluşması ve hava keselerinin varlığıdır. Ötüş ve kuş seslerinin kanatlılar için ayırt edici özellikler arasında yer alması bakımından birçok kuş türünde larinks, trakea ve syrinx üzerine birçok çalışma yapılmıştır. Bu çalışmada güvercin, atmaca, şahin, kartal, kaz, karga ve leylek türlerinde larinks, trake ve bir ses organı olan syrinx'in morfolojik yapılarının ortaya konulması amaçlanmıştır. Çalışmada toplam 48 örnek kullanıldı. Trakeal halkaların daha iyi gözlemlenebilmesi ve sayılabilmesi için materyaller metilen mavisi ile boyandı. Bu amaçla materyaller önce %70'lik alkolde iki saat bekletildi, distile su ile yıkandı, %0,1'lik metilen mavisi solüsyonunda 15 dakika bekletildikten sonra %50'lik ve %70'lik alkol solüsyonlarında birer saat bekletildi. Çalışılan tüm türlerde trakeal kıkırdakların tam bir halka olduğu, ancak trakeal uzunluk, kıkırdak sayısı ve dorsoventral düzleşme açısından farklılıklar olduğu gözlemlenmiştir. Syrinx leyleklerde trakeal tipte, diğerlerinde ise trakeobronşiyal tipte bulunmuştur. Sonuç olarak güvercin, şahin, atmaca, kartal, karga, kaz ve leylekten elde edilen verilerin farklı avlanma, ötme ve vokal özelliklerine bağlı olarak larinks, trake ve syrinx üzerindeki benzerlik ve farklılıkları ortaya konmuştur.

Anahtar Kelimeler: Gırtlak, Kanatlı, , Makro-anatomi, Sirenks, Soluk borusu.

Introduction

The respiratory system mainly provides in gas exchange, but also plays a role in thermoregulation of body temperature and helps to produce sound (Al-Mahmodi, 2012; Fedde, 1998). The respiratory system in avian is similar in function to other vertebrates but is more developed. There are many differences in the respiratory system organs of birds compared to mammals due to the workload caused by flight requirements, sound production and the desire to move (Heard, 1997; König et al., 2016; Nickel et al., 1977). The presence of both the larynx and syrinx in the respiratory system, the trachea consisting of long and complete cartilage rings, and the presence of air sacs are some of the important features that distinguish birds from mammals (Çalışlar, 1977; König et al., 2016; Nickel et al., 1977).

In avians, the larynx is formed by two single cartilago (cart.) cricoidea and cart. procricoidea and two paired cartilago arytenoidea (Al-Mussawy et al., 2012; Getty, 1975; King and McLelland, 1984; Öcal and Erden, 2002). Between the cart. arytenoidea is a narrow slit called the glottis. This cartilage regulates the opening of the glottis through the muscles and is involved in the regulation of the voice (King and McLelland, 1984).

The trachea connects the larynx to the syrinx and its length varies depending on the length of the neck in avian (Getty, 1975; Kabak et al., 2007; Öcal and Erden, 2002; Taşbaş et al., 1994). The most important difference between the trachea, which consists of cartilages called cartilago trachealis, from mammals is the complete presence of cartilage rings (Getty, 1975; Gündemir and Alpak, 2020; Yılmaz et al., 2016).

Syrinx is the organ that produces sound in birds (Casteleyn et al., 2018; Dewi et al., 2023). There are 3 basic syrinx types according to its topographic location. These are classified as tracheobronchial, tracheal, and bronchial type. Tracheobronchial type syrinx is the most common type in avian (Baumel et al., 1993; Evans, 2016; Ibrahim et al., 2020). In female avians, territorial marking and recognition of family members are of great importance for the socialization of offspring and the attraction of mating partners in males (Casteleyn et al., 2018; Eens and Gorissen, 2005).

There have been many studies on the larynx, trachea and syrinx as they are the distinguishing features of song and bird vocalizations in many avian species. In the present study, the purpose was to demonstrate the morphological structures of the larynx, trachea and syrinx, which is a sound organ, pigeon, sparrowhawk, falcon, eagle, goose, crow and stork.

Materials and Methods

A total of 48 specimens were used in the study. In terms of using animals found dead in nature, the study is not subject to ethical approval. Approval document was received from Bingöl University HADYEK with E-85680299-020-143158 dated 02.02.2024. The study samples were pigeon (*Columbia livia*) (Female(F):10, Male(M):10), goose (*Anser anser*) (F:3, M:5), sparrowhawk (*Accipiter nisus*) (F:3, M:4),

falcon (*Falco peregrinus*) (M:1), eagle (*Aquila chrysaetos*) (F:1, M:2), crow (*Corvus corax*) (F:4, M:3) and stork (*Ciconia ciconia*) (F:1, M:1). Dissection was performed according to the dissection technique of Calislar (1977), and the topographic features of the larynx cranialis, trachea and syrinx were recorded. These sections were then removed completely. Excess tissues were dissected. The dorsoventral (DV) and laterolateral (LL) diameters of the tracheal cartilages at the upper-middle-lower 1/3 distances and the length of the trachea were measured with a digital caliper. The materials were stained with methylene blue for better observation and counting of the tracheal rings. For this purpose, the materials were first kept in 70% alcohol for 2 hours, washed with distilled water, kept in 0.1% methylene blue solution for 15 minutes and then kept in 50% and 70% alcohol solutions for 1 hour each. The papillae in the mons laryngealis of the stained materials were counted. The tissues on the larynx cartilages were removed and the cartilage structure was analyzed. Tracheal cartilages were counted and the structure of the syrinx was examined. Anatomical terms were used according to Nomina Anatomica Avium (Baumel et al., 1993).

Results

In all materials examined, the mons laryngealis was observed as a mound on the caudal part of the tongue and at the base of the pharynx (Figures 1 and 2). It was determined that the length of the glottis located above the mons laryngealis and the sulcus laryngealis located just behind the glottis varied according to the species (Table 1). Anatomical results showed that the larynx was similar in structure and position in the species studied. Cartilago laryngealis consisted of single cartilago cricoidea, cartilago procricoidea and paired cartilago arytenoidea. Papillae on the mons laryngealis, which vertically delimit the sulcus laryngealis, were absent in pigeons and stork, but present in other species. In the species examined, the transversal papillae showed different arrangements as single row, two rows, three rows and scattered. In pigeons with single row arrangement, there were 24.7 ± 1.49 papillae in females and 26.2 ± 2.52 papillae in males. In falcon, rostrotransversal papillae (26) and caudotransversal papillae (9) arrangement was observed. In eagles and sparrowhawks, transversal papillae were arranged in 3 (rostral, middle and caudal) rows from front to back. In eagles, the number of papillae in the anterior, middle and posterior arrangement was higher in both sexes than in sparrowhawks. In crows, geese and storks, transversal papillae were scattered. In the crow and goose, they were scattered over the entire mons laryngealis, while in the stork, several papillae were found on the caudal border of the mons laryngealis. The mean standard deviation values of the number of papillae according to species and sex are given in Table 2.

The trachea was found to start behind the cartilago cricoidea and continue to the bifurcatio trachea in the stork, and to the syrinx in other species. The trachea was composed

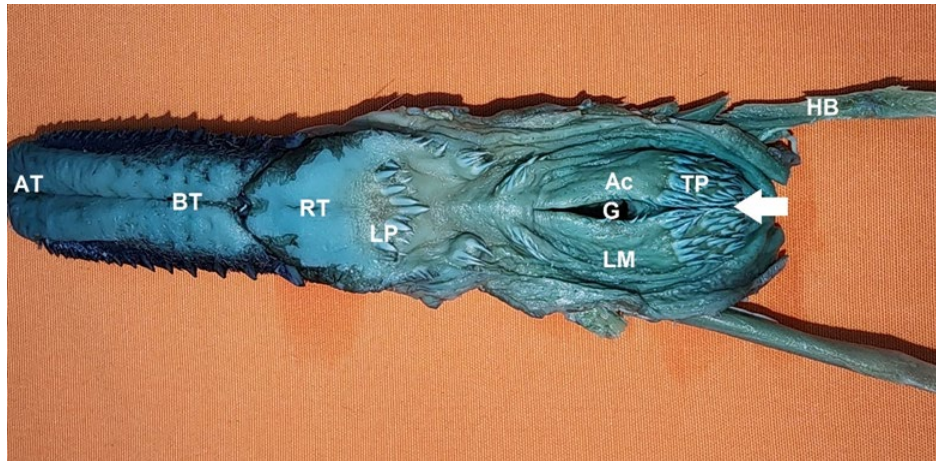


Figure 1. Topography showed location of the larynx in goose, Hyoid bone (HB), at the base of tongue, (AT) Apex of Tongue, (BT) Body of Tongue, (RT) Root of Tongue, (G) Glottis, (LM) Laryngeal Mound, (LP), Laryngeal Papilla, (Ac) Arytenoid cartilage, (white arrow) Sulcus laryngealis.

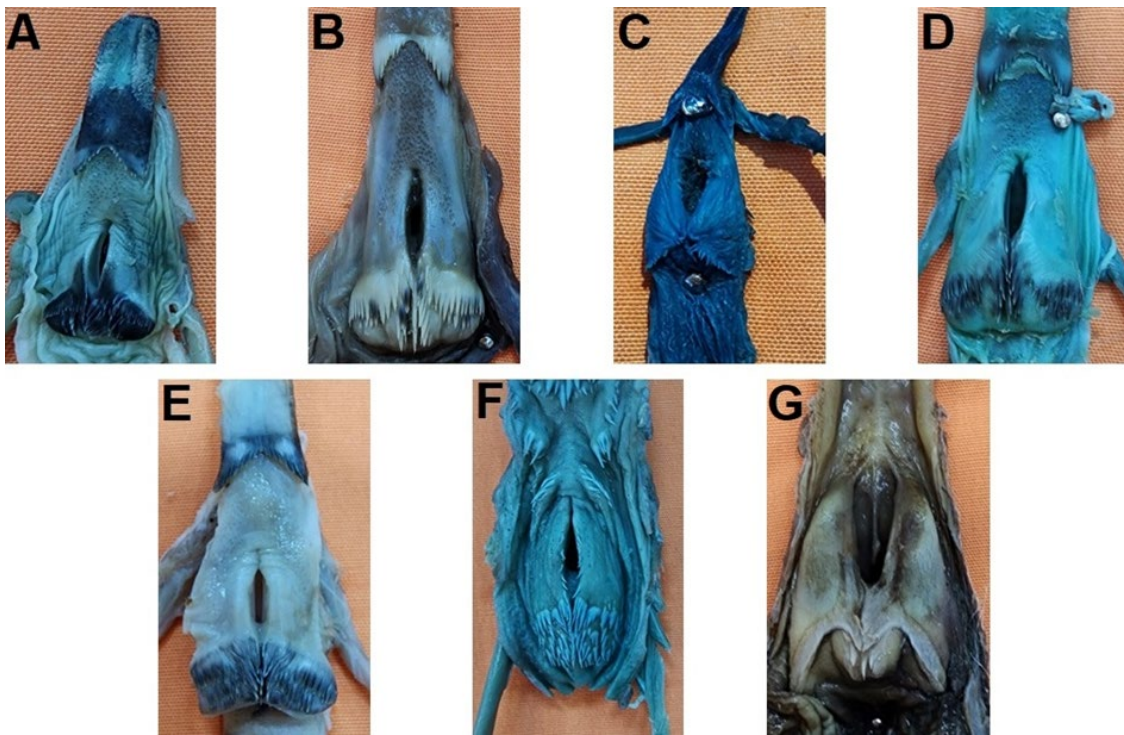


Figure 2. Larynx and papillae by species, (A) Sparrowhawk, (B) Falcon, (C) Pigeon, (D) Crow, (E) Eagle, (F) Goose, (G) Stork.

Table 1. Glottis and sulcus laryngealis length by species and sex.

Species	Glottis length		Sulcus laryngealis length	
	Female	Male	Female	Male
Pigeon	7.13±0.19	6.98±0.52	3.28±0.43	3.12±0.26
Goose	13.62±0.97	15.10±0.58	9.15±0.52	9.10±0.65
Crow	7.24±0.55	6.92±0.67	4.98±0.65	4.12±0.53
Stork	14.67*	13.02*	7.14*	6.12*
Sparrowhawk	4.47±0.54	5.83±0.44	3.12±0.14	3.27±0.53
Eagle	8.85*	7.84±0.17	6.04*	5.55±0.08
Falcon	-	7.31*	-	4.51*

Table 2. Papillae arrangement and number "n"

Species	Sex	Papillae arrangement and number			
		Vertical	Transversal		
Pigeon	Female	-	Single row (n) 24.7±1.49		
	Male	-	26.2±2.52		
Falcon			Two rows Rostrotransversal		Caudotransversal
	Male	18	26		9
Eagle	Female	18	Three rows (n) Rostral	Middle	Caudal
	Male	16.5±2.5	28.5±0.5	17	14
Sparrowhawk	Female	11	24	17.5±1.5	11.5±0.5
	Male	13	25	12.5	7
Crow	Female	19	Messy 20.75±0.82		
	Male	17	20.33±0.47		
Goose	Female	26	32.33±1.24		
	Male	25	31.6±1.01		
Stork	Female	-	5		
	Male	-	4		

of ring-shaped cartilago trachealis. At the beginning of the neck region, the trachea was located ventral to the esophagus, and then the trachea remained on the left due to the transition of the esophagus to the right. At the entrance of the thoracic region, the trachea was found to be in the ventro-median position again. It was determined that the trachea had different lengths depending on the length of the neck in birds. While the length of the trachea was longer in the female goose than in the male stork, the number of tracheal cartilages was higher in the male stork. Similarly, while the length of the trachea was less in the female eagle than in the male pigeon, the number of tracheal cartilages was higher in the female pigeon. This is thought to be due to the different thicknesses of the tracheal cartilages in the analyzed species (Table 3). The longest trachea was 266.40±4.22 mm in male goose, dorsoventral and laterolateral diameters of cartilago trachealis removed from the upper-middle and lower 1/3 levels of the trachea were different according to the species (Table 4, Figure 3). Cartilago trachealis was found to be dorsoventrally flattened in the upper 1/3 in all species. When DV/LL ratios were analyzed, it was found that dorsoventral flattening was highest in female eagles and lowest in female geese. In the middle 1/3, dorsoventral flattening increased in male falcon and female-male crows, decreased in both sexes in pigeons, storks and eagles, and cartilago trachealis became closer to the circle in sparrowhawks and geese. According to the data obtained from the lower 1/3, it was determined that the cartilago trachealis approached a circle in all species except the sparrowhawk. In sparrowhawks, it was determined that there was a decrease in the degree of dorsoventral flattening compared to the upper 1/3, but the cartilages close to the circle were located in the middle 1/3.

Syrinx was observed to be tracheobronchial type in all species except stork. In the stork, tracheal type syrinx was present. In the stork, 10-11 tracheal rings were located after the syrinx formation and then the bifurcatio trachealis was formed (Figure 4). In geese, the tympanum was shaped like a tube with fusion and ossification of 4-5 cartilages. In other species, the tympanum was shaped by cartilages that were separate from each other in the membrana tympanium lateralis and not a complete ring. It consisted of 3 cartilages in pigeons, 3-4 in falcon and eagles, 3-5 in crows, 4-5 in sparrowhawks and 5-6 in storks. It was determined that bronchus primarius merged from their medial walls at the level of the bifurcatio trachea and formed the pessulus. It was also determined that the first of the bronchosyringeal cartilages extended towards the pessula and connected (Figure 5).

Discussion and Conclusion

Mons laryngealis was reported to have a heart-shaped mound in owls (Demirkan and Özdemir, 2011) and gulls (Ince and Pazvant, 2010), a heart-shaped mound in red hawks (Kabak et al., 2007), Gerze roosters and hens (Onuk et al., 2015), and a heart-shaped mound in Asel roosters and hens (Yılmaz et al., 2016). Similarly, in this study, a heart-shaped hump was found in falcon, sparrowhawks, pigeons, crows and eagles. In geese (Onuk et al., 2010), it was reported to be seen as a hump. In the geese examined, it was observed that the mons laryngealis was an elliptical hump. In the stork, due to the wider glottis, the mons laryngealis had a similar appearance to the right and left lungs, forming a different hump shape from the others.

Table 3. Tracheal measurement length (mm) and number of cartilago trachealis by species and sex.

Species	Sex	Length (mm)	Tracheal cartilage (n)
Pigeon	Female	100.91±5.34	92±6.00
	Male	136.78±5.87	113.40±7.67
Goose	Female	256.33±2.62	136.66±1.69
	Male	266.40±4.22	141.40±2.72
Crow	Female	95.60±3.50	91.25±3.76
	Male	94.50±2.44	90.25±2.41
Stork	Female	255.44	143
	Male	250.32	141
Sparrowhawk	Female	76.10±1.56	76.66±0.69
	Male	86.12±2.11	84.40±3.22
Eagle	Female	132.81	114
	Male	129.19±3.62	102.5±0.5
Falcon	Male	120.65	103

Table 4. Tracheal diamater (mm).

Species	Sex	Diamater					
		Upper 1/3		Middle 1/3		Lower 1/3	
		DV	LL	DV	LL	DV	LL
Pigeon	Female	3.75±0.79	7.01±0.67	3.20±0.76	6.02±0.54	4.63±0.45	7.21±0.56
	Male	4.02±0.96	7.77±0.63	3.86±0.54	7.04±0.85	5.83±0.48	7.65±0.12
Goose	Female	8.69±1.12	9.26±2.02	9.20±1.26	10.97±1.92	9.78±2.23	10.05±2.41
	Male	8.71±0.78	9.35±0.43	9.45±0.37	11.12±0.45	10.05±0.61	10.63±0.09
Crow	Female	3.72±1.15	6.14±0.91	3.63±0.75	5.68±0.26	4.10±0.62	5.12±1.31
	Male	3.72±0.88	6.08±0.93	3.58±0.37	5.71±0.21	4.26±0.43	5.23±1.30
Stork	Female	6.52	13.10	7.29	12.52	8.36	11.40
	Male	6.46	12.95	7.05	12.44	8.18	11.25
Sparrowhawk	Female	3.05±0.56	4.62±0.29	2.97±0.07	3.24±0.11	2.22±0.37	2.96±0.33
	Male	3.15±0.42	4.78±0.12	3.10±0.17	3.46±0.23	2.36±0.32	3.02±0.21
Eagle	Female	3.81	7.85	4.02	6.43	4.68	5.74
	Male	4.16±1.64	7.73±1.21	4.17±1.46	6.53±1.21	4.65±1.75	6.12±1.45
Falcon	Male	4.74	8.62	4.76	8.25	5.65	5.54




Figure 3. Tracheal cartilage by species, (A) Tracheal cartilage and diameter schematized, (DV) Dorso-Ventral, (LL) Latero-Lateral, (B) Sparrowhawk, (C) Falcon, (D) Pigeon, (E) Crow, (F) Eagle, (G) Goose, (H) Stork.

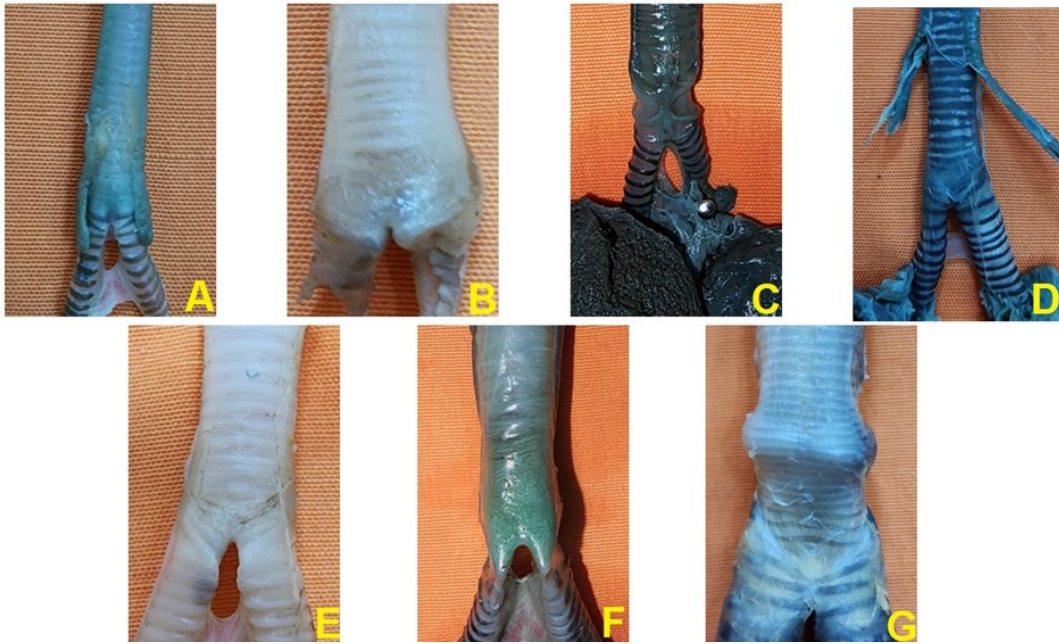


Figure 4. Syrinx by species, (A) Sparrowhawk, (B) Falcon, (C) Pigeon, (D) Crow, (E) Eagle, (F) Goose, (G) Stork.



Figure 5. Dorsal view of the syrinx in the male Sparrowhawk. (1) trachea, (2) sternotracheal muscle, (3) tympanum, (4) interbronchial foramen, (5) interbronchial ligament.

The presence of backward-facing papillae on both sides of the glottis has been reported in the Denizli cock (Taşbaş et al., 1994), Japanese quail (Çevik-Demirkan et al., 2007) and geese (Onuk et al., 2010). Among the species analyzed in this study, it was observed that it was prominently present in geese and crows and as papillae with smaller sizes in pigeons. These papillae were reported in turkeys (Getty, 1975), red hawks (Kabak et al., 2007), aseel roosters and hens (Yılmaz et al., 2016) and gulls (İnce and Pazvant, 2010), but not in storks, falcons, sparrowhawk and eagles.

In the red hawk (Kabak et al., 2007), goose (Onuk et al., 2010), Gerze rooster and hen (Onuk et al., 2015), gull (İnce and Pazvant, 2010), penguin (Taşbaş et al., 1986), and sparrowhawk (Toprak et al., 2016), a medial row of papillae in the sulcus laryngealis was reported. In this study, it was

observed that medial papillae were present in all species except pigeons and stork, similar to the literature. In pigeon and stork, no medial papilla row was found in accordance with the data of Yılmaz et al., (2016).

As in many avian species (Baumel et al., 1993; Çevik-Demirkan et al., 2007; İnce and Pazvant, 2010; Onuk et al., 2015; Yılmaz et al., 2016), it was observed that the larynx was formed from the single cart. cricoidea and cart. procricoidea and the paired cart. arytenoidea in all species examined in this study.

In avian, the length of the trachea and the number of rings vary depending on the length of the neck (Heard, 1997; Nickel et al., 1977; Öcal and Erden, 2002; Taşbaş et al., 1994). It was reported to be 188.33 ± 7.63 mm in male ducks and 171.00 ± 3.60 mm in female ducks (Al-Ahmed and Sadoon,

2020), 4.05 cm in quail (Rajathi et al., 2009), 12-13 cm in owls (Demirkan et al., 2011), 8.13 cm in pigeon (Hena et al., 2012), 17.1-22.2 cm in cock (Taşbaş et al., 1994). According to the tracheal length data in pigeons, crows, sparrowhawks, eagles and falcon examined in the study, it is the shortest in female sparrowhawks with 76.10 ± 1.56 mm and the longest in male pigeons with 136.78 ± 5.87 mm, and the data vary according to the species in this range. In storks and geese, the length of trachea was found to be over 250 mm.

It has been stated that the trachea in avian generally consists of 108-126 cartilages (Getty, 1975). It has also been reported that the number is 30-40 in small songbirds and up to 350 in flamingos and cranes (Heard, 1977). It was reported that there were 53-57 cartilago trachealis in magpie (Balkaya et al. 2016), 115-134 cartilago trachealis in gulls (İnce and Pazvant, 2010), 129.66 ± 2.51 and 137.66 ± 2.51 cartilago trachealis in male and female ducks (Al-Ahmed and Sadoon, 2020), 100-130 cartilago trachealis in poultry (Nikel et al., 1977), 117-140 cartilago trachealis in geese (Onuk et al., 2010). In the species analyzed in this study, the number of cartilages varied between 76-143 depending on the species.

It has been reported that the trachea in peacocks is cylindrical and its diameter is the largest in the middle 1/3 and the diameter decreases as it approaches the syrinx (Al-Araji and Mohammed, 2023). It has also been reported that the transversal cross-sectional surface of the tracheal cartilages is round in many species, while it is dorsoventrally flattened in parrots, day-hunting birds and storks (Heard, 1977; King and McLelland, 1984). Yılmaz et al. (2016) reported that it was dorsoventrally flattened in aeseel chickens and roosters at the beginning, became cylindrical by decreasing the diameters in the middle and turned into an oval shape in the last part. In the species examined, it was observed that the tracheal rings were dorsoventrally flattened in the initial part except for the sparrowhawk, while they were more cylindrical in sparrowhawks. In addition, it was determined that the cartilages of the trachea, which started as dorsoventrally flattened, continued to be flattened in pigeons as they approached the syrinx, while the cartilages became rounded in other species.

The structure of the syrinx has been analyzed in many avian species. The most common syrinx type is tracheobronchial type. Peking duck (Mohamed, 2017), aeseel roosters and chickens (Yılmaz et al., 2016), budgerigars and canaries (Gündemir and Alpak, 2020), male mallard duck (Frank et al., 2007), goose (Onuk et al., 2010), peacock (Al-Araji and Mohammed, 2023) ostrich (Chiappone et al., 2024), and partridge (*Alectoris chukar*) and Japanese quail (Kara et al., 2023) are among the poultry species showing tracheobronchial type syrinx. Oliveria et al. (2023), observed that the histological characteristics of syringes classify them as tracheal type in the White-eyed parakeet and tracheobronchial type in the red-winged tinamou and red-legged seriema. In this study, tracheobronchial type syrinx was observed in sparrowhawks, eagles, falcon, pigeons, geese and crows for both sexes similar to the literature. Casey and Gaunt (1985) reported that tracheal syrinx is mainly found in Furnarioidea (ovenbirds) and some

Ciconiidae (storks). The tracheal syrinx of male and female storks in this study is similar to the literature.

As a result, the similarities and differences of the data obtained from pigeon, falcon, sparrowhawk, eagle, crow, goose and stork on larynx, trachea and syrinx due to different hunting, singing and vocal characteristics were revealed.

Conflict of Interest

The authors stated that they did not have any real, potential, or perceived conflict of interest.

Funding

This work has received no financial support.

Similarity Rate

We declare that the similarity rate of the article is %10 as stated in the report uploaded to the system.

Author Contributions

Motivation / Concept: FAK

Design: FAK, AK

Control/Supervision: FAK, AK

Data Collection and/or Processing: AK, BK

Analysis and Interpretation: FAK, BK

Literature Review: FAK, BK

Writing of the Article: FAK, AK

Critical Review: FAK, AK, BK

References

- AL-Ahmed AS, Sadoon AH, 2020: Comparative Anatomical, Histological and Histochemical Study of (Larynx, Trachea and Syrinx) Between mature and immature males of local duck (*Anas platyrhynchos*). *Basra J Vet Res*, 19(1), 10-34.
- AL-Araji HM, Mohammed HH, 2023: Comparative Anatomical Study of The Trachea in Adult Male and Female Indigenous Peafowl (*Pavo Cristatus*). *Ann For Res*, 66(1), 1149-1157.
- AL-Mahmodi AM, 2012: Macroscopic and morphometric studies of the extra pulmonary primary bronchi and lungs of the indigenous adult male pigeon (*Columba domestica*). *Kufa J Vet Med Sci*, 3(1), 19-26.
- AL-Mussawy AM, AL-Mehanna NH, AL-Baghdady EF, 2012: Anatomical study of the larynx indigenous male turkey (*Meleagris gallopava*). *ALQadisiya J Vet Med Sci*, 11(1), 122-132.
- Balkaya H, Ozudoğru Z, Ozdemir D, Erbas E, Kara H, 2016: Saksığanda (*Pica pica*) larynx ve trachea üzerinde anatomik ve histolojik bir çalışma. *Harran Univ Vet Fak Derg*, 5, 44-49.
- Baumel JJ, King SA, Breazile JE, Evans HE, Berge JCV, 1993: Handbook of Avian Anatomy: Nomina Anatomica Avium, Second edition, Published by the Nuttall Ornithological Club Cambridge, pp. 257-299.
- Casey RM, Gaunt AS, 1985: Theoretical models of the avian syrinx. *J Theor Biol*, 116(1), 45-64.
- Casteleyn C, Cornillie P, Van Cruchten S, Van den Broeck W, Van Ginneken C, Simoens P, 2018: Anatomy of the upper

- respiratory tract in domestic birds, with emphasis on vocalization. *Anat Histol Embryol*, 47(2), 100–109.
- Chiappone M, Rodriguez-Saltos C, Legendre LJ, Li Z, Clarke J, 2024: Ostrich (*Struthio camelus*) syrinx morphology and vocal repertoire across postnatal ontogeny and sex: Implications for understanding vocal evolution in birds. *J Anat*, 244(4), 541-556.
- Çalışlar T, 1977: Tavuk Diseksiyonu. Ankara Üniversitesi Basımevi. Ankara, Turkey, 28-31.
- Çevik Demirkan A, Hazıroğlu RM, Kürtül I, 2007: Gross morphological and histological features of larynx, trachea and syrinx in japanese quail. *Anat Histol Embryol* 36(3), 215-219.
- Demirkan AÇ, Özdemir V, 2011: A Study on anatomical structures of the larynx, trachea and syrinx in Eurasian Eagle Owl (*Bubo bubo*). *J Anim Vet Adv* 10(24), 3218-3224.
- Dewi CMS, Dhamayanti Y, Fikri F, Purnomo A, Khairani S, Chhetri S, Purnama MTE, 2023: An investigation of syrinx morphometry and sound frequency association during the chirping period in lovebirds (*Agapornis fischeri*). *F1000Research*, 11, 354.
- Eens M, Gorissen L, 2005: Complex female vocal behaviour of great and blue tits inside the nesting cavity. *Behaviour*, 142(4), 489–506.
- Evans HE, 2016: Avian anatomy. In I. J. Lovette & J. W. Fitzpatrick (Eds.), *Handbook of bird biology* (3rd ed., pp. 169–213). The Cornell Lab of Ornithology, Wiley.
- Fedde MR, 1998: Relationship of structure and function of the avian respiratory system to disease susceptibility. *Poult Sci* 77, 1130 – 1138.
- Frank T, Probst A, König HE, Walter I, 2007: The syrinx of the male mallard (*anas platyrhynchos*) special anatomical features. *Anat Histol Embryol*, 36(2), 121- 126.
- Getty R, 1975: *Sisson and Grossman's the Anatomy of the Domestic Animals*, 5 ed, Vol.2. London, UK: W.B. Saunders Company pp. 1891-1902.
- Gündemir O, Alpak H 2020: Macroanatomic and histological examination of the trachea and syrinx in budgerigars and canaries. *Harran Üniv Vet Fak Derg*, 9(1), 19-23.
- Heard DJ, 1997: Avian respiratory and physiology. *Seminars avian exotic pet med*, 6(4), 172-179.
- Hena SA, Sonfada ML, Bello A, Danmaigoro A, Tanimomo BK, 2012: Comparative morphologic and morphometric studies on the lower respiratory tract of adult Japanese quail (*coturnix japonica*) and pigeon (*Columbia livia*). *J Biol Sci* 1(2), 37-42.
- İbrahim IA, Hussein MM, Hamdy A, Abdel-Maksoud FM, 2020: Comparative morphological features of syrinx in male domestic fowl *Gallus gallus domesticus* and male domestic pigeon *Columba livia domestica*: A histochemical, ultrastructural, scanning electron microscopic and morphometrical study. *Microsc Microanal*, 26(2), 326–347.
- İnce NG, Pazvant G, 2010: Martılarda larynx ve trachea üzerinde makro-anatomik çalışma. *İstanbul Üniv Vet Fak Derg*, 36(2), 1-6.
- Kabak M, Orhan IO, Hazıroğlu RM, 2007: The gross anatomy of larynx, trachea and syrinx in the long-legged buzzard (*Buteo rufinus*). *Anat Histol Embryol*, 36(1), 27-32.
- Kara H, Özdemir D, Özüdoğru Z, Balkaya H, 2023. Morphological comparison of the chukar partridge (*Alectoris chukar*) and Japanese quail (*Coturnix coturnix japonica*) syrinx. *Vet Res Forum*, 14(6), 341-345.
- King AS, McLelland J, 1984: *Birds. Their Structure And Function*. Second ed. London: Bailliere Tindall pp:110-121.
- Koenig HE, Navarro M, Zengerling G, Korbel R, 2016: *Avian Anatomy*, second edition, 118-126.
- Mohamed R. 2017: Sexual dimorphism in the anatomical features of the Syrinx in the White Pekin ducks (*Anas platyrhynchos*). *Int J Agricult Sci Vet Med*, 5(5), 78-85.
- Nickel R, Schummer A, Seiferle E, 1977: *Anatomy of the Domestic Birds*. Verlag Paul Parey Berlin pp: 62-65
- Oliveira ELR, Zuliani F, de Camargo GC, Desantis S, Schimming BC, 2023. Morphology of the syrinx of three species of birds from Brazilian cerrado (*Psittacara leucophthalmus*, *Rhynchotus rufescens* and *Cariama cristata*): Gross anatomy and light microscopy study. *Anat Histol Embryol*, 52(6), 827-835.
- Onuk B, Hazıroğlu RM, Kabak M, 2010: The Gross anatomy of the larynx, trachea and syrinx in goose (*Anser anser domesticus*): Bronchi and sacci pneumatici. *Kafkas Üniv Vet Fak Derg*, 16(3), 443-450.
- Onuk B, Kabak M, Gülbahar M, Kabak Y, Demirci B, Karayığit M, Gültüken M, 2015: Gerze horoz ve tavuklarında larynx, trachea ve syrinx'in anatomik yapısının belirlenmesi. *İstanbul Üniv Vet Fak Derg*, 41(1), 92-98.
- Öcal K, Erde, H, 2002: Solunum sistemi. *Evcil Kuşların Anatomisi*. Ed. Dursun, N. I.baskı, Medisan Yayınevi, Ankara. pp. 77-84, 91-96.
- Rajathi S, Lucy KM, Maya S, Chungath JJ, 2009: Anatomical studies on the trachea in Japanese quail (*Coturnix coturnix japonica*). *J Vet Anim Sci*, 40, 17-19.
- Taşbaş M, Özcan Z, Hazıroğlu M, 1986: Penguenin dili ve ön solunum yollarının (larynx cranialis, trachea, syrinx) anatomik ve histolojik yapısı üzerinde bir çalışma. *Ankara Üniv Vet Fak Derg*, 33(2), 240-261.
- Taşbaş M, Hazıroğlu RM, Çakır A, Özer M, 1994: Denizli horozunun solunum sisteminin morfolojisi. II. Larynx, trachea, syrinx. *Ankara Üniv Vet Fak Derg*, 41,135–153.
- Toprak B, Balkaya H, Yılmaz S, 2016: Atmacada (*Accipiter nisus*) Ağız–Yutak Boşluğunun Makroskobik Yapısı Üzerine İncelemeler. *FÜ Sağ Bil Vet Derg*, 30(3), 165-170.
- Yılmaz B, Demircioğlu İ, Arıcan İ, Yılmaz R, 2016: Aseel Irkı Horoz ve Tavuklarda Larynx, Trachea ve Syrinx'in Anatomik ve Histolojik Yapısı. *Fırat Üniv Sag Bil Vet Derg*, 30(3), 211-216.



Fare (Balb/C mice) ve Sıçan (Wistar Albino Rat)'da Articulatio Genus'un Karşılaştırmalı Morfolojik İncelenmesi

Sefa YEKELER^{1,a}, Yonca Betil KABAK^{2,b}, Burcu ONUK^{3,c,*}

¹Ondokuz Mayıs Üniversitesi Lisansüstü Eğitim Enstitüsü Veterinerlik Anatomisi Anabilim Dalı, TR- 55200 Samsun, Türkiye.

²Ondokuz Mayıs Üniversitesi Veteriner Fakültesi Patoloji Anabilim Dalı, TR- 55200 Samsun- Türkiye.

³Ondokuz Mayıs Üniversitesi Veteriner Fakültesi Anatomi Anabilim Dalı, TR- 55200 Samsun, Türkiye.

^aORCID: 0009-0000-8826-6476;

^bORCID: 0000-0002-3442-8377;

^cORCID: 0000-0001-8617-3188;

Geliş Tarihi: 18.03.2024

Kabul Tarihi: 23.05.2024

Bu makale Nasıl kaynak gösterilir: Yekeler S, Kabak YB, Onuk B. (2024). Fare (Balb/C mice) ve Sıçan (Wistar Albino Rat)'da Articulatio Genus'un Karşılaştırmalı Morfolojik İncelenmesi. Harran Üniversitesi Veteriner Fakültesi Dergisi, 13(1): 56-62.

DOI:10.31196/huvfd.145478.

***Yazışma adresi:** Burcu ONUK

Ondokuz Mayıs Üniversitesi Veteriner Fakültesi Anatomi Anabilim Dalı, TR- 55200 Samsun, Türkiye.

e-mail: burcuonuk@omu.edu.tr

Online erişim adresi: <https://dergipark.org.tr/tr/pub/huvfd>

Özet: Diz eklemi vücuttaki konumu nedeniyle travmalara açık ve korunmasız bir eklemdir. Bölgenin yapısı, farklı hayvan türlerinde morfolojik ve görüntüleme teknikleri gibi yöntemlerle ortaya konulsada hala konu ile ilgili eksik kısımlar bulunmaktadır. Altışar adet erişkin fare ve sıçanın kullandığı bu çalışmada articulatio genus'un karşılaştırmalı morfolojik incelemesinin yapılarak literatür eksiklerinin giderilmesi amaçlandı. Sıçanda insana benzer şekilde trochlea ossis femoris'i yanlardan sınırlayan labium laterale, labium mediale'ye göre daha proksimal'den başlarken farede bu yapılar diğer evcil memelilere benzer olarak aynı mesafeden başlamaktaydı. Meniscus'lerin şekli sıçanda ve farede farklıydı. Sıçanda her iki meniscus'de "C" harfi şeklindeydi. Fakat lateral meniscus insandakinin tersi olarak daha geniş yapıdaydı. Farede lateral meniscus tek parçalı iken medial meniscus iki parçalı melek kanadı görünümündeydi. Her iki türdede meniscus içerisinde kemik dokuya rastlanıldı. Femur'un distal kondüllerinde yer alan fabella'nın sayısı ve şekli sıçanda genel olarak köpeğe benzesede medial fabella'nın yuvarlak olması ve popliteal fabella'nın konumu farklılık oluşturdu. Farede saptanan iki fabella da yaklaşık olarak aynı boyuttaydı ve şekil olarak şapkaya benzemektedir. Bu çalışma ile elde edilen verilerin literatürüne katkı sağlayacağı düşünüldü.

Anahtar Kelimeler: Anatomi, Femur, Meniscus, Patella, Tibia.

Comparative Morphological Examination of Articulatio Genus in Mouse (Balb/C) and Rat (Wistar Albino)

Abstract: The knee joint is vulnerable to trauma and unprotected due to its location in the body. Although the structure of the region has been revealed by methods such as morphological and imaging techniques in different animal species, there still needs to be parts on the subject. This study, aimed to fill the literature gaps by performing a comparative morphological examination of the articulatio genus in which six adult mice and six rats were used. In the rat, similar to humans, the labium laterale, which limits the trochlea ossis femoris from the sides, started more proximal than the labium mediale, whereas in the mouse, these structures started from the same distance, similar to other domestic mammals. Both menisci were shaped like the letter "C" in the rat. However, the lateral meniscus was more comprehensive than in humans. While the lateral meniscus was in one piece, the medial meniscus looked like a two-piece angel wing in the mouse. Bone tissue was found within the meniscus in both species. Although the number and shape of the fabella located in the distal condyles of the femur were generally similar to the dog in the rat, the roundness of the medial fabella and the location of the popliteal fabella made a difference. The two fabellas detected in the mouse were approximately the same size and resembled a hat in shape. It is thought that the data obtained from this study will contribute to the literature.

Keywords: Anatomy, Femur, Meniscus, Patella, Tibia.

Giriş

Diz eklemi (art. genus) vücudun hareket ettirilmesinden vücudun taşınmasına kadar oldukça önemli fonksiyonları kapsamaması nedeniyle yapı olarak çok iyi bilinmelidir (Esmer ve ark. 2011; Üstüner, 2006). Bu eklem femur, patella ve tibia kemikleri arasında şekillenmiş composit bir eklemdir (Dursun, 2008; Dyce ve ark., 2010). Bu eklemden femur ile tibia arasında iki kondiler tipte, patella ve femur arasında ise sellar tipte olmak üzere üç adet farklı eklem bulunur (Dursun, 2008; Dyce ve ark., 2010; König ve Liebich, 2015).

Fare dizinin genel yapısı diğer türlere benzesede boyut olarak çok küçüktür. Fare tibia'sı ve fibula'sı distal yarılarının çoğu boyunca kaynaşarak tibio-fibular kompleksi oluşturur (Glasson ve ark., 2010). Tibial yüzeyin morfolojisi de insanlardakinden farklıdır. Tibial kondiller posterior'da interkondiler fossa ile ayrılır (Olah ve ark., 2021). Sıçanda tibia ve fibula kısmen kaynaşmıştır ve femoral kondillerin eğriliği posterior'da belirgin bir şekilde artmaktadır (Hildebrand ve ark., 1991).

Literatürde diz eklemi morfometrik ve anatomik açıdan çeşitli görüntüleme yöntemleri kullanılarak incelenmiştir (Fowlie, 2011; Maulet ve ark. 2005). Bunun yanısıra sağlıklı ya da hastalık oluşturulmuş fare ve sıçanda diz eklemine modellemesinin yapıldığı (Charles ve ark., 2016; Lin ve Xing, 2018; Oláh ve ark., 2021; Wendling ve ark., 2021; Xu ve ark., 2017), histolojik yapısının incelendiği (Carballo ve ark., 2018; Takahashi ve ark., 2019) ve arka bacak lokomotor sistemi (Charles ve ark., 2016) üzerine

yapılmış çalışmalar bulunmaktadır. Fakat BALB/c fare ve Wistar Albino sıçan diz eklemlerinin detaylı yapısının makroskopik ve osteometrik olarak incelendiği ve birbirleriyle karşılaştırıldığı bir araştırmaya rastlanılmamıştır. Bundan ötürü yapılan çalışma sonuçlarının konu ile ilgili literatüre katkıda bulunması amaçlanmıştır.

Materyal ve Metot

Bu çalışmada 6 adet ergin fare (BALB/c) ve 6 adet ergin sıçan (Wistar albino)'a ait sağ ve sol olmak üzere toplam 24 adet diz eklemi kullanıldı. Çalışmanın materyalini daha önce OMÜ Veteriner Fakültesi Anatomi Anabilim Dalında doktora tez projesinde kullanılmış hayvanlar (Etik kurul No: 2021/32) oluşturdu. Kemik doku maserasyonunda dermestes maculatus larvaları kullanıldı. Olympus SZ61TRC marka stereomikroskop altında diseksiyonlar yapılarak makroskopik ve morfometrik veriler alındı. Fotoğraflar Olympus C-5060 marka dijital fotoğraf makinesi ile çekildi. Tüm ölçümlerde dijital kumpas (Mitutoya, japonya) kullanıldı. Eklemi oluşturan kemiklere ait ölçüm noktaları Şekil 1'de gösterildi. Histolojik incelemeler için ayrılan fare ve sıçan diz eklemleri %10'luk formalinde tespit edildikten sonra %2'lik paraformaldehit ile hazırlanan %10'luk formik asit solüsyonunda 1-1,5 hafta süreyle dekalsifiye edildi. Sonrasında rutin yöntemle takip edilen dokular parafinde bloklandı. Bloklardan 5 µm kalınlığında alınan kesitler

Tablo 1 Diz eklemine katılan kemiklere ait ölçüm değerleri

	mm	Dişi fare	Erkek fare	Dişi Sıçan	Erkek Sıçan
Condylus medialis ^a	yükseklik	1,68±0,08	1,75±0,3	3,94±0,05	4,11±0,13
	genişlik	1,17±0,06	1,33±0,19	2,41±0,02	2,58±0,16
Condylus lateralis ^a	yükseklik	1,80±0,10	1,67±0,26	3,50±0,02	3,77±0,17
	genişlik	1,32±0,17	1,23±0,14	2,46±0,17	3,12±0,28
Fossa intercondylaris ^a	genişlik	1,62±0,11	1,70±0,11	3,08±0,02	3,16±0,09
	Epicondylus lateralis ile epicondylus medialis arası ^a				
	dış mesafe	2,65±0,03	2,73±0,13	5,90±0,17	6,74±0,27
	iç mesafe	0,71±0,06	0,67±0,05	1,38±0,05	1,49±0,11
Trochlea ossis femoris ^a	çap	2,69±0,10	2,44±0,16	6,42±0,09	7,86±0,28
Femur distal uç ^a	genişlik	2,12±0,06	2,47±0,16	4,37±0,14	5,30±0,42
Cartilage suprapatellaris	uzunluk	1,89±0,02	1,91±0,02	3,03±0,05	3,09±0,08
	genişlik	1,00±0,18	0,97±0,05	1,7±0,02	1,8±0,03
Patella	uzunluk	1,93±0,06	1,90±0,06	5,11±0,05	5,09±0,03
	genişlik	1,17±0,07	1,26±0,09	2,59±0,10	3,17±0,04
Condylus lateralis ^b	craniocaudal uzunluk	1,86±0,31	1,89±0,08	5,18±0,11	5,22±0,13
	mediolateral uzunluk	1,38±0,31	1,81±0,16	3,45±0,09	3,04±0,19
Condylus medialis ^b	craniocaudal uzunluk	1,93±0,09	2,04±0,13	4,30±0,25	5,80±0,29
	mediolateral uzunluk	1,4±0,12	1,55±0,21	3,12±0,06	2,79±0,09
İki tuberkül arası ^b	mesafe	0,61±0,01	0,56±0,07	1,37±0,09	1,31±0,05

^a:Femur'a ait ölçüm noktaları; ^b: tibia'ya ait ölçüm noktaları

Hematoksilen-Eozin (HE) ile boyandı. Histolojik inceleme Nikon Eclipse E600W ışık mikroskobu yardımıyla yapıldı ve Nikon DS Camera Head DS-5M görüntüleme sistemi ile mikroskobik fotoğrafları çekildi.

Bulgular

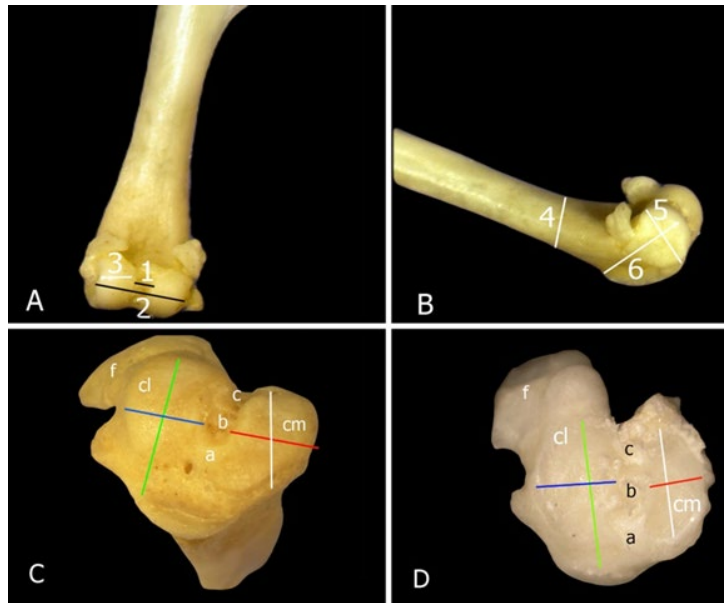
Yapılan incelemeler sonucunda sıçanda ve farede art. genus'un art. femorotibialis, art. femoropatellaris ve art. tibiofibularis proximalis olmak üzere 3 adet eklemde oluştuğu saptandı. Çalışılan türlerde diz eklemine katılan kemiklere ait ölçümler Tablo 1'de sunuldu.

Farede femur'un condylus lateralis ve medialis'inin proksimal'de hemen hemen eşit büyüklükte olduğu sıçanda ise condylus lateralis'in proksimal kısmının condylus medialis'e oranla daha geniş şekillendiği gözlemlendi. Sıçanda bu genişleşmiş kısımda iki adet fabella (susam kemiği) bulunmaktaydı. Condylus medialis'in proksimal'inde ise bir adet fabella mevcuttu (Şekil 2). Farede ise her iki condylus üzerinde şekli fõtr şapkaya benzeyen birer adet fabella bulunmaktaydı (Şekil 2).

Femur'a cranial'den bakıldığında trochlea ossis femoris, her iki türde de lateral ve medial iki labium ve bu labiumlar arasında patella'nın kaymasına olanak sağlayan bir oluktan oluşmaktaydı (Şekil 2). Sıçanda labium laterale, labium mediale'ye göre daha proksimal'den başlarken farede her ikisinde aynı mesafeden başladığı ve eşit yükseklikte olduğu saptandı. Patellar oluşun genişliği ratta $2,09 \pm 0,22$ mm, farede ise $0,75 \pm 0,09$ mm olarak ölçüldü. Sıçanda patella'nın basis patella denilen kısmı geniş ve yuvarlak iken, apex patellae denilen kısmı daha düz ve dardı (Şekil 3). Ayrıca sıçanda apex patella'nın cranial yüzünde bir tümseklik olduğu gözlemlendi. Farede patella'nın hem basis hemde apex

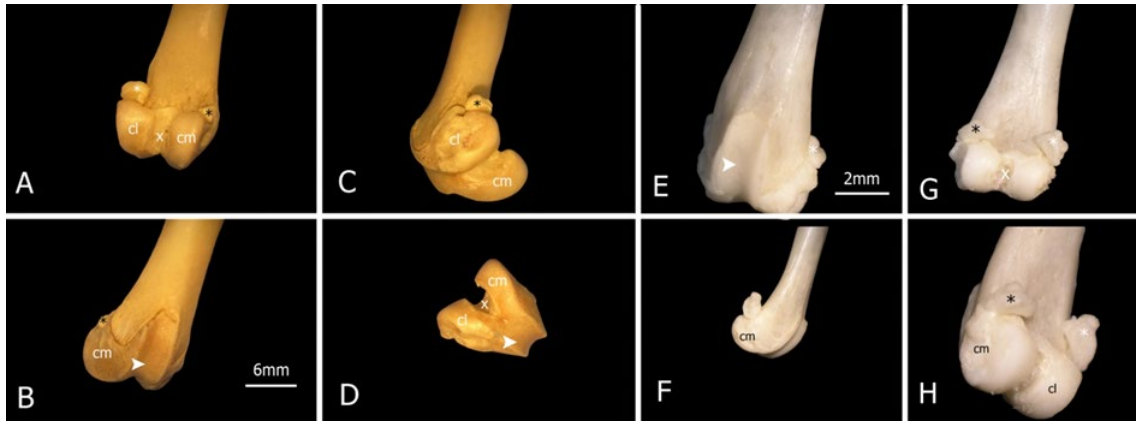
kısmı düzdü (Şekil 3). Patella'yı tuberositas tibia'ya bağlayan ligamentum patella'nın apex patella'dan başladığı saptandı. Bu ligament her iki türde de tek parçalı bant şeklindeydi (Şekil 3).

Sıçanda ve farede tibia'nın condylus lateralis'i condylus medialis'e göre hem daha geniş hemde yüksekti. Her iki türde de condylus lateralis, lateral'den iki çıkıntıya sahipti ve aralarında bir çentik mevcuttu (Şekil 1). Farede condylus lateralis'in caudal yarımı medial'e doğru eğilimliydi. Tuberculum intercondylaris lateralis ve medialis aralarında açıklık olacak şekilde birbirlerine paralel olarak konumlanmıştı ve eşit yükseklikteydi. Bu nedenle eminentia intercondylaris oluşmamıştı. Sıçanda ise tuberculum intercondylaris lateralis ve medialis oldukça belirgindi ve lateral olarak konumlanan medial'e göre daha yüksekti. İki türde de bu yapılar arasında area intercondylaris centralis, gerisinde area intercondylaris caudalis ve önünde de area intercondylaris cranialis mevcuttu (Şekil 1). Ancak bu bölgeler sıçanda çukur şeklinde iken farede sıg idi. Sıçanda area intercondylaris centralis diğer arealara nazaran daha derindi. Tibia'nın condylus'larının üzerinde her iki türde de meniscus'ler bulunmaktaydı. Farede lateral ve medial meniscus'lerin şekli farklıydı. Lateral meniscus tek parçalı yamuk şeklindeydi. Medial meniscus ise iki parçadan oluşmaktaydı (Şekil 3). Bunun cranial konumlanan parçası diğer parçasına nazaran daha büyüktü ve iki parça birbirleriyle birleşmişti. Bu görüntüsü melek kanadına benzemektedir. Sıçanda ise meniscus lateralis ve medialis "C" harfi şeklinde idi. Meniscus lateralis medialis'e göre daha geniş bir "C" oluşturmaktaydı (Şekil 3). Histolojik incelemede meniscusler hem sıçanda hemde farede kollagen iplik demetlerinden ve chondroblastlardan meydana gelmekteydi. Aynı zamanda meniscuslerin uç kısımlarında osteositlerden oluşan kemik dokunun varlığı saptandı (Şekil 4).

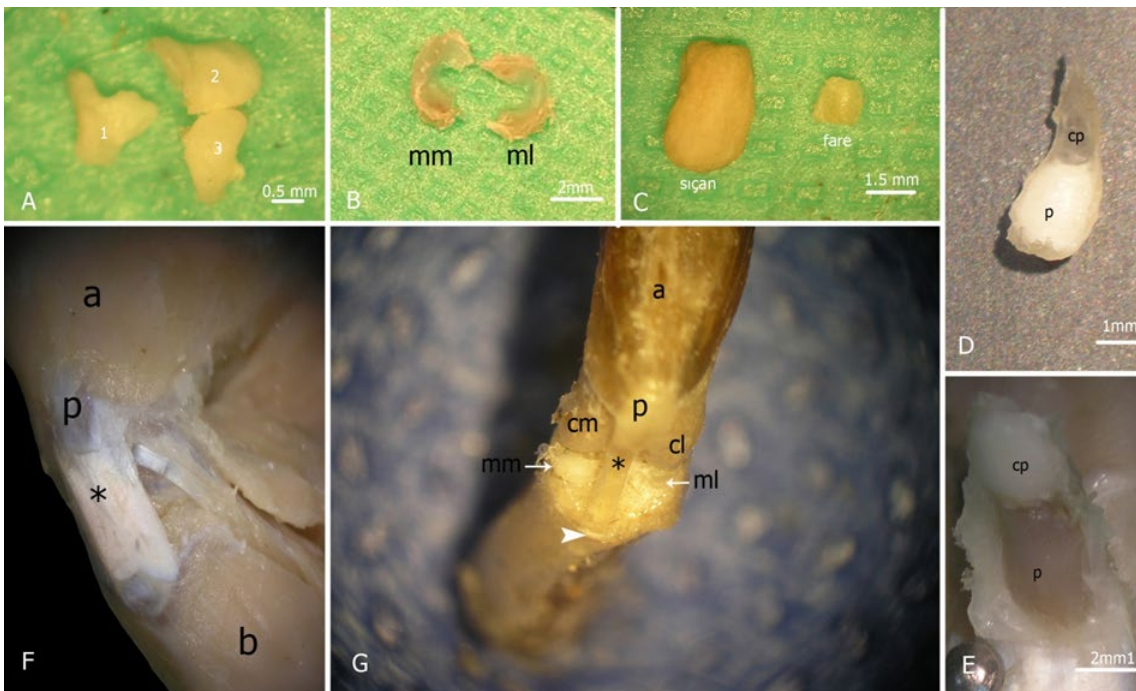


Şekil 1. Fare ve sıçan'a ait ölçüm noktaları A: femur'un caudal görünümü; B: femurun lateral görünümü; C: tibia'nın craniodorsal görünümü; D: Tibia'nın dorsal görünümü.

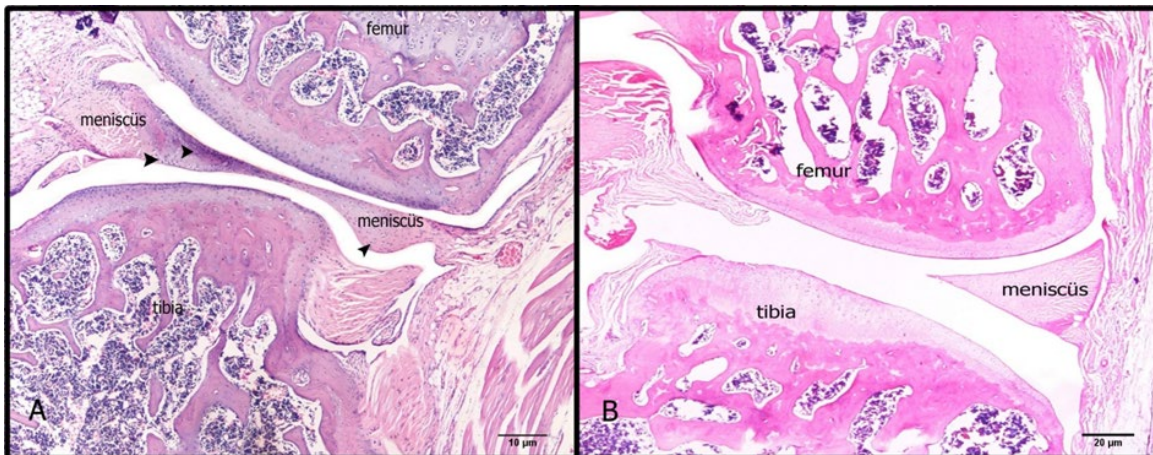
1: iki kondil arası iç mesafe, 2: iki kondil arası dış mesafe, 3: condylus genişliği, 4: femur distal genişliği; 5: condylus yüksekliği, 6: trochlea ossis femoris çapı, beyaz çizgi: condylus medialis'in craniocaudal uzunluğu, kırmızı çizgi: condylus medialis'in mediolateral uzunluğu, yeşil çizgi: condylus lateralis'in craniocaudal uzunluğu, mavi çizgi: condylus lateralis'in mediolateral uzunluğu, a: area intercondylaris cranialis, b: area intercondylaris centralis, c: area intercondylaris caudalis, f: fibula; cl: condylus lateralis, cm: condylus medialis



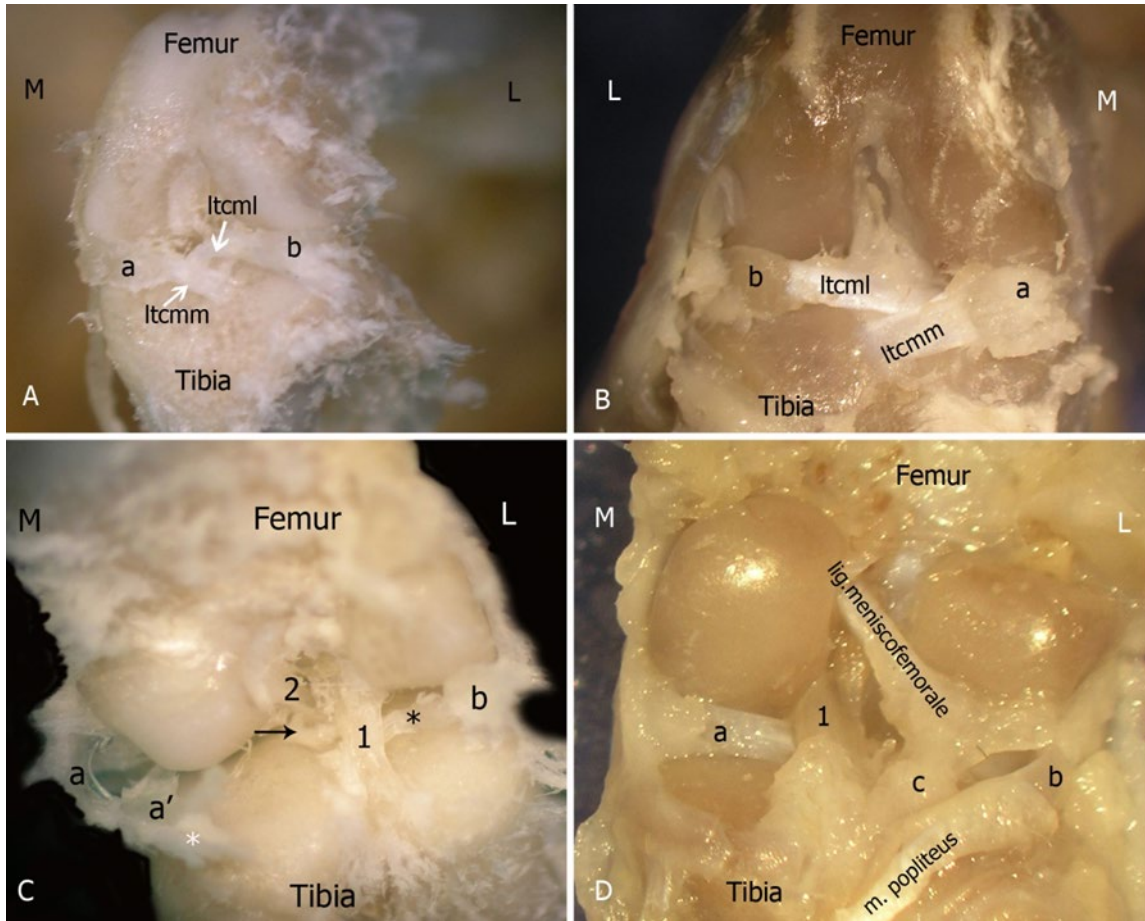
Şekil 2. Siçan'da (A-D) ve fare'de (E-H) femurun caudal (A,G), cranial (B,E), lateral (C,F,H) ve distal (D) yönlerden görünümü
cl: condylus lateralis; cm: condylus medialis; x: fossa intercondylaris; ok başı: trochlea ossis femoris; siyah yıldız: os sesamoideum m. gastrocnemius medialis; beyaz yıldız: os sesamoideum m. gastrocnemius lateralis



Şekil 3. Fare'de (A, C, D, G) ve siçanda (B, C, E, F) patella ve meniscus'lerin görünümü
a: m. quadriceps femoris; b: m. tibialis cranialis; cl: condylus lateralis; cm: condylus medialis; cp: cart. suprapatellaris; mm: meniscus medialis; ml: meniscus lateralis; p: patella; *: ligamentum patella; beyaz ok başı: tuberositas tibia; 1: lateral meniscus; 2: medial meniscus'ün cranial parçası; 3: medial meniscus'ün caudal parçası.



Şekil 4. Fare'de (A) (X 4 bar) ve siçan'da (B) art. genus'un histolojik yapısı (X 2 bar) ok başı: chondroblast



Şekil 5. Fare (A, C) ve siçan (B, D)'de art. genus'un cranial (A, B) ve caudal (C, D)'den görünümü
a: meniscus medialis'in cranial kısmı, a': meniscus medialis'in caudal kısmı; b: meniscus lateralis; Itcmm ve siyah ok: ligamentum tibiale craniale menisci medialis; Itcml: ligamentum tibiale craniale menisci lateralis; M: medial; L: lateral; 1: ligamentum cruciatum caudale; 2: ligamentum cruciatum craniale; siyah yıldız: ligamentum tibiale caudale menisci lateralis; beyaz yıldız: ligamentum tibiale caudale menisci medialis; c: lig. meniscotibiale.

Farede ve siçanda femur ile tibia arasında çapraz olarak uzanan ligamentum cruciatum craniale, medial kondülün cranial'inden çıkıp tibia'nın inc. poplitea'sına bağlıyordu. Ligamentum cruciatum caudale ise femur'un condylus lateralis'inin iç yüzünden çıkıp area intercondylaris centralis'e bağlanmaktaydı. Meniscus lateralis'in caudal'inden çıkan ligamentum tibiale caudale menisci lateralis'in, lig. cruciatum caudale'nin altından geçerek area intercondylaris caudalis'e bağlandığı saptandı (Şekil 5). Medial meniscus'ün cranial'inden ayrılan ligamentum tibiale craniale menisci medialis'in iki parçalı olduğu bir kısmının lateral meniscus'den çıkan ligamentum tibiale craniale menisci lateralis ile önde birleşirken (lig. transversum genus) diğer kısmının ise area intercondylaris cranialis'e bağlandığı belirlendi. Medial meniscus'ün caudal kenarından çıkan ligamentum tibiale caudale menisci medialis, area intercondylaris caudale'ye bağlanmaktaydı (Şekil 5).

Tartışma

Patellar oluşu sınırlandıran lateral labium'un insanda (Dere, 2012), medial labium'un ise bos ve equus'ta daha büyük şekillendiği, fakat k. ruminant, carnivor ve domuzda bu iki labium arasında büyüklük açısından bir fark olmadığı

ifade edilmiştir (Dursun, 2008; Dyce ve ark., 2010; König ve Liebich, 2015). Yapılan çalışmada siçanda labium laterale ile labium mediale'ye göre daha proksimal'den başladığı için daha büyüktü. Bu durum insan'a (Dere, 2012) benzemektedir. Farede ise labium laterale ile labium mediale'nin aynı mesafeden başlaması ve eşit yükseklikte olması k. ruminant ve carnivor (Dyce ve ark., 2010; König ve Liebich, 2015)'a benzerdi.

İnsanda, bazı sığır türlerinde ve carnivorlarda her iki meniscus'ün cranial uçlarını birbirine bağlayan lig. transversum genus'dan bahsedilmektedir (Esmer ve ark. 2011; König ve Liebich, 2015). Yapılan çalışmada da hem farede hemde siçanda bu ligamentin varlığı tespit edilmiştir. Bu ligamentin literatürde (Esmer ve ark. 2011; König ve Liebich, 2015) bildirildiği gibi meniscus'lerin yanlara doğru hareketini kısıtladığı düşünülmüştür.

Literatürde (Hildebrand ve ark., 1991; Sert ve Eken, 2024) siçan, tavşan ve kemirgenlerde cart. suprapatellaris'in mevcudiyetinden bahsedilmektedir. Yapılan çalışmada da cart. suprapatellaris belirlendi. Bu kıkırdığın şeklinin ise çalışılan türlerde farklı olduğu dikkat çekti. Siçanda oval şekilli olan bu kıkırdak farede ön ucu daha sivri üçgen şeklindeydi. Bu yapının adı geçen araştırmacıların (Sert ve Eken,

2024) ifade ettikleri gibi bu türlerin zıplama kabiliyetini artırdığı öngörüldü.

İnsanda (Sanal, 2016) ve evcil memelilerde (Dursun, 2008) genel olarak meniscus'lerin fibrokıkırdak yapıda olduğu ifade edilmiştir. Yetişkin fare (Pedersen, 1949) meniscus'ünde kemikçikler veya lunulalar olarak adlandırılan kemik nodüllerin bulunduğu bildirilmiştir. Ayrıca literatürde fare ve diğer kemirgenlere benzer şekilde sıçanların meniscus'lerinin de kemikleşmiş olduğundan ve boynuzlarında piramit şeklinde kemikçikler içerdiğinden bahsetmektedir (Gamer ve ark., 2017; Hildebrand ve ark., 1991). Yapılan çalışmada da her iki türün ergin ve sağlıklı hayvanlarının meniscus'lerinde kemik doku olduğu belirlendi.

Mevcut çalışmada kullanılan sıçanda meniscus'lerin şekli, literatür de evcil memeliler için (Dursun, 2008) bildirilenle benzerdi. İnsanda (Gamer ve ark., 2017) medial meniscus'ün daha geniş yapıda "C" şeklinde olduğu bildirilmiştir. Sıçanda (Hildebrand ve ark., 1991) ise lateral meniscus'ün medial olandan daha büyük olduğu söylenmektedir. Yapılan çalışmada ise sıçanda lateral meniscus'ün insandakinin tersi olarak daha geniş yapıda "C" şeklinde olduğu gözlemlendi. Farede ise meniscus'lerin şekli diğer memelilerde bildirilenden farklıydı. Lateral meniscus tek parçalı iken medial meniscus iki parçalı melek kanadı görünümündeydi. Literatürde farede meniscus'ün şekline ait bulguya rastlanılmadı.

Evcil memelilerde ve insanda mevcut olan, femur ve tibia arasında bulunan lig. cruciatum craniale ve caudale ile yanlarda iki kemiği birbirine bağlayan lig. collaterale laterale ve mediale'nin origo ve insertio noktaları için yapılan çalışmada elde edilen bulgularının literatürde fare (Carballo ve ark., 2018) ve sıçanda (Song ve ark., 2023) bildirilenle uyumlu olduğu saptandı.

Sonuç

Bu çalışmada BALB/c fare ve Wistar Albino sıçan olmak üzere iki farklı deney hayvanı türünde diz eklemine anatomik yapısı incelendi. Farede femur'un condylus lateralis ve medialis'inin proksimal'de hemen hemen eşit büyüklükte olduğu sıçanda ise condylus lateralis'in proksimal kısmının condylus medialis'e oranla daha geniş olduğu saptandı. Linea intercondylaris'in sıçanda fareye göre daha belirgin olduğu görüldü. Farede fossa intercondylaris ile fossa poplitea arası kemiksel bir bölme vardı bu nedenle fossa poplitea sıçana göre oldukça çukurdu. Her iki türde de trochlea ossis femoris lateral ve medial iki labium ve bu labiumlar arasında patella'nın kaymasına olanak sağlayan bir oluktan oluşmuştu. Sıçanda labium laterale, labium mediale'ye göre daha proksimal'den başlamasına rağmen farede her iki labium'unda aynı mesafeden başladığı belirlendi. Tibia'nın condylus'larının üzerinde her iki türde de meniscüsler bulunmaktaydı. Farede lateral meniscüs'ün tek parçalı yamuk şeklinde olması ve medial meniscüs'ün ise iki parçalı melek kanadı görüntüsü çalışmanın dikkat çekici bulgusuydu. Bu çalışmada oldukça küçük bir hayvan olan farede meniscüs'ün şeklinin farklı bir yapıda olması, türler

arasında bu yapıda değişikliklerin olup olmadığının ileriki çalışmalarda araştırılması gerekliliğini düşündürdü.

Çıkar çatışması

Yazarlar bu yazı için gerçek, potansiyel veya algılanan çıkar çatışması olmadığını beyan etmişlerdir.

Etik izin

Bu çalışma "Hayvan Deneyleri Etik Kurullarının Çalışma Usul ve Esaslarına Dair Yönetmelik" Madde 8 (k) gereği HADYEK iznine tabi değildir.

Finansal destek

Bu çalışma için herhangi finansal destek bulunmamaktadır.

Benzerlik Oranı

Makalenin benzerlik oranının sisteme yüklenen raporda belirtildiği gibi % 9 olduğunu beyan ederiz.

Açıklama

Bu çalışma 1. yazarın aynı isimli yüksek lisans tez çalışmasından özetlenmiştir.

Yazar Katkıları

Fikir/Kavram: BO, SY
Tasarım: SY, BO
Denetleme/Danışmanlık: BO
Veri Toplama ve/veya İşleme: SY, BO
Analiz ve/veya Yorum: SY, BO, YBK
Kaynak Taraması: SY, BO
Makalenin Yazımı: SY, BO
Eleştirel İnceleme: BO, YBK

Kaynaklar

- Carballo CB, Hutchinson ID, Album ZM, Mosca MJ, Hall A, Rodeo Jr, S., ... and Rodeo SA, 2018: Biomechanics and microstructural analysis of the mouse knee and ligaments. *J Knee Surg*, 31(06), 520-527.
- Charles JP, Cappellari O, Spence AJ, Wells DJ, Hutchinson JR, 2016: Muscle moment arms and sensitivity analysis of a mouse hindlimb musculoskeletal model. *J Anat*, 229(4), 514-535.
- Dere F, 2012: Anatomi Atlası ve Ders Kitabı. 6. Baskı, Adana: Nobel Tıp Kitapevleri.
- Dursun N, 2008: Veteriner Anatomi I (12. Baskı). Medisan Yayınevi.
- Dyce KM, Sack WO, Wensing CJG, 2010: Textbook of veterinary anatomy. 4th ed. United States, Missouri: Saunders Elsevier.
- Esmer AF, Başarır K, Binnel M, 2011: Diz eklemine cerrahi anatomisi. *TOTBİD Dergisi*, 10 (1):38 44.
- Fowle JG, 2011: Functional anatomy of the equine meniscus: Pathogenesis and pathophysiology of injury to the cranial horn of the medial meniscus. Michigan State University. Large Animal Clinical Sciences.

- Glasson SS, Chambers MG, Van Den Berg WB, Little CB, 2010: The OARSI histopathology initiative- recommendations for histological assessments ofosteoarthritis in the mouse. *Osteoarthr Cartil*, 18 Suppl 3, S17–S23.
- Hildebrand C, Öqvist G, Brax L, Tuisku F, 1991: Anatomy of the rat knee joint and fibre composition of a major articular nerve. *Anat Rec*, 229(4), 545-555.
- König HE, Liebich HG, 2020: Veterinry Anatomy of Domestic Animals: Textbook and Colour Atlas, Barnes & Noble.
- Lin X, Xing L, 2018: Ultrasound as a New Imaging Tool to Assess Pathological Change of Joints in Preclinical Mouse Models of Osteoarthritis. *J Orthop Physiother*, 1(1), 102.
- Maulet BEB, Mayhew IG, Jones E, Booth TM, 2005: Radiographic anatomy of the soft tissue attachments of the equine stifle. *Equine Vet J*, 37(6), 530-535.
- Oláh T, Michaelis JC, Cai X, Cucchiarini M, Madry H, 2021: Comparative anatomy and morphology of the knee in translational models for articular cartilage disorders. Part II: Small animals. *Ann Anat*, 234, 151630.
- Pedersen HE, 1949: The ossicles of the semilunlar cartilages of rodents. *Anat Rec*, 105 (1), 1-9.
- Akkoyun Sert Ö, Eken E, 2024; Yeni Zelanda Tavşanlarında Diz Eklemine Bilgisayarlı Tomografi ve Manyetik Rezonans Görüntülerinden Üç Boyutlu Verilerinin Değerlendirilmesi. *Selçuk Sağlık Dergisi*, 5(1), 70 – 78.
- Takahashi I, Matsuzaki T, Kuroki H, Hosono M, 2019: Disuse histological changes of an unloading environment on joint components in rat knee joints. *Osteoarthr Cartil*, 1(1-2), 100008.
- Üstüner Y, 2006: Total Diz Artroplastisi Erken Dönem Sonuçları (uzmanlık tezi). İstanbul: TC Sağlık Bakanlığı Haseki Eğitim ve Araştırma Hastanesi, Ortopedi ve Travmatoloji Kliniği.
- Wending O, Hentsch D, Jacobs H, Lemercier N, Taubert S, Pertuy F., ... and Herculat, Y, 2021: High resolution episcopic microscopy for qualitative and quantitative data in phenotyping altered embryos and adult mice using the new "Histo3d" system. *Biomedicine*, 9(7), 767.
- Xu H, Bouta EM, Wood RW, Schwarz EM, Wang Y, Xing L, 2017: Utilization of longitudinal ultrasound to quantify joint soft-tissue changes in a mouse model of posttraumatic osteoarthritis. *Bone Res*, 5(1), 1-7.



Investigation of the Presence and Prevalence of Listeriosis in Clinical Samples in Van and its Region

Kadir AKAR^{1,a,*}, Gökçenur SANIOĞLU GÖLEN^{2,b}, Ali Rıza BABAOĞLU^{1,c}, İsmail Hakkı EKİN^{1,d}

¹Van Yuzuncu Yil University, Department of Microbiology, Faculty of Veterinary Medicine, Van-Turkey.

²Universty of Aksaray, Department of Microbiology, Faculty of Veterinary Medicine, Aksaray-Turkey.

^aORCID: 0000-0003-0894-7357

^bORCID: 0000-0001-9950-330X

^cORCID: 0000-0001-8023-3442

^dORCID: 0000-0001-5029-8130

Received: 31.03.2024

Accepted: 28.05.2024

How to cite this article: Akar K, Sanioğlu Gölen G, Babaoğlu AR, Ekin İH. (2024). Investigation of the Presence and Prevalence of Listeriosis in Clinical Samples in Van and its Region. Harran Üniversitesi Veteriner Fakültesi Dergisi, 13(1): 63-67. DOI:10.31196/huvfd.1452209.

***Correspondence:** Kadir AKAR

Van Yuzuncu Yil University, Department of Microbiology, Faculty of Veterinary Medicine, Van-Turkey.

e-mail: kadirakar@yyu.edu.tr

Available on-line at: <https://dergipark.org.tr/tr/pub/huvfd>

Abstract: Listeriosis is an infection that causes abortion in humans and various animals worldwide. The causative agent is spread by livestock faeces, especially ruminants, and has a zoonotic character, transmitted by ingesting contaminated silage and feed. In this study, it was aimed to investigate the presence of *Listeria* spp. in 120 samples (79 abortion material, 41 brain material) of sheep. For this purpose, the polymerase chain reaction (PCR) method was performed using specific oligonucleotide pairs for *Listeria* spp. all of the abortion materials from Van province and its districts were found to be negative. However, a total of 2 (4.87%) samples, one each from the Erciş and Gevaş districts, from sheep with clinical nervous symptoms were found positive. As a result, it was determined that *Listeria* spp. was sporadic in Van province. It was concluded that this situation may be due to the low use of silage in ovine breeding in Van province. It was thought that periodical studies should be carried out to determine the course of the disease in the region.

Keywords: *Listeria* spp., PCR, Silage.

Van'da Klinik Örneklerde Listeriosis'in Varlığının Araştırılması

Özet: Listeriozis, dünya genelinde insanlar ve çeşitli hayvanlarda abortusa neden olan bir enfeksiyondur. Etken özellikle ruminant gibi çiftlik hayvanlarının dışkılarıyla saçılarak, kontamine silaj ve yemlerin sindirim yoluyla alınmasıyla bulaşan zoonoz karakterli bir özelliğe sahiptir. Bu çalışmada koyunlara ait 120 örnek (79 abort materyali, 41 beyin materyali) kullanılarak *Listeria* spp. varlığının araştırılması hedeflendi. Bu amaçla *Listeria* spp. için spesifik oligonükleotid çiftlerinin kullanıldığı polimeraz zincir reaksiyonu (PZR) yöntemi kullanıldı. Yapılan değerlendirmede Van ili ve ilçelerine ait abort materyallerinin tamamı negatif bulundu. Ancak klinik olarak sinirsel semptom gösteren koyunlardan Erciş ve Gevaş ilçelerinden birer tane olmak üzere toplam 2 (%4.87) adet örnekte pozitiflik saptandı.

Sonuç olarak abort etkenleri arasında yer alan *Listeria* spp.'nin Van ilinde sporadik seyrettiği belirlendi. Bu durumun Van il genelinde küçükbaş hayvancılıkta silaj kullanımının oldukça düşük olmasından kaynaklanabileceği kanaatine varıldı. Hastalığın yöredeki seyri için periyodik çalışmaların yapılması gerektiği düşünüldü.

Anahtar Kelimeler: *Listeria* spp., PZR, Silaj.

Introduction

Listeriosis is a sporadic or endemic bacterial infection of humans and animals caused by *Listeria (L.) monocytogenes* (Orsi and Wiedmann, 2016). It is known that the disease is a significant public health problem because it is widespread and zoonotic throughout the world. *Listeria* spp. is a Gram-positive, facultative intracellular pathogen widely found in the environment. The genus *Listeria* has 27 species identified so far and has a broad host spectrum including soil, water, vegetation and animals (Carlin et al., 2021). Although there are many apathogenic species of *Listeria* spp., *L. monocytogenes* is one of the food and feed-borne pathogens with a zoonotic character, mainly transmitted from ruminants. Although many apathogenic species of *Listeria* spp. *L. monocytogenes* is a food and feed-borne pathogen with a zoonotic character, mainly transmitted from ruminants (Diriba et al., 2021). It can cause various clinical infections in both humans and ruminants, including meningoencephalitis, metritis, abortion, septicaemia, mastitis, gastroenteritis and conjunctivitis. Metritis can cause neonatal septicaemia, abortion and stillbirths, mainly in the last trimester of pregnancy (Orsi and Wiedmann, 2016). Farm animals, especially cattle, sheep and goats, are frequently affected (Roberts and Wiedmann, 2003). In addition, clinically healthy animals can excrete *L. monocytogenes* into the environment, and therefore, farms are also considered natural reservoirs (Nightingale et al., 2004; Rodriguez et al., 2021). It has been reported that the pathogen spreads to the environment as an asymptomatic carrier after oral ingestion. In addition, consuming contaminated silage in farms is considered one of the primary sources of ruminant listeriosis, and it has been reported that outbreaks may occur in farms (Aslantaş et al., 2023; García et al., 2016). The ability of *L. monocytogenes* to tolerate adverse conditions related to temperature, humidity and atmospheric oxygen makes it difficult to eradicate the pathogen on farms and in food processing plants. Due to the high morbidity and mortality of *L. monocytogenes*, economic losses occur in animal husbandry. In addition, *L. monocytogenes* can enter the food production chain and pose a potential health risk to humans (Steckler et al., 2018).

Detecting *Listeria* species using conventional diagnostic methods such as culture, immunohistochemistry, and serology can be time-consuming, complex, and sometimes inconclusive (Blumer et al., 2011; Leclercq et al., 2014). Considering their epidemic and zoonotic potential, there is a need for improved diagnostic methods for the detection of abortion agents to prevent transmission to both humans and animals and to limit their spread among animals. PCR method is one of the methods with high sensitivity and specificity in the diagnosis of pathogens (Barkallah et al., 2014; Goy et al., 2009).

Considering the potential of the PCR method for the etiological diagnosis of abortion in ruminants, this study aimed to investigate the presence of *Listeria* spp. in sheep with nervous symptoms and abortion cases by PCR method.

Material and Methods

Ethical consideration: Ethical approval of the study was obtained from Van Yüzüncü Yıl University Animal Researches Local Ethics Committee (Decision no: 2023/ 09-08), Van, Turkey.

Material: In this study, various samples taken from 79 cases of abortion and 41 cases with neural symptoms detected in sheep reared in 8 districts in Van and its region between 2020-2022 were used. The distribution of the districts sampled in the study is presented in Table 1. In addition, brain tissue taken from 41 sheep necropsies showing neural symptoms were included in the study. The samples were brought to Van Yüzüncü Yıl University, Faculty of Veterinary Medicine, Department of Microbiology laboratory under a cold chain.

Table 1. Locations of the samples analysed.

District	Number of Animals Sampled	
	Aborted fetuses and sheep Samples	Samples of Nervous Symptoms
Edremit	4	3
Erciş	0	8
Gevaş	0	5
Gürpınar	4	6
İpekyolu	15	3
Muradiye	3	3
Özalp	46	9
Tuşba	7	4
Total	79	41

Reference culture: The study used the *L. monocytogenes* (ATCC 7646) reference strain as a positive control.

Method: Tissue samples were cut into small pieces with sterile forceps and a scalpel in the laboratory. Two hundred milligrams each were transferred into tubes containing 20% glycerin Brain Heart Broth (Merck, 1.10493) and homogenized in a tissue lyser (Qiagen, Tissue Lyser). All samples were stored at -20°C until DNA isolation.

DNA isolation and amplification: Genomic DNAs of the previously homogenized samples were isolated using a commercial genomic DNA isolation kit (Hydra, Genomic DNA Purification Kit, HY-GDNA-100, İstanbul/ Türkiye). Genomic DNA isolation protocol was applied as recommended by the company.

In the amplification of the samples used in the study, the genus-specific *prs* gene region of *Listeria* spp. for genus-level identification and the *hly* gene region defined as a specific genetic marker for the molecular identification of *L. monocytogenes* at the species level were used as primers (Table 2).

Table 2. Oligonucleotide sequences used in the study.

Agent	Target Gene	Product size (bp)	Oligonucleotide sequence (5'-3')	Reference
<i>Listeria</i> spp.	<i>prs</i>	370	F: CTGAAGAGATTGCGAAAGAAG R: CAAAGAAACCTTGGATTGCGG	(Doumith et al., 2004)
<i>L. monocytogenes</i>	<i>hyl</i>	456	F: GGGAAATCTGTCTCAGGTGATGT R: CGATGATTTGAACTTCATCTTTTGC	(Rodríguez-Lázaro et al., 2004)

For the preparation of the PCR mixture, 12.5 µl mastermix (Thermoscientific, 2X PCR Mastermix, K0171, Vilnius/Lithuania), 5 µl genomic DNA, 1.5 µl primers (F-R) and 4.5 µl PCR water (Bioshop, Canada) were used for a total reaction volume of 25 µl. In the amplification process for *Listeria* spp. using Thermal Cycler (Corbett Research, Qiagen GmbH, Sydney, Australia), the protocol of initial denaturation at 94 °C for 5 minutes, denaturation at 94 °C for 30 seconds, annealing at 55.5 °C for 45 seconds, extension at 72 °C for 45 seconds, final extension at 72 °C for 5 minutes for a total of 35 cycles was applied (Gülaydın et al., 2023).

In the amplification process for *L. monocytogenes*, after initial denaturation at 95 °C for 10 min, a 40-cycle protocol was applied as denaturation at 95 °C for 45 s, annealing at 63 °C for 45 s, and elongation at 72 °C for 45 s. Final elongation was performed at 72°C for 10 min.

DNA obtained from *the L. monocytogenes* (ATCC 7646) reference strain was used as a positive control, and deionized water was used as a negative control. The PCR amplicons were run on an agarose gel electrophoresis setup (Thermo Scientific, OwlR EasyCast™ B1, Ohio/ USA) using 2% agarose gel (Atlas, Ankara / Türkiye) and then analyzed under UV light in a Gel Imaging device (Genesis Spectronic®, USA).

Results

No positivity for *Listeria* spp. was detected in the 79 abortion samples examined in the study. However, in PCR analyses of brain samples taken from 41 sheep with neural symptoms, 2 (4.87%) positivities were detected, one each in the samples taken from Erciş and Gevaş districts (Figure 1).

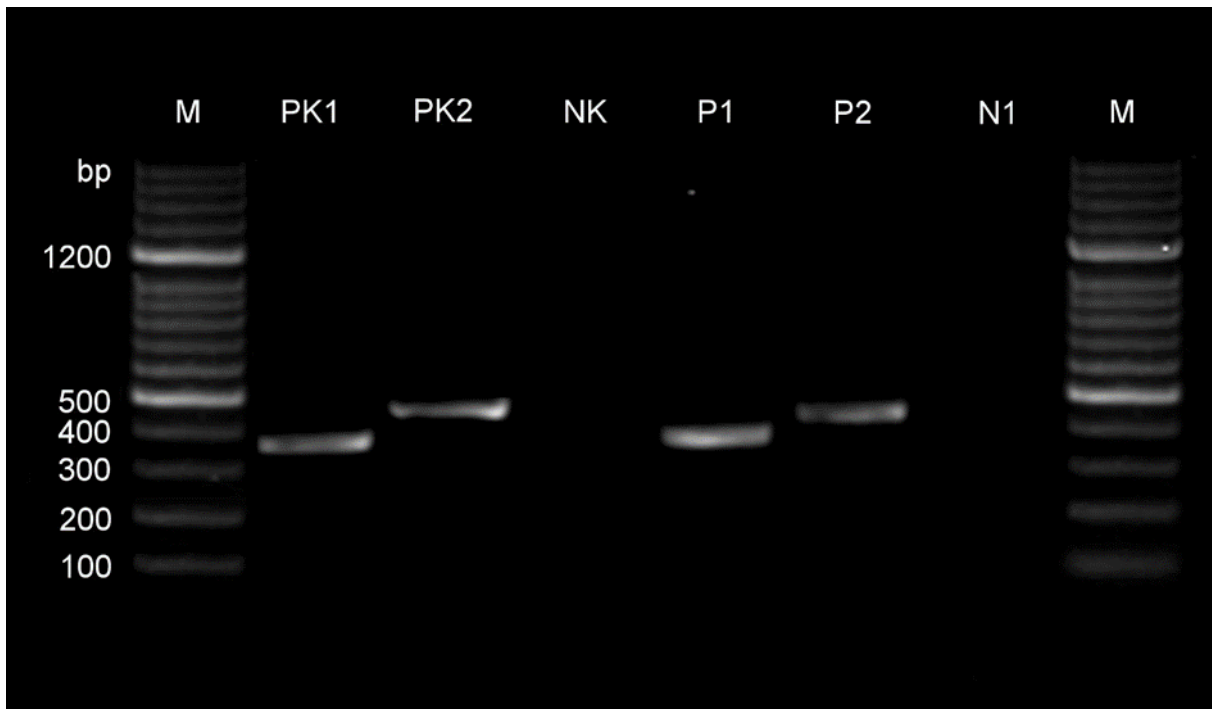


Figure 1. M: Ladder 100 bp marker (Vivantis); PK1: *Listeria* spp. Positive control; PK2: *L.monocytogenes* Positive control; NK: Negative control; P1: *Listeria* spp. Positive sample (370bp); P2: *L. monocytogenes* Positive sample (456bp); N1: Negative sample.

Discussion and Conclusion

Listeriosis is a highly prevalent zoonotic infectious disease reported in more than 40 animal species in different countries on six continents. It has become a significant health problem, especially in ruminants, and can be

transmitted to humans (Karakurt et al., 2021). It was emphasized that *Listeria* is one of the bacteria that should not be overlooked among the factors causing abortion (Yeni et al., 2024). Studies on seroprevalence and detection of listeriosis in ruminants in Van and its region are very few. In this study, it was aimed to investigate the presence of

Listeria spp. in clinical and necropsy samples taken from sheep with abortion and nervous symptoms in Van and its region by molecular methods.

It was stated that neural symptoms due to listerial meningoencephalitis are only seen in adult ruminants, and the pathogenesis is not fully understood (Koopmans et al., 2023). It was emphasized that listeriosis cases are frequently associated with silage-fed animals, and the disease usually occurs in winter and early spring (Gorski et al., 2022). In a study conducted in Burdur province, the brain tissues of 15 sheep with nervous symptoms were examined by immunohistochemical method. All of them were positive for *L. monocytogenes*, and 12 of the animals examined were fed silage (Haligur et al., 2019). Similarly, in a study conducted in Kars province, it was reported that *L. monocytogenes* was isolated and identified in 12 of the samples in cultural analyses of brain and liver tissues taken from 18 sheep and cattle with clinical symptoms, and positive samples were also confirmed by immunofluorescent staining method (Karakurt et al., 2021).

In Türkiye, there is very limited literature on which listeriosis has been investigated by PCR in aborted fetuses. This study detected 2 (4.87%) positivity for *L. monocytogenes* in PCR analyses of brain samples taken from 41 sheep with neural symptoms. In a study conducted by (Gülaydın et al., 2023), on the etiological analysis of abortion cases in sheep in Van and its region by PCR method, it was reported that the presence of *L. monocytogenes* was detected in only 1 (0.77%) of 130 abortion samples. Similarly, it was reported that *L. monocytogenes* was isolated and identified in only 1 (0.91%) of the samples taken from 110 sheep and goats that were aborted in Elazığ and its region, and serological positivity was not detected (Muz et al., 1999). Similarly, it was reported that *Listeria* spp. could not be detected by PCR method in 179 cattle and sheep abortus materials collected from nine cities in different regions of Turkey (Yeni et al., 2024). In another study, aborted tissues from 7 different regions of Turkey were analysed by PCR method. However, *L. monocytogenes* could not be detected (Sakmanoğlu et al., 2021).

On the other hand, in a seroprevalence study conducted in Adana, blood sera of 557 aborted cattle were analysed, and 162 (40.9%) of the samples were found to be positive for *L. monocytogenes* (Yagci Yucel et al., 2014). In another study, 42.85% of blood serum samples taken from aborted cattle in 40 different facilities in İzmir, Kırıkkale, and Tokat provinces were serologically positive for *L. monocytogenes* (Yildiz et al., 2009).

In this study, all 79 abortus samples analyzed using PCR were negative for *Listeria* spp. The agent could not be detected in Van and its region, because the disease is associated with silage, and silage feeding is very limited in the area. This may be because the disease is widespread in the region due to the good level of silage feeding in the provinces where the studies were conducted, or the positivity may be high due to the possibility of cross-reactions in serological analyses. According to Bergeys Manual, it has been reported that the antigenic structures of *Listeria* strains *staphylococci* and *enterococci* and *Escherichia*

coli bacteria can give cross-reactions due to antigenic proximity (Brenner et al., 2005). It was reported that silage feeding was applied in 7% of the fattening enterprises in Van province, 2% of which was in Erciş province, especially in cattle fattening (Budağ and Keçeci, 2013). Therefore, it is seen that listeriosis, which is reported among the causes of abortion, is sporadic in Elazığ region, similar to Van and its region.

Another reason for the region's low detection rate of listeriosis may be related to the method applied. It is thought that inhibitory substances, encountered mainly in the PCR method and caused by the lack of appropriate material, may be present in the samples used in this study, albeit to a lesser extent. In a related evaluation, it is claimed that IgG, lactoferrin, and hemoglobin, as well as anticoagulants such as heparin, inhibit PCR in blood samples used for PCR diagnosis of abortion cases. It has also been emphasized that protease activity in the blood may decrease PCR efficiency, and inhibitors in muscle tissues may inhibit all or part of Taq polymerase and cause false negative results (Kula and Gökpınar, 2018).

Inadequate sample collection is another factor contributing to the poor isolation rate of *Listeria* spp. In one study, it was stated that random sample collection in infections without adequate examination and clarification of the stage of the disease had a significant negative effect on the reliability of isolation and identification (Malik et al., 2002). Although this situation is not very likely for this study, it is more likely that the isolation rate is low due to the sporadic course of the disease.

In conclusion, it is essential to investigate the presence of zoonotic *Listeria* spp. in Van and its region to give direction to animal health and public health as well as disease control and prevention strategies. Although *Listeria* spp. was not detected in abortion samples in this study, the presence of the agent, which is frequently isolated from foodstuffs, should be routinely investigated and taken into consideration. This study demonstrated that listeriosis is still sporadic in Van and its region, and it was concluded that examination of the brain tissues of animals with neural symptoms would be beneficial.

Conflict of Interest

The authors declare that they have no conflict of interest or potential conflict of interest.

Ethical Approval

Ethical approval of the study was obtained from Van Yüzüncü Yıl University Animal Researches Local Ethics Committee (Decision no: 2023/ 09-08), Van, Turkey.

Funding

This study was supported by Van Yüzüncü Yıl University BAP Coordination Office with project number TYD-2023-10816.

Similarity Rate

We declare that the similarity rate of the article is %6 as stated in the report uploaded to the system.

References

- Aslantaş Ö, Büyükcaltay K, Keskin O, Güllü Yücecepe A, Adigüzel A, 2023: Gıda ve Hayvan Klinik *Listeria monocytogenes* İzolatlarının Tam Genom Dizilimine Dayalı Karakterizasyonu. *Kafkas Üniv Vet Fak Derg*, 29 (3), 221-230.
- Barkallah M, Gharbi Y, Hassena AB, Slima AB, Mallek Z, Gautier M, Greub G, Gdoura R, Fendri I, 2014: Survey of Infectious Etiologies of Bovine Abortion during Mid- to Late Gestation in Dairy Herds. *PLoS ONE*, 9 (3), e91549.
- Budağ C, Keçeci Ş, 2013: Van'da Büyükbaş Hayvan Besilerinde Kullanılan Yemler ve Besi Şekillerine İlişkin Bir Anket Çalışması. *Yüzüncü Yıl Üniversitesi Fen Bilimleri Enstitüsü Dergisi*, 18 (1-2), 48-61.
- Blumer S, Greub G, Waldvogel A, Hassig M, Thoma R, Tschuur A, Pospischil N A, 2011: Borel *Waddlia*, *Parachlamydia* and *Chlamydiaceae* in bovine abortion *Vet Microbiol*, 152, 385-393
- Brenner DJ, Krieg NR, Staley JT, Garrity GM, 2005: *Bergey's Manual of Systematic Bacteriology*, 2nd Edition, Vol. 2 (The Proteobacteria), part C (The Alpha-, Beta-, Delta-, and Epsilonproteobacteria), Springer, New York.
- Carlin CR, Liao J, Weller D, Guo X, Orsi R, Wiedmann M, 2021: *Listeria cossartiae* sp. Nov., *Listeria immobilis* sp. Nov., *Listeria portnoi* sp. Nov. And *Listeria rustica* sp. Nov., isolated from agricultural water and natural environments. *Int J Syst Evol Microbiol*, 71 (5), 004795.
- Diriba K, Awulachew E, Diribsa K, 2021: The prevalence of *Listeria* species in different food items of animal and plant origin in Ethiopia: A systematic review and meta-analysis. *Eur J Med Res*, 26 (1), 60.
- Doumith M, Buchrieser C, Glaser P, Jacquet C, Martin P, 2004: Differentiation of the Major *Listeria monocytogenes* Serovars by Multiplex PCR. *J Clin Microbiol*, 42 (8), 3819-3822.
- García JA, Micheloud JF, Campero CM, Morrell EL, Odriozola ER, Moreira AR, 2016: Enteric listeriosis in grazing steers supplemented with spoiled silage. *J Vet Diagn Invest, Inc*, 28 (1), 65-69.
- Gorski L, Cooley MB, Oryang D, Carychao D, Nguyen K, Luo Y, Weinstein L, Brown E, Allard M, Mandrell RE, Chen Y, 2022: Prevalence and Clonal Diversity of over 1,200 *Listeria monocytogenes* Isolates Collected from Public Access Waters near Produce Production Areas on the Central California Coast during 2011 to 2016. *Appl Environ Microbiol*, 26, 88 (8).
- Goy G, Croxatto A, Posfay-Barbe KM, Gervais A, Greub G, 2009: Development of a real-time PCR for the specific detection of *Waddlia chondrophila* in clinical samples. *Eur J Clin Microbiol Infect Dis*, 28 (12), 1483-1486.
- Gülaydın Ö, Öztürk C, Ekin İH, İlhan Z, İlhan F, 2023: Investigation of selected bacterial agents causing sheep abortion in the Van Province by RT-PCR and histopathological methods. *Acta Vet Brno*, 92 (1), 69-77.
- Haligur M, Aydoğan A, Özmen O, Ipek V, 2019: Immunohistochemical evaluation of natural cases of encephalitic listeriosis in sheep. *Biotech Histochem*, 94 (5), 341-347.
- Karakurt E, Büyük F, Dağ S, Beytut E, Çelebi Ö, Karataş Ö, Nuhoglu H, Mendil AS, Akça D, Yıldız A, 2021: Investigation of Ruminant Encephalitic and Septicemic Listeriosis by the Immunofluorescence Method. *J Etlik Vet Microbiol*, 32 (1), 33-39.
- Koopmans MM, Brouwer MC, Vázquez-Boland JA, van de Beek D, 2023: Human Listeriosis. *Clin Microbiol Rev.*, 23, 36 (1).
- Kula D, Gökpinar S, 2018: Polimeraz Zincir reaksiyonu (PZR) İnhibitörleri. *Animal Health Prod and Hyg*, 7 (2), 599-604.
- Leclercq A, Oevermann A, Danguy-des-Dé serts R, Granier S, Hammack T, Jinneman K, et al., 2014: *Listeria monocytogenes*. Chapitre 2.9.7. In *OIE Terrestrial Manual*. OIEWorld Organization for Animal Health (OIE), Paris
- Malik SVS, Barbudde SB, Chaudhari SP, 2002: Listeric Infections in Humans and Animals in the Indian Subcontinent: *Trop Anim Health Prod, A Review*, 34 (5), 359-81.
- Muz A, Özer H, Eröksüz H, Ertaş HB, Öngör H, Gülcü HB, Dabak M, Başbuğ O, Kalender H, 1999: Elazığ ve Çevresinde Koyun ve Keçilerde Abortus Olgularının Bakteriyolojik, Serolojik ve Patolojik Olarak incelenmesi. *Tr J Vet Anim Sci*, 23 (1), 177-188.
- Nightingale KK, Schukken YH, Nightingale CR, Fortes ED, Ho AJ, Her Z, Grohn YT, McDonough PL, Wiedmann M, 2004: Ecology and Transmission of *Listeria monocytogenes* Infecting Ruminants and in the Farm Environment. *Appl Environ Microbiol*, 70 (8), 4458-4467.
- Orsi RH, Wiedmann M, 2016: Characteristics and distribution of *Listeria* spp., including *Listeria* species newly described since 2009. *Appl Microbiol Biotechnol*, 100 (12), 5273-5287.
- Roberts AJ, Wiedmann M, 2003: Pathogen, host and environmental factors contributing to the pathogenesis of listeriosis. *Cell Mol Life Sci*, 60 (5), 904-918.
- Rodríguez C, Taminiou B, García-Fuentes E, Daube G, Korsak N, 2021: *Listeria monocytogenes* dissemination in farming and primary production: Sources, shedding and control measures. *Food Control*, 120, 107540.
- Rodríguez-Lázaro D, Hernández M, Pla M, 2004: Simultaneous quantitative detection of *Listeria* spp. And *Listeria monocytogenes* using a duplex real-time PCR-based assay. *FEMS Microbiol Lett*, 233 (2), 257-267.
- Sakmanoğlu A, Uslu A, Sayın Z, Gölen GS, İlhan A, Padron-Perez B, Karyeyen Y, Gök A, Tekindal MA, Erganis O, 2021: A one-year descriptive epidemiology of zoonotic abortifacient pathogen bacteria in farm animals in Turkey. *Comp. Immunol. Microbiol Infect Dis*, 77, 101665.
- Steckler AJ, Cardenas-Alvarez MX, Townsend Ramsett MK, Dyer N, Bergholz TM, 2018: Genetic characterization of *Listeria monocytogenes* from ruminant listeriosis from different geographical regions in the U.S. *Vet Microbiol*, 215, 93-97.
- Yagci Yucel S, Yaman M, Kurt C, Babur C, Celebi B, Kilic S, Ozen D, 2014: Seroprevalance of Brucellosis, Listeriosis and Toxoplasmosis in Cattle in Adana Province of Turkey. *Turkiye Parazitoloj Derg*, 38 (2), 91-96.
- Yeni DK, Balevi A, Ashraf A, Shah Ms, Büyük F, 2024: Molecular detection of bacterial zoonotic abortive agents from ruminants in Turkey. *Braz J Microbiol*, Mar 12.
- Yıldız K, Kul O, Babur C, Kilic S, Gazyagcı AN, Celebi B, Gurcan IS, 2009: Seroprevalence of *Neospora caninum* in dairy cattle ranches with high abortion rate: Special emphasis to serologic co-existence with *Toxoplasma gondii*, *Brucella abortus* and *Listeria monocytogenes*. *Vet Parasitol*, 164 (2-4), 306-310.



Capsular Tension Ring and Iris Hook Use in The Management of Cataract with Phacoemulsification Method in Dogs

Osman BULUT^{1,a,*}, Ayşe İpek AKYÜZ ÜNSAL^{2,b}, Ali BELGE^{3,c}

¹Mugla Sitki Kocman University, Faculty of Milas Veterinary Medicine, Department of Surgery, Mugla, Türkiye.

²Aydın Adnan Menderes University, Faculty of Medicine, Department of Ophthalmology, Aydın, Türkiye.

³Aydın Adnan Menderes University, Faculty of Veterinary Medicine, Department of Surgery, Aydın, Türkiye.

^aORCID: 0000-0003-2773-8243;

^bORCID: 0000-0001-5260-674X;

^cORCID: 0000-0003-3346-6926;

Received: 01.04.2024

Accepted: 06.05.2024

How to cite this article: Bulut O, Akyüz Ünsal AI, Belge B. (2024). Capsular Tension Ring and Iris Hook Use in The Management of Cataract with Phacoemulsification Method in Dogs. Harran Üniversitesi Veteriner Fakültesi Dergisi, 13(1): 68-75. DOI:10.31196/huvfd.1462824.

***Correspondence:** Osman BULUT

¹Mugla Sitki Kocman University, Faculty of Milas Veterinary Medicine, Department of Surgery, Mugla, Türkiye.

e-mail: obulut@mu.edu.tr

Available on-line at: <https://dergipark.org.tr/tr/pub/huvfd>

Abstract: The purpose of this study is to evaluate the surgical outcome of capsular tension ring and iris hook use during phacoemulsification in dogs with zonular weakness and miotic pupils. This study includes nineteen dogs (29 eyes) that underwent phacoemulsification (15 dogs/25 eyes) and extracapsular cataract extraction surgery (4 dogs/4 eyes) between February 2014 and February 2015. Patients with any ophthalmic problem other than cataracts were not included in the study. Some dogs did not achieve pharmacologic pupil dilation. These dogs required the use of iris hooks or the insertion of capsular tension rings. The capsular tension ring insertion was used in dogs with zonular rupture in more than half of the zonules. Capsular tension rings were inserted in cases of zonular dialysis and iris hooks were placed to widen the pupil. Fifteen dogs (25 eyes) underwent phacoemulsification, while 4 (4 eyes) received extracapsular cataract extraction (ECCE) surgery due to the difficulty of phacoemulsification in hypermature cataracts. Iris hooks were used in four dogs (8 eyes) for drug-resistant miotic pupils. Capsular tension rings were inserted to stabilize the lens capsule during phacoemulsification and to centralize the intraocular lens (IOL) in the bag. Capsular tension rings in cases of zonular dialysis and iris hooks in drug-resistant miotic pupils improved the success of cataract operations with phacoemulsification. Both are safe and useful for zonular weakness and for maintaining mydriasis during surgery.

Keywords: Canine, Extracapsular cataract extraction (ECCE), Intraocular lens, Mydriatics, Zonular weakness.

Köpeklerde Fakoemülsifikasyon Tekniği ile Katarakt Cerrahisinde Kapsül Germe Halkası ve İris Kancası Kullanımı

Özet: Bu çalışmanın amacı, miyotik pupilla ve zonuler zayıflığa sahip köpeklerin fakoemülsifikasyon operasyonunda, kapsül germe halkası ve iris kancalarının kullanımının cerrahi sonuçlarını değerlendirmektir. Çalışmanın materyalini, Şubat 2014 ve Şubat 2015 tarihleri arasında, katarakt cerrahisi için fakoemülsifikasyon (15 köpek/25 göz) ve ekstrakapsüler katarakt ekstraksiyonu (EKKE) (4 köpek/4 göz) uygulanan toplam 19 köpek oluşturdu. Katarakt harici başka bir göz hastalığı olanlar çalışmaya dahil edilmedi. Operasyonlar sırasında pupillada miyosis şekillenen bazı köpeklere iris kancaları, zonüler zayıflığı olanlara ise kapsül germe halkası yerleştirildi. Kapsül germe halkaları aynı zamanda lens kapsülü stabil hale getirmek ve intraokuler lense (İOL) kapsül içinde sentralize etmek için kullanıldı. Miyosis şekillenen toplam 4 köpekte (8 göz) iris kancaları kullanıldı. Fakoemülsifikasyon işlemi ile katarakt ekstraksiyonu gerçekleştirilemeyen 4 köpekte EKKE uygulandı. Zonüler zayıflık için kapsül germe halkaları ile pupillar miyosis karşı iris kancaları kullanımının katarakt operasyonlarının başarısını arttırdığı tespit edildi.

Anahtar Kelimeler: Ekstrakapsüler katarakt ekstraksiyonu (EKKE), İntroakuler lens, Köpek, Midriyatiks, Miyosis, Zonuler zayıflık.

Introduction

Cataract is a frequent and common eye disease in canines as well as other animals and the leading cause of blindness (Chen et al., 2023). The most effective treatment is to remove the affected lens material and, if appropriate, replace it with an artificial intraocular lens (IOL) (Dowler et al., 2021). Phacoemulsification is the most popular method due to its high success rates, but it can be affected by drug-resistant miotic pupils, zonular weakness or dialysis, and postoperative posterior capsule opacification, which can impact the short and long-term success (Edelmann et al., 2022).

During phacoemulsification, miotic pupil size can affect lens visualization and cause complications like posterior capsule rupture, potentially leading to nuclear fragments falling into the vitreous (Newbold et al., 2015). If miotics are insufficient to enlarge the small pupil, simple iris dilating techniques, sphincterotomy, iris retractors, or pupil expanders are recommended to simplify the surgery (Sigle and Nasisse, 2006). The iris hooks are inserted into the iris and then gently pulled to stretch and hold the iris open, allowing the surgeon to access the lens. This can be especially helpful in cases where the pupil is too small or not responding to medication that would typically be used to dilate it (Alagoz et al., 2009).

Capsular tension rings (CTR) during phacoemulsification surgery help distribute the force received by the zonules evenly around the circumference. These rings help to stabilize the lens during phacoemulsification surgery. They also inhibit late-term lens epithelial cell migration and prevent decentration. CTR use during phacoemulsification in dog eyes is limited in the literature also (Santosh et al., 2019; Wilkie et al., 2015).

The present study aims to report the outcome of cases undergoing lens extraction surgery via phacoemulsification or extracapsular cataract extraction (ECCE) in dogs. This study conducted capsular tension ring and iris hook use in case of zonular weakness and miotic pupils that are resistant to pharmacologic dilation, respectively.

Materials and Methods

Ethical Statement: The ethical approval of the study was provided by Aydin Adnan Menderes University's Institutional Animal Care and Use Committee (approval number: 2014-075). In this study, a signed information confirmation form was obtained from the patient owners.

Animals: The study material consisted of nineteen dogs (29 eyes) of different ages (mean age 9.75 ± 6.25 years), species, and genders (13 female, 6 male), which were referred to Aydin Adnan Menderes University, Faculty of Veterinary Medicine, Department of Surgery for cataract surgery. Phacoemulsification was performed on 25 eyes of 15 dogs. ECCE surgery was performed on 4 eyes of 4 dogs, due to the challenges of phacoemulsification in cases of hypermature cataracts. Therefore, a total of 29 eyes from nineteen dogs were included in the study.

Clinical Examinations and Anesthesia: An anamnesis, ophthalmoscopic inspection, and reflex examination were performed. Mydriatic was administered to the dogs, and the entire lens was examined with ophthalmoscopy, leading to a diagnosis of cataract. As mature and hypermature cataracts did not allow for retina examination, ultrasonography was performed to check for possible retinal detachment or vitreous hemorrhage. Ten dogs had senile, 8 had traumatic and 1 had metabolic (diabetic) cataracts. Three of them were immature, 7 of them were hypermature and 19 of them were mature morphologically in 29 eyes.

All animals diagnosed with cataracts and scheduled for operative intervention are recommended to use corticosteroid drops (1% prednisolone sodium phosphate, Norsol®, Mefar İlaç Sanayi A.Ş., Türkiye) and antibiotic drops (0.3% ofloxacin, Exocin®, Allergan AbbVie Company, Ireland) five times a day, two drops in each eye, starting seven days before the surgery to the day of the operation to prevent secondary uveitis. To achieve mydriasis, topical tropicamide 0.5% (Tropamid®, Mefar İlaç Sanayi A.Ş., Türkiye), phenylephrine HCl 2.5% (Mydfrin®, Alcon Laboratories Ticaret A.Ş., Türkiye), and cyclopentolate HCl 1% (Sikloplejin®, Abdi İbrahim İlaç Sanayi ve Ticaret A.Ş., Türkiye) were applied at 10-minute intervals, respectively. After adequate mydriasis was achieved, the dogs were anesthetized. Induction of all cases was achieved by intramuscular injection of atropine sulfate 2% (Atropin® %2, Deva Holding A.Ş., Türkiye) at a dose of 0.045 mg/kg, xylazine hydrochloride 2% (Alfazyne® %2, Alfasan International, Holland) at a dose of 1-2 mg/kg, and ketamine hydrochloride 10% (Alfamine® 10%, Alfasan International, Holland) at a dose of 11 mg/kg. After induction, the patients were intubated and general anesthesia was maintained with 1-3% isoflurane (Isoflurane®, Piramal Critical Care, USA).

Surgery Technique: After intubation, the dogs were placed in a decubitus position on the operating table. The head, cornea, and eyeball were positioned under the operating microscope parallel to the ceiling (Fig. 1). The hair

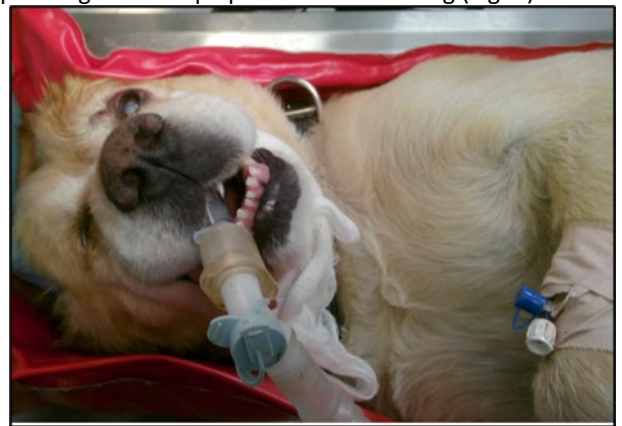


Figure 1. The decubitus position of the patient under a microscope.

around the eyelids was shaved, and the skin was cleaned with a 5% povidone-iodine solution. The ocular surface was irrigated with physiological saline after the instillation of 0.5-

1% povidone-iodine (Povidine®, Toseil İlaç Sanayi A.S, Türkiye) solution. To manipulate the eyeball, 4/0 non-absorbable silk material was placed in the superior rectus as a sling.

The operation started with a 1.1 mm wide side-port incision from the limbus at the 3 and 9 o'clock positions (Fig. 2a). Trypan blue 0.06% (Ocublu®, Miray Medical, Türkiye) was directly applied onto the anterior capsule of the lens to stain it in mature cataracts after injecting an air bubble into the anterior chamber from the temporal side port, with a dosage ranging from 0.5 to 1.5 ml. (Fig. 2b). Three seconds later, the anterior chamber was irrigated with Ringer lactate solution (Polifleks Laktat Ringer®, Polifarma İlaç Sanayi ve Tic. A.Ş, Türkiye) to eliminate the toxic effect of Trypan blue on corneal endothelial cells. To maintain anterior chamber depth, viscoelastic material (Bio-Hyalur SV®, BioTech, India) was injected (Fig. 2c).

Following a 2.8 mm main entrance incision at 12 o'clock, a tear was created on the capsule with a cystotome (Fig 3a). A smooth 360-degree circular opening was created in the center of the anterior capsule by holding the edge of this tear with utrata forceps (Fig. 3b, 3c). Attention was paid to ensuring the diameter of the capsulorhexis was 1 mm smaller than the optic diameter of the IOL to be inserted. The capsule and the lens were separated from each other using a flat-ended 27G hydro dissection cannula. (Fig. 3d). The lens was rotated within the capsule to ensure that hydro dissection had occurred.

After hydro dissection, the phaco device (MTP 2000 phacoemulsifier, USA) was operated at 30 joules of ultrasound energy, 50 watts of aspiration power, and 450 mmHg vacuum. The lens was dissected using the phaco-chop technique with the help of a phaco chopper and the nucleus was fragmented and emulsified (Fig. 4a, 4b, 4c). In 4 cases where there was a posterior capsule rupture and wide zonular dialysis extending to 180 degrees, the corneal incision was enlarged, and the cataract was extracted using the extracapsular cataract extraction (ECCE) technique (Fig. 5).

In cases with insufficient pupillary dilatation and zonule weakness (Fig. 6a), iris hooks (IrisCare, Madhu Instruments,

India) were placed through both side ports. Additionally, new small side ports at 1, 4, and 5 o'clock positions to achieve pupil dilation. The plugs at the end of the iris hooks were pulled towards the free end and inserted through the incision. After the hook part was attached to the iris and the capsule, the plug was pushed towards the hook and placed in front of the cornea. The iris hooks were attached to the edge of the capsulorhexis to reduce the strain on the zonules and simultaneously dilate the pupil (Fig. 6b, 6c). Placement of the iris hooks in these positions allowed for the successful completion of the phacoemulsification stage by providing adequate pupil dilation.

In addition to iris hooks, a 13 mm capsular tension ring (CTR, Freedom Capsular Tension Ring, India) was placed inside the capsule to support the zonules in cases of zonular weakness. The CTR was inserted after cortical aspiration and before IOL implantation, using tying forceps in both hands without a CTR injector. One open end of the CTR was slowly guided into the capsule. When inserting the CTR follow the curvature of the capsule bag. The y-tipped manipulator was inserted into the hole and supported the ring as the ring was placed into the correct position. The CTR was useful during the IOL implantation stage for the IOL stabilization and centralization (Fig. 7).

Residual cortical material was removed using irrigation/aspiration cannulas which were inserted from the side ports at 450-600 mmHg aspiration parameters (Fig. 8a). Once the stability of the anterior chamber was achieved, 1–1.5 ml of 1% Na-hyaluronate (Bio-Hyalur SV®, BioTech, India) was injected into the anterior chamber and a foldable 41 D hydrophilic-acrylic IOL (Eyecryl Plus, BioTech, India) was inserted through the 3.2 mm incision with an IOL injector (Fig. 8b). After the IOL implantation, the viscoelastic material was removed using an irrigation-aspiration procedure. The corneal incisions were closed by hydrating the corneal edges of the incisions for anterior chamber stabilization. Corticosteroid drops (%0.1 dexamethasone, Maxidex®, Alcon Couvreur N.V, Belgium) and antibiotic drops (0.3% ciprofloxacin, Ciloxan®, Rijksweg, Belgium) were injected into the anterior chamber at a dose of 0.3 mL to prevent possible infection and inflammation (Fig. 8).

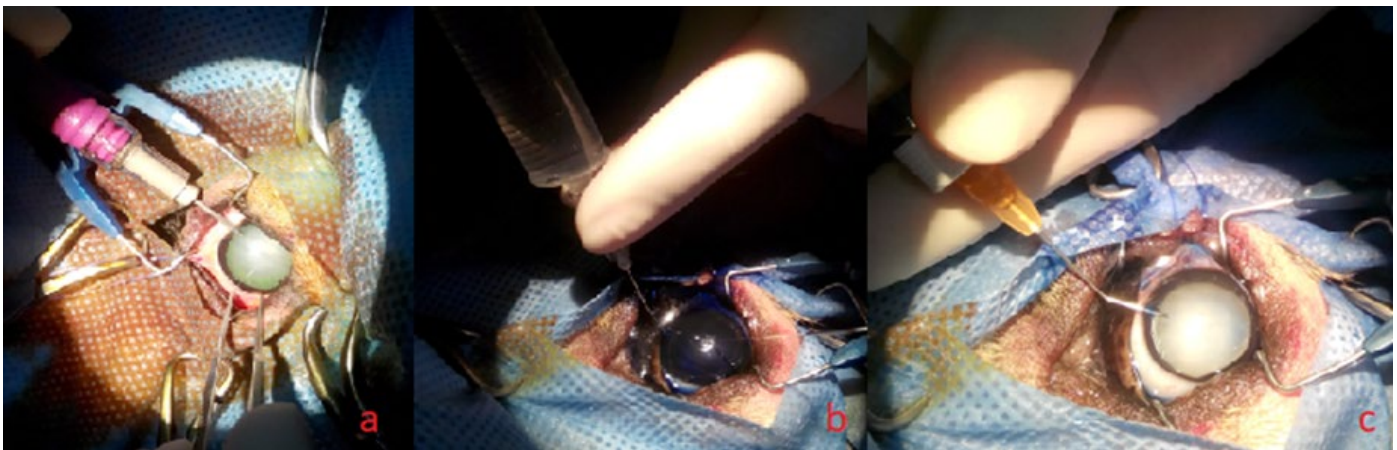


Figure 2. a: Side-ports at 3 and 9 o'clock, b: Trypan blue injection under air bubble, c: injection of viscoelastic material.

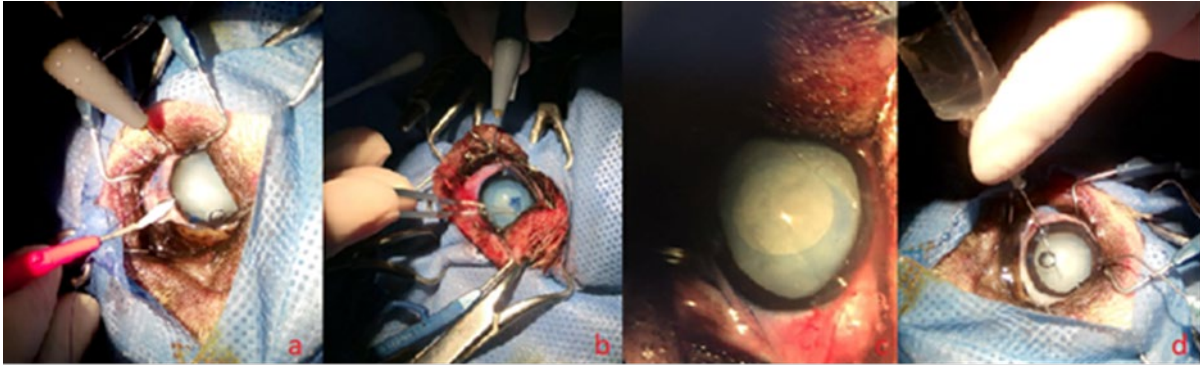


Figure 3. a: Main incision at 12 o'clock, b: Capsulorhexis procedure, c: Circumferential curvilinear capsulorhexis of the lens capsule, d: Hydrodissection of the lens from the capsule.

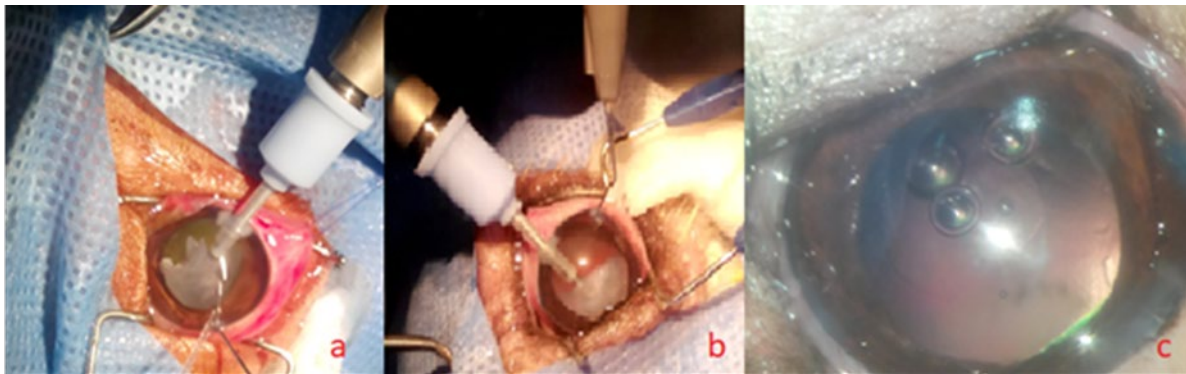


Figure 4. Steps of phacoemulsification (Phaco-chop technique).

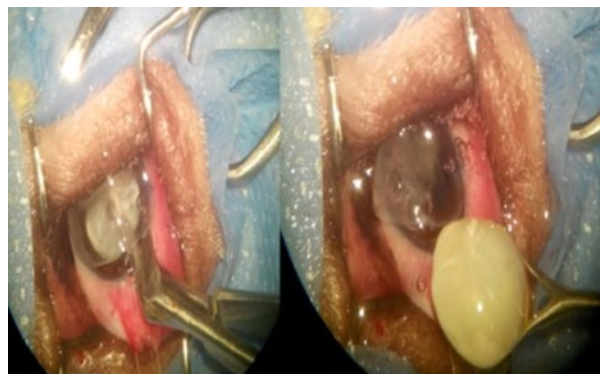


Figure 5. The stages of ECCE.

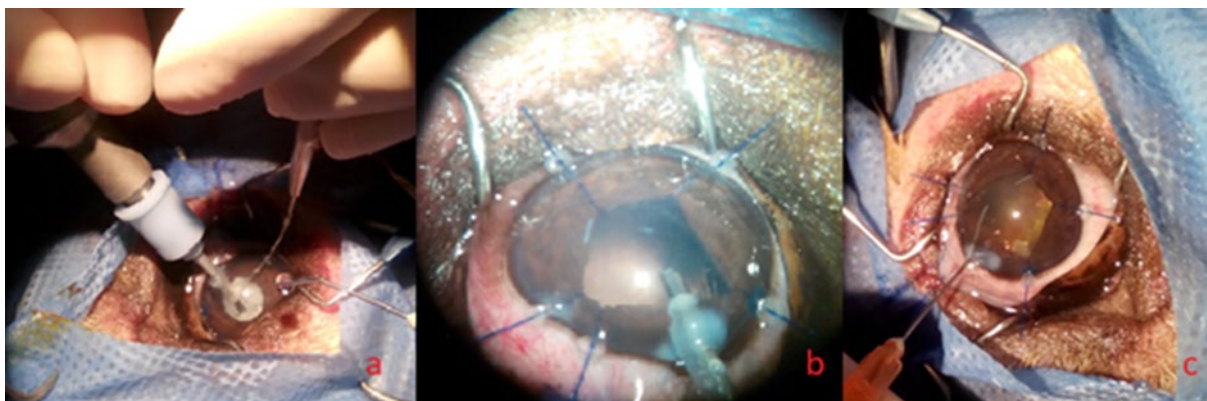


Figure 6. a: Pupillary miosis during phacoemulsification, b-c: Iris hooks.

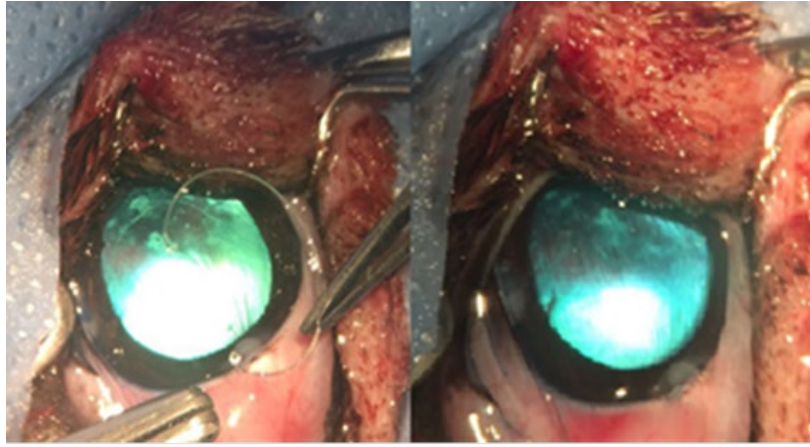


Figure 7. Implantation of CTR

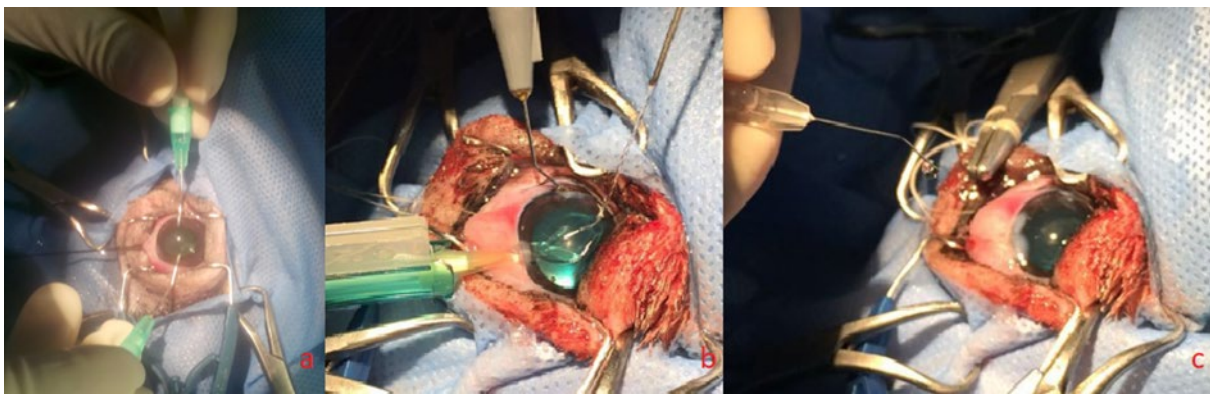


Figure 8. a: Irrigation aspiration of cortex materials, b: Implantation of IOL, c: The closure of the incisions with corneal hydration.

Results

In our study, phacoemulsification was performed in 15 (25 eyes) cases and ECCE was performed in 4 cases (4 eyes) for cataract surgery. IOL was implanted in 13 cases (23 eyes) after phacoemulsification and in 1 case (1 eye) after ECCE, while 5 cases were left aphakic. The demographic data of the dogs are summarized in Table 1. Plausible improvement in vision was reported by the owners and confirmed by clinical examinations in 14 cases. However, in 5 cases, a slight improvement in vision was not achieved due to postoperative complications such as corneal edema, bullous keratopathy, anterior uveitis, formation of posterior pupillary membrane, anterior synechia, glaucoma, and posterior capsule opacification in the early postoperative period.

Intraoperative complications and management strategies: In four of our cases (8 eyes), mydriatic drugs were unable to achieve mydriasis. Therefore we placed iris hooks through the side ports at the edge of the iris and capsulorhexis borders to continue phacoemulsification. Iris hooks supported the capsule and dilated the pupil, allowing us to perform phacoemulsification safely.

In 14 cases (24 eyes), the capsulorhexis was performed in a circular shape and desired size, while in 5 cases (5 eyes), it was small and asymmetric due to zonular weakness. In those cases, we implanted CTR to support lens zonules and

avoid anterior chamber collapse during high vacuum. After lens removal, CTR was implanted in the capsule bag to centralize the IOL.

It was challenging to break the nucleus in 2 hypermature cases, so we had to use high ultrasound power and vacuum. Unfortunately, the increased ultrasound power led to a corneal burn approximately 2x2 mm in size at the main incision site. It has been revealed that high ultrasonic power and vacuum should not be used for performing phacoemulsification in cases of hypermature cataracts.

The anterior chamber was shallow at the end of the IOL implantation in 6 cases, so we tied the main corneal incision to cease the leakage and maintain anterior chamber depth. While in 13 cases, corneal hydration was enough to stabilize the anterior chamber.

As indicated in the literature, some complications were encountered after the phacoemulsification operation. Corneal edema was observed in all cases. However, bullous keratopathy was seen only in one patient in the late postoperative period. Anterior uveitis, anterior synechia, and pupillary membrane developed in 3 cases. Posterior capsule opacification developed in the late period in one of our patients and decreased the visual outcome. Intraocular pressure did not elevate in any of our patients, but retinal detachment was seen in one case. Endophthalmitis did not develop in any of the patients. With these results in 5 cases, a slight improvement in vision was not achieved.

Table 1. Demographic data of the dog patients.

Case No	Species	Etiology	Stage of the Cataract	
			Right Eye	Left eye
1	Terrier	Senile	Mature cataract	Mature cataract
2	Terrier	Senile	Hyperature cataract	Hyperature cataract
3	Golden Retriever	Traumatic	-	Hyperature cataract
4	Spaniel Cocker	Senile	Mature cataract	Mature cataract
5	Husky	Senile	Mature cataract	Mature cataract
6	Pinscher	Senile	Mature cataract	Hyperature cataract
7	Golden Retriever	Traumatic	Immature cataract	Hyperature cataract
8	Terrier	Senile	Hyperature cataract	Hyperature cataract
9	Pinscher	Senile	Mature cataract	Hyperature cataract
10	Terrier	Senile	Mature cataract	Mature cataract
11	Golden Retriever	Traumatic	Immature cataract	Mature cataract
12	Pug	Traumatic	Mature cataract	Mature cataract
13	Spaniel Cocker	Senile	Mature cataract	Mature cataract
14	Golden Retriever	Senile	Mature cataract	Mature cataract
15	Terrier	Metabolic	Mature cataract	Mature cataract
16	Chihuahua	Traumatic	Mature cataract	Immature cataract
17	Spaniel Cocker	Traumatic	Mature cataract	Mature cataract
18	Pug	Traumatic	Mature cataract	Mature cataract
19	Spaniel Cocker	Traumatic	Mature cataract	Mature cataract

Discussion and Conclusion

The goal of cataract surgery is to preserve the integrity of the eye and achieve the best possible visual outcomes with minimal complications. The utilization of the phacoemulsification method in cataract surgery is growing in popularity due to its various advantages. These include reducing the surgical duration, enabling smaller incisions, and facilitating faster postoperative visual recovery. Additionally, this method enables the implantation of an IOL to correct postoperative aphakia (Newbold et al., 2015).

Intraoperative complications of cataract surgery include posterior capsule rupture, which is the most common intraoperative complication associated with phacoemulsification in dogs (Johnstone and Ward, 2005). The posterior capsule tears usually occur due to excessive manipulation in difficult cases. The vitreous may move anteriorly and cause several complications such as ocular hypertension, retinal detachment, bacterial contamination, endophthalmitis, and decentralization of intraocular lens implants. If the posterior capsule is perforated during surgery, a vitrectomy can be performed to reduce the risk of glaucoma (Maggs et al., 2010). We performed anterior vitrectomy on our patients after posterior capsule rupture to avoid the aforementioned complications.

Small pupils, or miotic pupils, can be a challenge during cataract surgery. Myotic pupils have various reasons such as aging, posterior synechiae, trauma, chronic use of miotics, diabetes, syphilis, pseudoexfoliation, and uveitis (Dularent et al., 2023; Kershner, 2002). Additionally, factors such as prolonged time for corneal incision and anterior capsulotomy, frequent iris touch, excessive use of irrigation fluid during phacoemulsification, and prolonged surgery time may also contribute to small pupil formation (Saroglu,

2013). In cases where mydriatics are insufficient to enlarge the small pupil, various techniques such as simple iris dilating techniques, sphincterotomy, iris retractors, or pupil expanders are recommended (Vasavada and Singh, 2000). In human eyes, iris hooks are widely used to mechanically dilate the pupil and prevent complications (Balal et al., 2021; Nderitu and Ursell, 2019). However, there is limited literature on the use of iris hooks in canine eyes. In our study, we encountered resistant miosis in 4 cases (8 eyes) during phacoemulsification, which may have been due to iris touch and prolonged surgery time. In these cases, we used iris hooks to dilate the pupil and were able to complete the surgery successfully. We hope that sharing our experiences with the use of iris hooks can help other veterinary surgeons facing similar challenges during cataract surgery.

The CTR was first introduced in 1991 and was used in the first human eye during cataract surgery in 1993. The CTR is an open band-shaped ring made of polymethyl methacrylate (PMMA). The ring dimensions are 0.2 mm in thickness, 0.7 mm in width, 11.0 mm in diameter when closed, and 13.0 mm in diameter when open (Nishi et al., 1998). It was designed to be permanently implanted into the capsular bag and has blunt-tipped eyelets on both ends (Bayraktar et al., 2001). CTR may mechanically compress the capsule and shorten the distance between the IOL and capsular bag due to its square cross-section and sharp edges. Thus, according to some researchers, it inhibits the migration of lens epithelial cells (LECs) and retards the development of posterior capsular opacification (Menapece et al., 2008). In the literature, the use of CTR during surgery reduced the risk of posterior capsule rupture. This study compared two canine groups with CTR and without CTR in phacoemulsification (Wilkie et al., 2015). Some researchers reported the usefulness of the CTR in the prevention of

posterior capsule opacification till the 210th day of the postoperative period (Santosh et al., 2019). However, both studies did not provide information on the intraoperative benefits of the CTR in difficult cases such as zonular weakness. Many investigators implanted CTR before phacoemulsification (Jacob et al., 2003; Ma and Li, 2014), while others implanted CTR after cortical aspiration and before IOL implantation (Ahmed et al., 2005; Praveen et al., 2003). In our study, we used the CTR in both stages depending on the amount of zonular dialysis and phacodonesis. The implantation of CTR allowed us to continue phaco safely and to implant IOL in the center of the bag. Additionally, the posterior capsule opacification rate was quite low in the early postoperative period.

The hydrophobic or hydrophilic structure of intraocular lenses made of silicone is important. Although hydrophobic acrylic IOLs have a lower incidence of posterior capsule opacification and better biocompatibility, they can cause phimosis or severe opacification at the anterior capsule edge. On the other hand, hydrophilic acrylic IOLs have a higher incidence and severity of posterior capsule opacification, but less lens epithelial cell metaplasia and anterior capsule fibrosis (Kugelberg et al., 2006). In our study, 14 out of 19 cases (24 eyes) had hydrophilic acrylic IOLs implanted, while 5 cases were left aphakic. Contrary to the literature, in the acute phase, phimosis was observed very quickly in the anterior capsule within the first 0-6 hours, but uveitis and pupillary membrane decreased afterward. No posterior capsule opacification was observed in any of the cases.

Following cataract surgery, several complications may be encountered, albeit not necessarily common. These complications include lagophthalmos, corneal ulceration, iris bombe, corneal opacities, chemosis, hypopion, focal posterior synechiae, capsular phimosis, glaucoma, retinal detachment, corneal edema, and endophthalmitis (Sigle and Nassis, 2006). In all cases, corneal edema was observed after surgery. These complications are thought to be due to intraoperative complications such as deterioration of endothelial pump function as a result of high ultrasonic energy, high vacuum values, and long working hours. Also the failure of the pet owners to comply with the postoperative medical treatment procedures. To treat corneal edema, a 5% NaCl solution was instilled in the cornea in the postoperative period. Corneal edema disappeared by the end of the second week in the phaco group, while in those undergoing ECCE for hypermature cataracts, this period was extended.

Dogs are living longer due to the efforts of conscious dog owners who provide good living conditions for their pets. However, there is often a lack of sensitivity when it comes to scheduling routine eye examinations for dogs. This can lead to the detection of cataracts in very advanced stages and increase the risk of complications during surgery. In this study, we aimed to present the short-term results of using iris hooks and capsular tension rings in cases of resistant pupillary miosis, small pupils, and zonular weakness, which are the primary causes of complications. While a limited number of reports have shown that capsular

tension rings can also prevent posterior capsular opacification in the long term, preventing the formation of this opacity is crucial for providing dogs with visual rehabilitation for many years. We believe that randomized controlled clinical studies with larger participant populations and long-term results are necessary.

Conflict of Interest

The authors stated that they did not have any real, potential or perceived conflict of interest.

Ethical Approval

This study was approved by the Mugla Sıtkı Kocman University Animal Experiments Local Ethics Committee (2014-075 Number Ethics Committee Decision). In addition, the authors declared that Research and Publication Ethical rules were followed.

Funding

This study was supported by *Aydın Adnan Menderes University as scientific research*, (Project Number: VTF15046).

Similarity Rate

We declare that the similarity rate of the article is 15% as stated in the report uploaded to the system.

Explanation

It was presented as a fully paper at the I. International Makuvet Applied Education Congress (2018). And it was summarized from the 1st author's doctoral thesis with the same name.

Author Contributions

Motivation / Concept: OB, AB

Design: OB, AİAÜ

Control/Supervision: OB, AİAÜ, AB

Data Collection and / or Processing: OB, AİAÜ, AB

Analysis and / or Interpretation: OB, AİAÜ, AB

Literature Review: OB, AİAÜ, AB

Writing the Article: OB, AİAÜ, AB

Critical Review: OB, AİAÜ, AB

References

- Ahmed IK, Cionni RJ, Kranemann C, Crandall AS, 2005: Optimal timing of capsular tension ring implantation: Miyake-Apple video analysis. *J Cataract Refract Surg*, 31, 1809-1813.
- Alagoz G, Yalcin A, Serin D, Sahap Kukner A, Elcioglu M, Celebi S, 2009: Fakodonezisli Katarakt Olgusunda İris Germe Kancaları ile Lensin Korneaya Asılması. *Duzce Uni Tip Fak Derg*, 11, 48-50.

- Balal S, Jbari AS, Nitiahpapand R, Cook E, Akhtar W, Din N, Sharma A, 2021: Management and outcomes of the small pupil in cataract surgery: iris hooks, plugin ring or phenylephrine? *Eye*, 35, 2714-2718.
- Bayraktar S, Altan T, Kucuksumer Y, Yilmaz OF, 2001: Capsular tension ring implantation after capsulorhexis in phacoemulsification of cataracts associated with pseudoexfoliation syndrome. Intraoperative complications and early postoperative findings. *J Cataract Refract Surg*, 27, 1620-1628.
- Chen TM, Lasarev MR, Eaton JS, 2023: Retrospective investigation of perioperative risk factors for immediate postoperative corneal erosions in dogs undergoing phacoemulsification. *Vet Ophthalmol*, 26, 191-204.
- Dowler KK, Middleton JR, Dufour S, Hood AM, Giuliano EA, 2021: Characterization of postoperative "fibrin web" formation after cataract surgery. *Vet Ophthalmol*, 24, 37-47.
- Dularent T, Steun L, Isard PF, 2023: Eye trauma from a cat scratch with retention of the claw in the anterior chamber in a dog. *Open Vet J*, 13, 388-393.
- Edelmann ML, Mohammed HO, Ledbetter EC, 2022: Retrospective evaluation of phacoemulsification and aspiration in 182 eyes: Visual outcomes and CDE-predictive value. *Vet Ophthalmol*, 25, 316-325.
- Jacob S, Agrawal A, Agrawal S, Patel N, Lal V, 2003: Efficacy of capsular tension ring for phacoemulsification in eyes with zonular dialysis. *J Cataract Refract Surg*, 29, 315-321.
- Johnstone N, Ward DA, 2005: The incidence of posterior capsule disruption during phacoemulsification and associated postoperative complication rates in dogs: 244 eyes (1995-2002). *Vet Ophthalmol*, 8, 47-50.
- Kershner RM, 2002: Management of the small pupil for clear corneal cataract surgery. *J Cataract Refract Surg*, 28, 1826-1831.
- Kugelberg M, Wejde G, Jayaram H, Zetterstrom C, 2006: Posterior capsule opacification after implantation of a hydrophilic or a hydrophobic acrylic intraocular lens: One-year follow-up. *J Cataract Refract Surg*, 32, 1627-1631.
- Ma X, Li Z, 2014: Capsular tension ring implantation after lens extraction for management of subluxated cataracts. *Int J Clin Exp Pathol*, 7, 3733-3738.
- Maggs DJ, Nasisse MP, Marrion RM, Priddy NH, Doham JR, 2010: Effects of intracameral administration of α -chymotrypsin on intracapsular lens extraction and postoperative outcome in clinically normal dogs. *Am J Vet Res*, 71, 1475-1483.
- Menapace R, Sacu S, Georgopoulos M, Findl O, Rainer G, Nishi O, 2008: Efficacy and safety of capsular bending ring implantation to prevent posterior capsule opacification: Three-year results of a randomized clinical trial. *J Cataract Refract Surg*, 34, 1318-1328.
- Nderitu P, Ursell P, 2019: Iris hooks versus a pupil expansion ring: Operating times, complications, and visual acuity outcomes in small pupil cases. *J Cataract Refract Surg*, 45, 167-173.
- Newbold GM, Kelch WJ, Chen T, Ward DA, Hendrix DV, 2015: Phacoemulsification outcomes in Boston terriers as compared to non-Boston terriers: a retrospective study (2002-2015). *Vet Ophthalmol*, 21, 353-361.
- Nishi O, Nishi K, Mano C, Ichihara M, Honda T, 1998: The inhibition of lens epithelial cell migration by a discontinuous capsular bend created by a band-shaped circular loop or a capsule-bending ring. *Ophthalmic Surg Lasers*, 29, 119-125.
- Praveen MR, Vasavada AR, Singh R, 2003: Phacoemulsification in subluxated cataract. *Indian J Ophthalmol*, 51, 147-154.
- Santosh HK, Ranganath L, Nagaraja BN, Satyanarayana ML, Narayanaswamy M, 2019: Studies on the influence of capsular tension ring (CTR) on intraocular lens (IOL) implantation following phacoemulsification in cataractous dogs. *J Entomol Zool Stud*, 7, 1071-1078.
- Saroğlu M, 2013: Kedi ve Kopek Goz Hastalıkları. 2nd ed., Nobel Tip Kitabevleri, Türkiye.
- Sigle KJ, Nasisse MP, 2006: Long-term complications after phacoemulsification for cataract removal in dogs: 172 cases (1995-2002). *J Am Vet Med Assoc*, 228, 74-79.
- Vasavada A, Singh R, 2000: Phacoemulsification in eyes with a small pupil. *J Cataract Refract Surg*, 26, 1210-1218.
- Wilkie DA, Hoy SS, Metzler AG, Colitz CMH, 2015: Safety study of capsular tension ring use in canine phacoemulsification and IOL implantation. *Vet Ophthalmol*, 18, 409-415.



Evaluation of Cases of Foreign Body Ingestion in the Gastrointestinal Tract of Cats: 12 Cases

Ali GULAYDIN^{1,a,*}, Mustafa Barış AKGUL^{1,b}

¹Siirt University, Faculty of Veterinary Medicine, Department of Surgery, Siirt, Türkiye.

^aORCID: 0000-0002-7200-1040;

^bORCID: 0000-0002-9365-9925;

Received: 15.04.2024

Accepted: 05.06.2024

How to cite this article: Gulaydin A, Akgul MB. (2024). Evaluation of Cases of Foreign Body Ingestion in the Gastrointestinal Tract of Cats: 12 Cases. Harran Üniversitesi Veteriner Fakültesi Dergisi, 13(1): 76-83. DOI:10.31196/huvfd.1468487.

***Correspondence:** Ali GULAYDIN

Siirt University, Faculty of Veterinary Medicine, Department of Surgery, Siirt, Türkiye.

e-mail: a.gulaydin@siirt.edu.tr

Available on-line at: <https://dergipark.org.tr/tr/pub/huvfd>

Abstract: In this study, the operative treatment results of foreign body ingestion cases in 12 cats brought to Surgery Clinic of Siirt University Animal Health Practice and Research Hospital with various complaints between 2020 and 2023 were evaluated. As a result of radiographic examination, foreign bodies were detected in the stomachs of 3 patients and in the intestines of 9 patients. In the pre-operative period, the blood parameters of the patients were evaluated and all patients were administered fluid therapy and antibacterial treatment for prophylaxis. The foreign body was removed from the relevant area operatively under general anesthesia. In the post operative period, all patients except 1 (case no: 4) included in the study were hospitalized, and appropriate diet and post-operative care were applied. As a result, 11 (91.66%) of the 12 patients who underwent surgery in the study were discharged between post-operative 11th and 21st days without any complications. In the study, it was concluded that operative treatment was necessary in cases of foreign body ingestion in cats and that post-operative care was of great importance in prognosis.

Keywords: Cat, Foreign body, Gastrointestinal system.

Kedilerde Sindirim Sistemi Kanalında Tespit Edilen Yabancı Cisim Olgularının Değerlendirilmesi: 12 Olgu

Özet: Bu çalışmada 2020-2023 yılları arasında Siirt Üniversitesi Hayvan Sağlığı Uygulama ve Araştırma Hastanesi Cerrahi Kliniği'ne çeşitli şikayetlerle getirilen 12 kedide yabancı cisim yutma olgusunun operatif sağaltım sonuçları değerlendirildi. Radyografik muayene sonucunda hastaların 3'ünde midede, 9'unda ise bağırsakta yabancı cisim tespit edildi. Pre-operatif dönemde hastaların kan parametreleri değerlendirilerek tüm hastalara sıvı tedavisi ve profilaksi amacıyla antibakteriyel tedavi uygulandı. Hastalar genel anesteziye alınarak yabancı cisim ilgili bölgeden operatif olarak uzaklaştırıldı. Post-operatif dönemde çalışmaya dahil edilen olguların 1'i hariç (olgu no:4) tüm hastalar hospitalize edilerek uygun diyet ve post-operatif bakım uygulandı. Sonuç olarak çalışmada operasyonu gerçekleştirilen 12 olgunun 11 (%91,66)'i komplikasyon yaşanmadan 11-21. günlerde taburcu edildi. Araştırmada kedilerde yabancı cisim yutma olgularında operatif sağaltımın gerekli olduğu ve post-operatif bakımın prognozda büyük önem taşıdığı kanısına varıldı.

Anahtar Kelimeler: Gastrointestinal sistem, Kedi, Yabancı cisim.

Introduction

The phenomenon of foreign body ingestion in pet animals is a quite common occurrence and ranks among the most common reasons for presentations to veterinary emergency clinics (Aronson et al., 2000; Hayes, 2009; Papazoglou et al., 2003; Prat et al., 2014). Especially, cats swallowing various objects while playing with toys can lead to serious health problems (Capak et al., 2001; Erol et al., 2019). The lesions observed in these cases vary depending on the physical characteristics of the ingested foreign bodies. Sharp objects can cause severe pathologies by penetrating any part of the gastrointestinal tract (esophagus, stomach, and intestinal wall). Large and non-penetrating foreign bodies can cause complete or partial obstructions in the gastrointestinal tract (stomach and intestines) (Erol et al., 2019). It has been reported that obstructions by foreign bodies generally disrupt blood flow in the intestinal segment, leading to edema and gangrene. Consequently, complications such as ileus and mucosal barrier disruption may occur (Ellison, 1993; Hayes, 2009). Additionally, foreign body obstructions can lead to dehydration, mental status changes, fluid, acid-base, and electrolyte imbalances, resulting in hypovolemia and toxemia in pet animals (Kan et al., 2022; Lopez et al., 2021; Maxwell et al., 2021).

Clinical signs observed in cases of foreign body ingestion in cats and dogs vary depending on the nature of the foreign body (sharp or non-sharp), the location, degree, and duration of the obstruction (Aronson et al., 2000; Hayes, 2009; Papazoglou et al., 2003). Generally, the most common clinical signs include vomiting, regurgitation, depression, anorexia or hypoxia, and weight loss (Aronson et al., 2000; Hobday et al., 2014; Kan et al., 2022; MacPhail, 2002). In the cases causing intestinal obstructions, signs of pain, anorexia, hypersalivation, melena, dehydration, abdominal distension upon palpation, and signs of pain are observed, while a dilated intestinal segment is prominent on radiographic examination (Erol et al., 2019; Tyrrell and Beck, 2006).

Various treatment options are available to remove foreign bodies from the gastrointestinal system. It is emphasized that the nature of the foreign bodies, the status of obstruction, or the risk of perforation should be considered in determining the veterinarian's treatment method (Pratt et al., 2014). Inducing vomiting in the patient (Prat et al., 2014), endoscopy (Bebchuk, 2002; McCarthy, 2005; Tams, 2003), fluoroscopy (Moore, 2001), and surgical intervention are evaluated as treatment options (Binvel et al., 2018; Deroy et al., 2015). Especially, when planning endoscopic retrieval, it is reported that the possibility of failure and the high risk of intestinal perforation should be account (Binvel et al., 2018).

This study evaluated the effectiveness and outcomes of surgical interventions applied to cats with various foreign bodies detected in the gastrointestinal system based on clinical and radiographic examinations conducted at the Surgery Clinic of Siirt University Animal Health Application and Research Hospital between 2020 and 2023.

Materials and Methods

Animal Material: Twelve cats of various breeds, ages, and genders presented with complaints of anorexia, vomiting, and abdominal pain at the Surgery Department of Siirt University Animal Health Application and Research Hospital between 2020 and 2023, and diagnosed with foreign bodies in the gastrointestinal tract based on clinical and radiographic examinations, were included in this study.

Ethical Approval: This study is not subject to HADYEK approval as it falls under the scope of "clinical applications for diagnosis and treatment" according to Article 8, Clause 1 of the Regulation on the Principles and Procedures of Animal Experiments published in the official gazette on February 15, 2014.

Diagnosis: Anamnesis information obtained from the owners was initially evaluated in the cases. In addition to routine clinical examination, diagnosis was confirmed using direct, indirect radiography and ultrasonography. Abdominal radiographs (FDR Smart X, Fujifilm, Japonya) in LL (latero-lateral) and VD (ventro-dorsal) positions were obtained for all patients. The appearance, localization, opacity, and presence of foreign bodies in the stomach and small intestine were evaluated. Accordingly, the localization of radiopaque foreign bodies was determined. Patients suspected of having non-contrast foreign bodies were administered iohexsol (Omnipaque 300 mg/100 mL, Opakim Tıbbi Ürünler Sanayi ve Ticaret A.Ş., İstanbul, Türkiye) orally and partial or complete obstruction was determined by indirect radiography. Cases of intussusception were identified through abdominal ultrasonography (Mindray Vetus 8, Shenzhen Mindray Animal Technology Co. Ltd, Shenzhen, China) examination.

Pre-operative Care: Various blood parameters (Mindray BC-60R Vet, Shenzhen Mindray Animal Technology Co. Ltd, Shenzhen, China) were evaluated, and all cases received fluid therapy before the operation. As prophylaxis during the pre-operative period, ceftriaxone (Unacefin® 0.5 g, Yavuz İlaç, İstanbul, Türkiye) was administered at a dose of 20 mg/kg. Additionally, as indicated in similar studies (Hayes, 2009), to reduce the risk of post-operative infection, especially in patients undergoing enterotomy or enterectomy, 10 mg/kg of intravenous metronidazole (Flagyl, Aventis, France) was administered intraoperatively.

Operation: After completing the routine pre-operative preparations, anesthesia induction was achieved by intravenous injection of propofol at a dose of 4 mg/kg. Maintenance of anesthesia was performed using a closed-circuit anesthesia machine (SMS 2000 Classic Vent-V, SMS Medical Devices, Elek. Elekt. İnş. Teks. Turz. Oto San. ve Tic. Ltd. Şti. Ankara, Türkiye) with 2% sevoflurane (Sevorane®, Abbott, Italy). All patients were placed in a supine position on the operating table. A ventral midline incision was performed to reach the abdominal cavity using ventral midline incision was performed to reach the abdominal

cavity using a routine approach. The location of the foreign body was determined by palpation with the aid of radiographic images. An examination of the entire gastrointestinal system was performed. Gastrotomy was performed in 3 cases (case no: 1, 6, 12). In seven cases (case no: 2, 3, 4, 7, 8, 9, and 11) without evidence of inflammation and necrosis in the relevant segment, enterotomy was

performed, while in two cases with evidence of inflammation and necrosis, enterectomy and anastomosis were performed to remove foreign bodies (Table 1). Incision lines were closed with simple sutures using 2/0 polydioxanone (PDS II, Ethicon, USA). Muscles and skin were closed according to surgical principles, and the operation was concluded (Figure 1, 2).

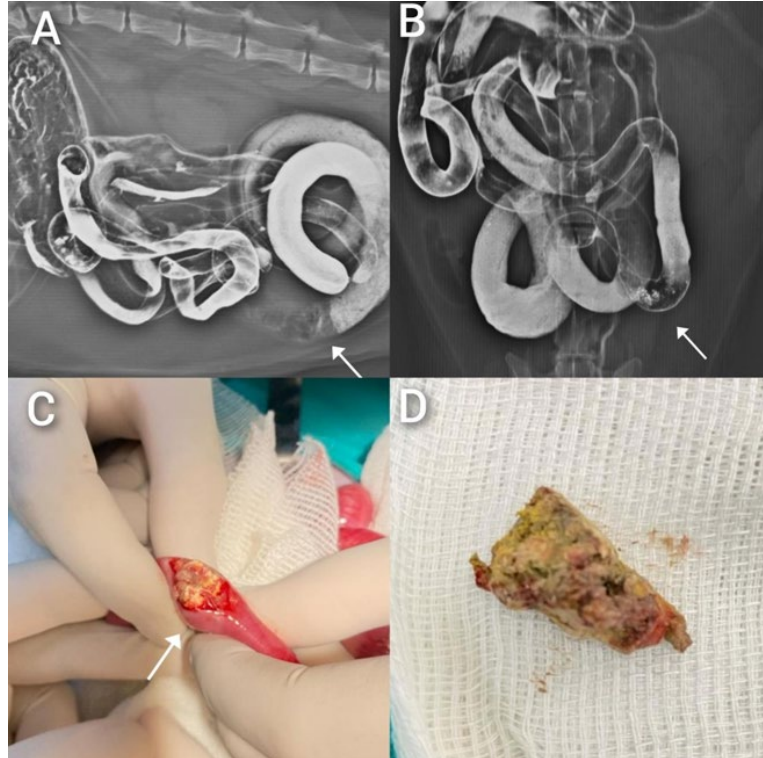


Figure 1. Case no: 4. A: Pre-operative indirect radiography L/L, B: Pre-operative indirect radiography V/D, C: Removal of foreign body, D: Foreign body (slipper piece).

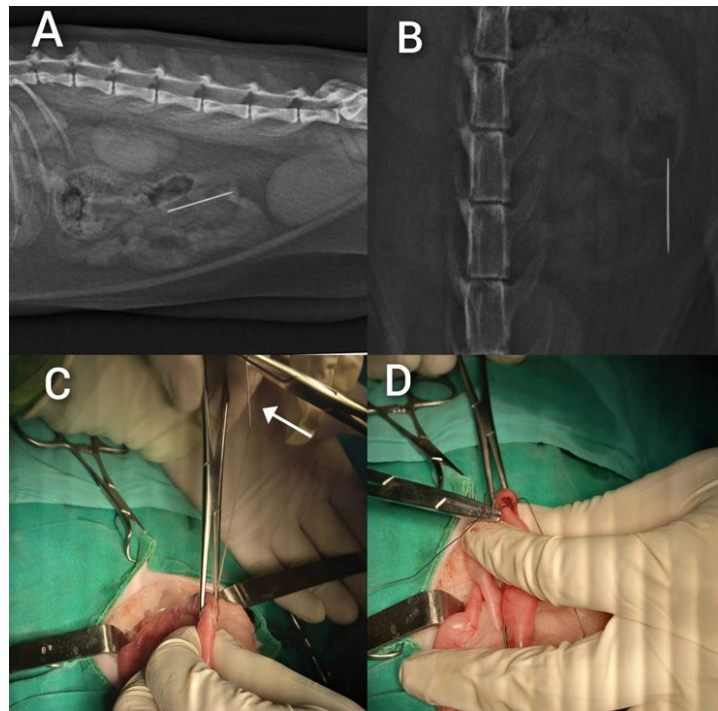


Figure 2. Case no: 3. A: Pre-operative Radiography L/L, B: Pre-operative Radiography V/D, C: Removal of Foreign Body (Sewing Needle), D: Sewing Line.

Table 1. Information about the cases included in the study.

No	Breed	Age	Sex	Kg	Localization	Operation	Foreign Body	A.T.H (day)	H.S (day)	Symptoms	Diagnosis
1	M	1 month	Male	1	Stomach	Gastrotomy	Plastic Ear Plugs	1	15	Anorexia, Vomiting	Direct Radiography (Radiopaque)
2	M	1 year	Male	3	Jejunum-Colon	Enterotomy	Sewing Thread	1	15	Anorexia, Vomiting	İnspection
3	M	1.5 years	Female	3.7	Jejunum	Enterotomy	Sewing Needle	1	11	Abdominal pain, Vomiting	Direct Radiography (Radiopaque)
4	M	3 years	Male	3.4	Jejunum	Enterotomy	Part of Slipper	3	0	Anorexia, Vomiting, Abdominal pain	Indirect Radiography (Complete obstruction)
5	M	2 years	Male	3.2	Jejunum-Colon	Anastomosis	Sewing Thread	8	21	Anorexia, Vomiting, Abdominal pain	Ultrasonography
6	S	2 years	Female	2.7	Stomach	Gastrotomy	Plastic Hair Clips	1	14	Anorexia, Vomiting	Direct Radiography (Radiopaque)
7	M	11 months	Male	2.6	Ileum	Enterotomy	Ball of String	1	16	Anorexia, Vomiting	Indirect Radiography (Partial obstruction)
8	S	2 months	Male	1.4	Ileum	Enterotomy	Ball of String	0	18	Anorexia, Vomiting	Indirect Radiography (Partial obstruction)
9	S	5 years	Male	4.7	Jejunum	Enterotomy	Slipper Sponge	2	16	Abdominal bloating, pain,	Indirect Radiography (Complete obstruction)
10	M	7 months	Male	1.7	Ileum	Anastomosis	Bone Fragment	5	21	Anorexia, Abdominal bloating, pain	Direct Radiography (Radiopaque)
11	S	3 years	Female	4.2	Jejunum-Colon	Enterotomy	Sewing Thread	2	14	Anorexia, vomiting, Abdominal bloating, pain	İnspection
12	M	4 years	Male	4.5	Stomach	Gastrotomy	Plastic Buckle	1	15	Anorexia, Vomiting	Direct Radiography (Radiopaque)

Post-operative Care: In patients undergoing gastrotomy or enterotomy, water was provided 12 hours after the operation (unless vomiting occurred), and a small amount of wet food was given 24 hours later. Patients were advised to return to their everyday regular feeding routines 36 hours after the operation. For patients who underwent anastomosis, water was provided 24 hours after the procedure, followed by a small amount of wet food after 36 hours, and a normal amount of wet food after 48 hours. Intravenous fluid therapy %0.9 NaCl solution (Pifarma, Söğütözü, Ankara, Türkiye), at a dose of 25 ml/kg, and %5 dextrose (Pifarma, Söğütözü, Ankara, Türkiye) was continued until adequate food intake was achieved for all patients. The duration of antibiotic (ceftriaxone at a dose of 20 mg/kg) and analgesic (meloxicam at a dose of 0.2 mg/kg) usage was determined considering the type of operation (whether an anastomosis was performed) and examination of the incision line (presence of infection). Thus, the use of meloxicam at a dose of 0.2 mg/kg (Meloxicam, Bavet, İstanbul, Türkiye) was continued for up to 3 days at most, while the use of ceftriaxone at a dose of 20 mg/kg (Unacefin® 0.5 g, Yavuz İlaç, İstanbul, Türkiye) was continued for up to 7 days.

Results

The study included 8 (66.66%) mixed-breed cats and 4 (33.33%) Scottish-breed cats. It was determined that the ages of the patients ranged from 1 month to 5 years, and their body weights varied between 1 and 4.7 kg.

According to the medical history, it was found that the cases were brought to the hospital approximately 1-8 days after the onset of symptoms. In 6 cases (case no: 1, 6, 7, 8, 9, 12), owners witnessed the ingestion of foreign bodies by their pets. In two cases (case no: 2, 11), a string protruding from the anus was observed upon inspection. In the other 4 cases, sufficient medical history could not be obtained.

During clinical examination, anorexia, intermittent vomiting, abdominal distension, and a hunched posture were observed in the patients. Direct radiographic examination revealed radiopaque foreign bodies in 5 cases (case no: 1, 3, 6, 10, 12). Indirect radiographic examination showed complete or partial obstruction in 4 cases (case no: 4, 7, 8, 9). Ultrasonographic examination detected jejunal invagination in 1 case (case no: 5). In 2 cases (case no: 2, 11), a string protruding from the anus was observed. The segments where foreign bodies were detected in the gastrointestinal tract are indicated in Table 1. Analysis of all cases revealed that routine blood parameters were within normal limits. Intraoperatively, invagination was detected in 1 case (case no: 5), and gangrene was observed in the intestinal segment of another case.

In post-operative period a specific dietary program was recommended for each patient following the surgical procedure. Forty-eight hours after surgery, it was observed that all patients, except one (case no: 4), showed increased appetite and normal defecation. In one patient (case no: 4), whose hospitalization was not accepted by the owner, it was found that the recommended dietary program was not followed, and due to the owner's uncontrolled behavior, a

large amount of wet food was fed to the patient approximately 6 hours after the surgery. On the third post-operative day, the patient was brought back with complaints of an open wound and foul odor at the incision site. Upon clinical, laboratory, and radiographic examinations, the patient was taken back to surgery due to suspected leakage at the enterotomy site. Infection, rupture, and abdominal contents were detected in the relevant intestinal segment. The abdominal cavity was lavaged with warm isotonic and antibiotic solutions, followed by anastomosis of the intestinal segment. The patient expired on the third post-operative day. Except for one patient (case no: 4) who could not be hospitalized, all other patients in the study fully recovered without complications and were discharged between days 11-21.

Discussion and Conclusion

It is emphasized that as the duration of clinical symptoms of intestinal obstruction in cats and dogs increases, the success rate of treatment decreases (Hayes, 2009). In this context, witnessing the ingestion of foreign bodies leads to patients being taken to the veterinarian more quickly, but also helps determine the duration of the foreign body in the digestive tract (Crino et al., 2023; Hayes, 2009). In this study, while pet owners reported foreign body ingestion in 6 cases (cases no: 1, 6, 7, 8, 9, 12), in 2 cases (case no: 2, 11), a string protruding from the anus was observed. It was determined that the arrival times of these cases to the hospital were shorter compared to those with uncertain medical histories. It was concluded that this situation allows for early intervention, reduces the risk of complications, and accelerates the recovery process. From this perspective, thought to be important in the treatment process, in line with the literature.

Although there was no clear correlation between foreign bodies and breeds, Hayes (2009) reported a higher incidence of foreign bodies in mixed-breed cats. Similarly, Demirel (2021) reported a higher incidence of foreign body ingestion cases in mixed-breed cats. In our study, 8 out of 12 cases (66.66%) were mixed-breed cats. However, we believe that factors such as the higher prevalence of foreign body ingestion cases among mixed-breed animals due to their outdoor living habits rather than their breed-specific characteristics contribute more to this situation.

Various studies have indicated that the average age of cats presenting with foreign body ingestion cases is less than 2 years old (Crino et al., 2023; Demirel, 2021; Hayes, 2009; Pratt et al., 2014). Consistent with previous reports, the average age of the cats in this study was less than 2 years old. We believe that the reason for this situation stems from factors such as the feeding habits of young cats, their desire to play, and their lack of experience.

Caixeta et al. (2018) reported that 62% of the dogs identified with foreign body ingestion were male, while 38% were female. Hobday et al. (2014) reported that 67% of the cases with foreign bodies were male dogs, and 33% were female. Demirel (2021) stated that 48.1% of the cats with

foreign bodies were female, while 51.9% were male, and for dogs, 39.9% were female, and 60% were male. Although our study had a limited number of cases, the higher proportion of male cats is consistent with the literature. This situation suggests that male animals are more interested in foreign objects than females.

In most cases of cats and dogs, foreign bodies are found in the small intestines (Hayes, 2009; Power and Diamond, 2021), while some researchers have reported that foreign bodies are most commonly found in the stomach in the gastrointestinal tract (Caixeta et al., 2018; Demirel, 2021; Hobday et al., 2014). Although we encountered more foreign bodies in the small intestine in our study, it was concluded that the localization might vary, and it was not possible to make a general statement about this.

It has been noted that cats have a greater interest in linear foreign bodies compared to other objects. Studies have generally observed that foreign bodies identified in cats are strings or yarns (Fossum, 2014; Hayes, 2009). Based on their findings, Demirel (2021) suggested that cats may involuntarily or voluntarily swallow string-like objects while playing with them due to the anatomical structure of their tongues. The detection of linear foreign bodies in 50% of our cases is consistent with literature findings. Taking into account the anamnesis information, we believe it is possible to infer that cats have a greater fondness for playing with these objects and that they may accidentally ingest them while playing.

Clinical signs resulting from the presence of foreign bodies in the digestive tract vary depending on the degree of obstruction, localization, and lesions that may occur in the intestines. In this regard, it was emphasized that an increase in the degree of obstruction, as well as proximal obstructions, would lead to more acute and severe clinical signs. Generally, clinical signs included vomiting, anorexia, dehydration, depression, weight loss, and abdominal pain (Erol et al., 2019; Pennick, 2002; Tyrrell, 2006). Crino et al. (2023) reported in their study that clinical signs were not observed in most cases identified with foreign body ingestion. In contrast, Pratt et al. (2014) stated in their study that severe clinical symptoms were observed. In this study, anorexia and intermittent vomiting were generally detected in clinical examinations of patients. Abdominal distension, pain, and a hunched posture were observed in patients with intestinal obstruction and penetrating foreign bodies. The mild clinical signs observed in this study were similar to those reported by Crino et al. (2023). It was presumed that this might be due to early presentation of patients to the hospital resulting in rapid diagnosis and treatment.

It was stated that the most commonly used diagnostic method for identifying foreign bodies in the gastrointestinal system is radiographic imaging (Armbrust, 2003; Erol et al., 2019; Koenhems, 2011; Tyrrell, 2006). It was noted that radiographic examination could identify radiopaque foreign bodies, the location of the obstruction, and the presence of gas and fluid accumulation, indicating a mechanical ileus condition (Arıcan, 2011; Finck et al., 2014; Thrall, 2013). In the study, the location of contrast-enhanced foreign bodies was determined by direct radiography in 5 cases, the site and

degree of obstruction were determined by indirect radiography in 4 cases, and diagnosis was confirmed by detecting invagination via ultrasonographic examination in 1 case. As noted in other studies, radiographic examination is considered sufficient for diagnosing foreign bodies.

It was mentioned that in the gastrointestinal system, especially in cases of partial obstruction, a foreign body might progress spontaneously through peristaltic movements and was expelled from the body with appropriate diet, thus obviating the need for operative intervention (Erol et al., 2019; Zatloukal et al., 2004). In human medicine, it was often stated that radiographic monitoring should be performed, and the duration required for monitoring the foreign body was reported to be 72 hours. During this period, if there was an increase in the severity of clinical signs or if the foreign body was not expelled through normal routes, operative treatment was recommended (Becq et al., 2021). Crino et al., (2023) suggested that the same procedure could be applied in veterinary medicine, but they emphasized that they did not specifically evaluate items such as threads attached to needles in their studies, and different recommendations might be applicable in such cases. Kan et al., (2022). They highlighted that the success rate of surgical intervention after foreign body obstruction decreased as the duration of obstruction symptoms prolonged, emphasizing the necessity of rapid stabilization and surgical intervention. In accordance with literature findings, due to concerns about various complications (pressure necrosis, intestinal perforation, invagination) in 12 patients in the study, operative treatment was performed within 24 hours for cases 3, 4, 5, and 10, and within 48 hours for cases 1, 2, 6, 7, 8, 9, 11, and 12, taking into account the time of arrival to the hospital and the type of foreign body without waiting for a 72-hour period. Except one patient who did not receive appropriate post-operative care from the owner, all other patients recovered without complications. This suggests the necessity of operative intervention without waiting for a waiting period in similar cases of foreign body incidents in our patients.

In various studies, the most essential critical complications of gastrointestinal surgery were emphasized as loss of suture line integrity and leakage of contents into the abdominal cavity (Allen et al., 1992; Evans et al., 1994; Hayes, 2009; Shales et al., 2005). In this study, leakage was complications at the enterotomy site was encountered in only one case. It was determined that this situation occurred due to inappropriate post-operative care. When other cases were evaluated, it was concluded that appropriate post-operative care positive contribution significantly to achieving favorable outcomes.

Considering the potential complications after gastrointestinal surgery, the post-operative diet program was supposed to be crucial (Durmuş et al., 2004; Erol et al., 2019). In our cases, a careful approach was taken during the post-operative period with 12-24 hours of water and 36-48 hours of food restriction. The results showed the importance of implementing these restrictions, as emphasized in the literature.

This study suggests that cats are prone to swallowing foreign objects, knowingly or unknowingly, due to their natural playful and active behavior, often resulting in jejunal obstruction. It emphasizes the significant impact of the time of presentation to the hospital on the diagnosis and treatment timelines, highlighting the crucial importance of clear anamnesis information. While the radiographic examination is generally sufficient, especially in the presence of radiopaque objects, it indicates the necessity of resorting to other imaging modalities to determine the details of complications. Of literature findings and study data underscores the importance of timely operative removal, particularly for foreign bodies that cause complete obstruction and exhibit penetrating properties. Furthermore, it identifies the lack of careful postoperative care as the sole complication encountered in the study, emphasizing the importance of adhering to standard care practices. These findings underscore the necessity of a cautious approach in managing cases of foreign body ingestion in veterinary practice.

Ethical Approval

This study is not subject to HADYEK permission in accordance with Article 8 (k) of the "Regulation on Working Procedures and Principles of Animal Experiments Ethics Committees".

Funding

This study was not supported by the institution or organization.

Similarity Rate

We declare that the similarity rate of the article is 11% as stated in the report uploaded to the system.

Author Contributions

Motivation / Concept: AG, MBA
 Design: AG, MBA
 Control/Supervision: MBA
 Data Collection and / or Processing: AG, MBA
 Analysis and / or Interpretation: AG
 Literature Review: AG
 Writing the Article: AG
 Critical Review: MBA

References

Allen D, Smeak D, Schertel E, 1992: Prevalence of small intestinal dehiscence and associated clinical factors: a retrospective study of 121 dogs. *J Am Anim Hosp Assoc*, 28 (1), 70-76.
 Arıcan M, 2011: Veteriner Genel Radyoloji ve Kedi, Köpek için Tanısal Radyografi Atlası. Bahçivanlar Basım San A.Ş., Konya, Türkiye.
 Armbrust LJ, Biler DS, Radlinsky MG, Hoskinson JJ, 2003: Ultrasonographic diagnosis of foreign bodeis associated with

chornic draining tracts and abscesses in dogs. *Vet Radiol Ultrasound*, 44 (1), 66-70.
 Aronson LR, Brockman DJ, Brown DC, 2000: Gastrointestinal emergencies. *Vet Clin North Am Small Anim Pract*, 30, 555-579.
 Bebcuk TN, 2002: Feline gastrointestinal foreign bodies. *Vet Clin North Am Small Anim Pract*, 32 (4), 861-880.
 Becq A, Camus M, Dray X, 2021: Foreign body ingestion: dos and don'ts. *Frontline Gastroenterol*, 12 (7), 664-670
 Binvel M, Poujol L, Peyron C, Dunie-Merigot A, Bernardin F, 2018: Endoscopic and surgical removal of oesophageal and gastric fishhook foreign bodies in 33 animals. *J Small Anim Pract*, 59 (1), 45-49.
 Caixeta ACF, Alves EGL, Coelho NGD, Souza ACF, Torres RCS, Nepomuceno AC, 2018: Foreign body in the gastrointestinal tract of dogs: a retrospective study. *Ars Veterinaria*, 34 (1), 20-24.
 Capak D, Simpraga M, Maticic D, Balli R, Janoska B, 2001: Incidence of foreign body induced ileus in dogs. *Berl Munch Tierarztl Wochenschr*, 114 (7-8), 290-296.
 Crinò C, Humm K, Cortellini S, 2023: Conservative management of metallic sharp-pointed straight gastric and intestinal foreign bodies in dogs and cats: 17 cases (2003-2021). *J Small Anim Pract*, 64 (8), 522-526.
 Demirel A, 2021: Kedi ve köpeklerde mide ve barsak yabancı cisim prevalansı. Yüksek Lisans tezi, Afyon Kocatepe Üniversitesi Sağlık Bilimleri Enstitüsü, Afyon.
 Deroy C, Corcuff JB, Billen F, Hamaide A, 2015: Removal of oesophageal foreign bodies: comparison between oesophagoscopy and oesophagotomy in 39 dogs. *J Small Anim Pract*, 56 (10), 613-617.
 Durmuş AS, Dabak M, Kızıl Ö, 2004: Bir alman çoban köpeğinde bağırsak obstrüksiyonu ve operatif sağaltımı. *Fırat Üniversitesi Doğu Araştırmaları Dergisi*, 3 (1), 65-69.
 Ellison GW 1993: Intestinal Obstruction. In: Disease Mechanisms in Small Animal Surgery, Bojrab MJ (Ed), 252-257, Lea & Febiger, Philadelphia, USA.
 Erol H, Atalan G, Alpman U, Yönez MK, Onmaz AC, 2019: Köpeklerde yabancı cisme (kulak küpesi) bağlı şekillenen mekanik ileus'un operatif sağaltım ve sonuçlarının değerlendirilmesi: 6 Olgu. *Erciyes Üniv Vet Fak Derg*, 16 (2), 92-97.
 Evans KL, Smeak DD, Biller DS, 1994: Gastrointestinal linear foreign bodies in 32 dogs: a retrospective evaluation and feline comparison. *J Am Anim Hosp Assoc*, 30 (5), 445-450.
 Finck C, D'anjou MA, Alexander K, Specchi S, Beauchamp G, 2014: Radiographic diagnosis of mechanical obstruction in dogs based on relative small intestinal external diameters. *Vet Radiol Ultrasound*, 55 (5), 472-479.
 Hayes G, 2009: Gastrointestinal foreign bodies in dogs and cats: A retrospective study of 208 cases. *J Small Anim Pract*, 50 (11), 576-583.
 Hobday MM, Pachtiger GE, Drobatz KJ, Syring RS, 2014: Linear versus non-linear gastrointestinal foreign bodies in 499 dogs: Clinical presentation, management and short-term outcome. *J Small Anim Pract*, 55 (11), 560-565.
 Kan T, Hess RS, Clarke DL, 2022: Clinical findings and patient outcomes following surgical treatment of chronic gastrointestinal foreign body obstructions in dogs and cats: 72 cases (2010-2020). *Can J Vet Res*, 86 (4), 311-315.
 Koenhemi L, İskefli O, Dokuzeylül B, Gönül R, Or E, Uysal A, 2011: Bir köpekte yabancı cisme bağlı akut mide dilatasyonu teşhisinde radyolojik ve ultraonografik inceleme. *Yüzüncü Yıl Üniversitesi Vet Fak Derg*, 22 (3), 185-187.
 Lopez DJ, Holm SA, Kortzen B, Baum JJ, Flanders JA, Sumner JP, 2021: Comparison of patient outcomes following enterotomy versus intestinal resection and anastomosis for treatment of

- intestinal foreign bodies in dogs. *J Am Vet Med Assoc*, 258 (12), 1378-1385.
- MacPhail C, 2022: Gastrointestinal obstruction. *Clin Tech Small Anim Pract*, 17 (4), 178-183.
- Maxwell EA, Dugat DR, Waltenburg M, Upchurch D, Soto-Elias P, Duffy DJ, Spector D, Petrovsky B, Payton M, 2021: Outcomes of dogs undergoing immediate or delayed surgical treatment for gastrointestinal foreign body obstruction: A retrospective study by the Society of Veterinary Soft Tissue Surgery. *Vet Surg*, 50 (1), 177-185.
- Mccarthy T, 2005: *Veterinary Endoscopy for the Small Animal Practitioner*. Saunders, St Louis, MO, USA.
- Moore AH, 2001: Removal of oesophageal foreign bodies in dogs: fluoroscopic method and outcome. *J Small Anim Pract*, 42 (5), 227-230.
- Papazoglou L, Rallis T, 2003: Intestinal foreign bodies in dogs and cats. *Compend Contin Educ Vet*, 25 (11), 830-843.
- Pennick DG, 2002: Gastrointestinal Tract. In: *Small Animal Diagnostic Ultrasound*, Nyland TG, Mattoon JS (Eds), 207-230, WB Saunders, Philadelphia.
- Power AM, Diamond DW, Puetthoff C, 2021: Laparotomy-Assisted transoral foreign body retrieval in small animals: 10 Cases (2018-2020). *Top Companion Anim Med*, 42, 100504.
- Pratt CL, Reineke EL, Drobatz KJ, 2014: Sewing needle foreign body ingestion in dogs and cats: 65 cases (2000-2012). *J Am Vet Med Assoc*, 245 (3), 302-308.
- Shales CJ, Warren J, Anderson DM, Baines SJ, White RAS, 2005: Complications following full-thickness small intestinal biopsy in 66 dogs: a retrospective study. *J Small Anim Pract*, 46 (7), 317-321
- Tams TR, 2003: *Handbook of Small Animal Gastroenterology*. 2nd ed., Saunders, St Louis, MO, USA.
- Thrall D, 2013: *Textbook of Veterinary Diagnostic Radiology*. 2nd ed., Saunders, St. Louis Missouri, USA.
- Tyrrell D, Beck C, 2006: Survey of the use of ultrasonography in investigating gastrointestinal foreign bodies in small animals. *Vet Radiol Ultrasound*, 47 (4), 404-408.
- Zatloukal J, Crha M, Lorenzova J, Husnik R, Kohout P, Necas A, 2004: The comparative advance of plain radiography in diagnosis of obstruction of the small intestine in dogs. *Acta Vet Brno*, 73 (1), 365-374.

HARRAN ÜNİVERSİTESİ VETERİNER FAKÜLTESİ DERGİSİ YAYIN KURALLARI *

1- Harran Üniversitesi Veteriner Fakültesi Dergisi (Harran Üniv Vet Fak Derg), özellikle Veteriner Hekimliği bilim alanı ile ilgili olmak üzere insan ve hayvan sağlığını kapsayan Türkçe ve İngilizce olarak hazırlanmış orijinal klinik ve deneysel araştırmalar, olgu sunumları, derlemeler (çağrılı veya sorumlu yazara ait derleme konusu ile ilgili en az 3 araştırma makalesinin referans listesinde olması gereklidir), kısa bilimsel makale ve editöre mektuplar yayınlayan hakemli bir dergidir. Dergide İngilizce hazırlanmış makalelerin yayımlanmasına öncelik verilir. Dergi 6 ayda bir, yılda 2 sayı olarak yayınlanır. Yayınlanan makalelerden ücret alınmamaktadır.

2- Dergiye kabul edilen yayınlar başka bir yerde yayınlanmamış olmalıdır. Eş zamanlı olarak incelenmek üzere başka dergilere gönderilmiş olmamalıdır. Yayınlanan makalelerden doğacak her türlü hukuki ve cezai sorumluluk yazarlara aittir. Yazarlara yayın hakkı bedeli ödenmez. Gönderilen makaleler ve ekleri makale yayınlansın veya yayınlanmasın geri iade edilmez.

3- Daha önce kongrelerde tebliğ edilmiş ve özeti yayımlanmış çalışmalar, bu durum kapak sayfasında belirtilmek üzere kabul edilir. Bununla birlikte yayın, tezden üretilmiş ise ve destekleyen kuruluş var ise yayında belirtilmelidir.

4- Dergi Editörlüğüne ulaşan makale, dergi editörlüğüne ön değerlendirmeye tabi tutulur. Editörlük, ön değerlendirme sonucuna göre makaleyi reddetme veya hakem değerlendirmesine tabi tutmadan önce düzeltme isteme hakkına sahiptir.

5- Makaleler değerlendirme için en az iki hakeme gönderilir. Makale kabul sürecinde, iki hakemin görüşlerinin farklı olması durumunda editör, üçüncü bir hakemin veya danışma kurulunun görüşünü alarak karar verir.

6- Harran Üniversitesi Veteriner Fakültesi Dergisi, etik ilkelere saygı çerçevesinde, TÜBİTAK ULAKBİM tarafından Türkiye'de tüm üniversitelerin kullanımına açmış olduğu "ithenticate" intihal tespit programı aracılığıyla gönderilen tüm makale, olgu sunumu ve derlemelerin ön değerlendirmesinin yapılması ve sonuçların gönderilmesi gerekmektedir. Bu ön değerlendirme sonuçlarına göre, makale, olgu sunumu veya derlemelerin başka kaynaklarla benzerlik oranının %15'i (özet, abstract ve kaynaklar hariç) aşmaması gerekmektedir. "ithenticate" programı aracılığı ile yapılacak öndeğerlendirmede benzerlik oranının %15 değerini aşması durumunda yayımlanmak üzere dergimize gönderilen makale, olgu sunumu veya derlemeler değerlendirilmeye alınmayacaktır.

7- Gönderilen herhangi bir makalenin (tüm makale kategorileri için) referanslarının en az % 20'sinin son beş yılda yayınlanan referansları içermesi gerekir. Anonim kaynaklar asgari düzeyde tutulmalıdır.

8- Makale yayına kabul edildiği takdirde her türlü yayın hakkının devredildiğine dair beyanları kapsayan Telif Hakkı Devir Sözleşmesinin tüm yazarlar tarafından imzalanarak basımdan önce elektronik olarak dergi editörlüğüne gönderilmesi gerekmektedir. Telif Hakkı Devir Sözleşmesi gönderilmeyen makaleler yayımlamaya kabul edilmiş olsalar bile basılmazlar.

9- Harran Üniversitesi Veteriner Fakültesi Dergisi'ne gönderilecek makale, olgu sunumu, derleme vb. çalışmalar, <https://dergipark.org.tr/tr/pub/huvfd> adresinden gönderildiğinde değerlendirme sürecine alınmaktadır.

10- Harran Üniversitesi Veteriner Fakültesi Dergisi'ne gönderilecek makale, olgu sunumu, derleme vb. çalışmalar MS Word formatında, tüm fotoğraflar (resimler) en az 300 dpi çözünürlükte, TIFF veya JPEG formatında kaydedilmiş olmalıdır.

YAZIM KURALLARI

Yazılar, MS Word formatında, Times New Roman yazı tipinde, 12 punto, çift satır aralıklı ve her kenardan 2.5 cm boşluk bırakılarak hazırlanmalıdır. Makaleye satır numaraları (makalenin 2. sayfasından başlamak üzere sürekli olacak şekilde) eklenmelidir. Bu şekildeki yazılar, şekil ve tablolar dâhil olmak üzere orijinal bilimsel araştırmalar ve derlemelerde 15, kısa bilimsel makale ve olgu sunumlarında 5 sayfayı geçmemelidir.

Birimler ve ölçüler için Uluslararası Standart birimleri (SI-sistem) kullanılmalıdır.

Araştırma Makaleleri: Orijinal araştırma makaleleri aşağıdaki ana konu sıralamasına göre dizilmelidir: Başlık, Yazar adları (Sorumlu yazar (*) ile işaretlenmeli), Yazar adresleri, Yazar ORCID numaraları, Özet ve Anahtar kelimeler (3 - 6 kelime), İngilizce başlık, Abstract ve Keywords ile Giriş, Materyal ve Metot, Bulgular, Tartışma ve Sonuç, Teşekkür veya Bilgilendirme ile Kaynaklar. Her bir Tablo ve Şekil ayrı sayfalarda yer almalıdır.

YAZIM DÜZENİ

Özet: Orijinal araştırma makalelerinde 250, diğer makale türlerinde 200 kelimeyi geçmeyecek şekilde hazırlanmalıdır.

Anahtar Kelimeler: En fazla 6 tane olmak üzere her iki dildeki özeti altında alfabetik sırayla verilmelidir. Anahtar kelimeler, Türkiye Bilim Terimleri arasından seçilmelidir. Anahtar kelimelerin seçiminde Türkiye Bilim Terimleri internet adresinden (<http://www.bilimterimleri.com>) yararlanılmalıdır.

Giriş: Sonuçların anlaşılabilirliği ve yorumlanabilirliği için o konu ile ilgili yapılmış olan çalışmalar hakkında bilgilere yer verilmelidir. Giriş'te çalışmanın hipotezi belirtilmelidir. Çalışmanın amacı bu bölümün en sonunda açık olarak yazılmalıdır.

Materyal ve Metot: Bu bölümde deneysel çalışmalar diğer araştırmacılar tarafından tekrarlanabilecek yeterlilikteki detayı ile verilmelidir. Uluslararası indeksli dergilerde yayınlanmış bir makalede açıklanan bir teknik kullanıldığında, metodun çok kısa açıklanması ve ilgili orijinal makaleye atıf yapılması gereklidir. Makalede etik kurul izni ve/veya yasal/özel izin alınmasının gerekip gerekmediği bu bölümde belirtilmelidir. Materyal olarak hayvan kullanılan orijinal araştırma makalelerinde (klinik, deneysel, saha çalışmaları vb.); etik kurul onayı alınmış olmalıdır. Etik kurul onay/izin belgesinin "alındığı etik kurulun ismini, sayısını ve tarihini" içeren açıklayıcı bilgiler materyal ve metot bölümüne yazılmalıdır. Yayın kurulu etik kurul onay belgesini isteme hakkına sahiptir.

Bulgular: Araştırma bulguları açık ve anlaşılabilir şekilde verilmelidir. Bulgular, gerektiğinde tablo ve şekillerle desteklenmeli ve kısa olarak sunulmalıdır.

Tartışma ve Sonuç: Bulgular gereksiz ayrıntıya girmeden literatürler ışığında tartışılmalı ve bulguların önemi vurgulanmalıdır. Sonuç ya da öneri cümlesi ile bitirilmelidir.

Teşekkür: Çalışma veya makaleye kişisel katkı ve parasal destek burada belirtilmelidir.

Derleme: Derginin yayın alanlarındaki konularda yenilikleri içeren, güncel kaynaklardan yararlanılarak hazırlanmış makaleler olup, yazarların konu ile doğrudan ilişkili en az 3 adet çalışmalarının olması ve bunların derleme içinde kullanılması durumunda yayınlanmak üzere kabul edilebilecektir. Sorumlu yazar, derlemesini gönderirken konu ile ilgili makalelerinin de künye bilgilerini dergi editörlüğüne göndermelidir (makale künyeleri, makale metninin en son sayfasında sunulmalıdır). Harran Üniversitesi Veteriner Fakültesi Dergisi'nde değerlendirmeye alınan ve yayınlanan derlemeler **çağrılı derlemelerden** oluşmaktadır. Derlemelerde; Özet, Giriş, Sonuç ve Kaynaklar bölümleri bulunmalıdır.

Olgu Sunumu: Yazarların, karşılaştıkları yeni veya ender gözlemlenen olguların ele alındığı, bilimsel değere sahip bilgileri içeren eserlerdir. En fazla 15 kaynak kullanılmalı ve bu kaynakların güncel olmasına özen gösterilmelidir. Olgu sunumları; Özet, Giriş, Olgu tanımı, Tartışma ve Sonuç ile Kaynaklar bölümlerinden oluşmalıdır.

Kısa Bilimsel Makale: Kısa bilimsel makalelerde dar kapsamlı olarak ele alınmış, yeni bilgi ve bulgular sunulmalıdır. Araştırma makalesi formatında hazırlanmalı ve en fazla 5 sayfa olmalıdır. En fazla 2 tablo veya şekil içermelidir.

Kaynaklar

Metin içinde atıf yapılırken;

1. Yazar veya yazarların soyadından sonra parantez içinde kaynağın yayın yılı belirtilmelidir; Adams (1998) tarafından; Wilkie ve Whittaker (1997) tarafından; Doyle ve ark. (2007) tarafından....
2. Cümlelerin sonunda atıf yapıldığında ise yazar ismi ve yayın yılı parantez içinde belirtilmelidir; ... bildirilmiştir (Adams, 1998); bildirilmiştir (Wilkie ve Whittaker, 1997); bildirilmiştir (Doyle ve ark., 2007).
3. Birden çok kaynağa atıf yapılması durumunda önce alfabetik sonra kronolojik sıralama yapılmalıdır; bildirilmiştir (Adams, 1998; Adams, 2008; Doyle ve ark., 2007; Wilkie ve Whittaker, 2006).
4. Aynı yazarın aynı yıl yayınları söz konusu ise her biri "a" harfinden başlayarak küçük harflerle işaretlenmelidir; (Adams, 2005a; Adams, 2005b;...).

Kaynak listesi aşağıdaki şekilde hazırlanmalıdır:

1. **Kaynak listesi yazar soyadına göre alfabetik olarak sıralanmalıdır.**
2. **Kaynaklarda yer alacak dergi adları ISI web of Science'a göre kısaltılmalı ve italik yazılmalıdır.**
3. **Kaynakların yazın şekli aşağıdaki şekilde olmalıdır.**

Makale; Sullivan JC, Sasser JM, Pollock JS, 2007: Sexual dimorphism in oxidant status in spontaneously hypertensive rats. *Am J Physiol Integr Comp Physiol*, 292 (1), 64-68.

Kitap; Cadenas E, Packer L, 2001: Handbook of Antioxidants. 2nd ed., Marcel Dekker Inc., New York, USA.

Kitaptan bir bölüm: Bahk J, Marth EH (1990). Listeriosis and *Listeria monocytogenes* In: Foodborne Diseases, Cliver DO (Ed), 248-256, Academic Press, San Diego. **Web sayfası:** Anonim (1) <http://www.emea.europa.eu>, Erişim tarihi; 01.04.2010.

Tez: Er A, 2009: Makrolid grubu antibiyotiklerin endotoksemide sitokin düzeylerine etkisi. Doktora tezi, SÜ Sağlık Bilimleri Enstitüsü, Konya.

Bilimsel toplantıda sunulan bildiri: Allen WR, Wilsher S, Morris L, Crowhurst JS, Hillyer MH, Neal HN, 2006: Re-establishment of oviducal patency and fertility in infertile mares. In: Proceedings of the Ninth International Symposium on Equine Reproduction, Kerkrade, Holland, pp. 27-28.

Tablo ve Şekiller: Her bir tablo ve şekil ayrı sayfalara yerleştirilmelidir. Kullanım sırasına göre numaralandırılmalı, kısa başlıklarla ifade edilmeli ve metin içinde tablo numarası verilerek atıfta bulunulmalıdır. Tablo başlıkları makalenin yazım dilinde tablonun üst bölümüne yazılmalıdır. Tabloda kullanılan kısaltmalar ve gerekli açıklamalar tablo altında verilmelidir. Şekil başlıkları makalenin yazım dilinde şeklin alt bölümüne yazılmalıdır.

HARRAN UNIVERSITY VETERINARY FACULTY JOURNAL PUBLICATION RULES *

- 1- Journal of Harran University Veterinary Faculty is a refereed journal that publishes original clinical and experimental research in Turkish and English, covering human and animal health, especially in the field of Veterinary Science, case reports, reviews (at least 3 on the subject of compilation of the invited or responsible author) the research paper must be on the reference list), short scientific articles and letters to the editor. Publishing articles in English is given priority in the journal. The journal is published electronically every 6 months and 2 issues a year. There are no fees for published articles.
- 2- Publications accepted to the journal should not have been published elsewhere. It should not have been submitted to other journals for review simultaneously. All legal and criminal liability arising from the published articles belong to the authors. Authors are not paid the right to publish. Submitted articles and their attachments are not returned, whether the article is published or not.
- 3- The works that have been previously communicated in congresses and published with a summary are accepted to be stated on the cover page. However, if the publication is produced from the thesis and there is a supporting organization, it should be stated in the publication.
- 4- The article that reaches the Journal Editor is subjected to preliminary evaluation by the journal editor. Editing has the right to reject the article according to the preliminary evaluation result or to request correction before subjection to the reviewer.
- 5- Articles are sent to at least two referees for evaluation. In the article acceptance process, if the opinions of the two referees differ, the editor decides by taking the opinion of a third referee or advisory board.
- 6- TUBITAK ULAKBIM respect for ethical principles, which opened to the use of all universities in Turkey "iThenticate" sent through plagiarism detection program, the whole article, must be made of the case report and review of the preliminary assessment and the delivery of results. According to these preliminary evaluation results, the similarity rate of articles, case reports or reviews with other references should not exceed 15% (excluding abstract, abstract and references). Articles, case reports or reviews sent to our journal for publication will not be evaluated if the similarity rate exceeds 15% in the evaluation made through the "ithenticate" program.
- 7- At least 20% of references to any submitted article (for all article categories) must include references published in the last five years. Anonymous references should be kept to a minimum.
- 8- If the article is accepted for publication, the Copyright Transfer Agreement, which includes the declaration that any right of publication has been transferred, must be signed by all authors and sent to the journal editor before printing. Articles without Copyright Transfer Agreement are not published even if they are accepted to publish.
- 9- An article, case report, review etc. to be sent to Harran University Veterinary Faculty Journal. When the works are sent to <https://dergipark.org.tr/tr/pub/huvfd>, they are taken into the evaluation process.
- 10- An article, case report, review etc. to be sent to Harran University Veterinary Faculty Journal. Works must be saved in MS Word format, all photographs (pictures) at least 300 dpi resolution, in TIFF or JPEG format.

WRITING RULES

Manuscripts should be prepared in MS Word format, Times New Roman font, with 12 font size, double line spacing and 2.5 cm space on each side. Line numbers (continually starting from page 2 of the article) should be added to the article. Articles of this type should not exceed 15 pages in original scientific research and reviews, including figures and tables, and 5 pages in short scientific articles and case reports.

International Standard Units (SI-system) should be used for units and dimensions.

Research Articles: Original research articles should be arranged in the order of the following main topics: Title, Author names (must be marked with the responsible author (*)), Author addresses, Author ORCID numbers, Abstract and Keywords (3 - 6 words), English title, Abstract and Introduction to Keywords, Material and Method, Results, Discussion and Conclusion, Thanks or Information and References. Each Table and Figure should be on separate pages.

STYLE AND FORMAT

Abstract: It should be prepared not to exceed 250 words in original research articles and 200 words in other types of articles.

Keywords: It should be given in alphabetical order below the summary in both languages, maximum 6. Keywords should be selected from Turkey Science Terms. Turkey Science Terms in the selection of keywords from the internet address (<http://www.bilimterimleri.com>) should be utilized.

Introduction: In order for the results to be understood and interpreted, information about the studies done on that subject should be included. In the introduction, the hypothesis of the study should be specified. The purpose of the study should be clearly written at the end of this section.

Material and Method: Experimental studies should be given in this section with sufficient detail that can be repeated by other researchers. When using a technique described in an article published in international indexed journals, it is necessary to describe the method very briefly and to cite the relevant original article. In the article, it should be stated in this section whether the ethical committee permission and / or legal / special permission should be obtained. In original research articles using animals as materials (clinical, experimental, field studies, etc.); ethics committee approval must have been obtained. Explanatory information including the name, number and date of the ethics committee's ethics committee approval / permit document should be written in the material and method section. The editorial board has the right to request the ethics committee approval document.

Results: Research findings should be given clearly and understandably. Findings should be supported with tables and figures when necessary and presented briefly.

Discussion and Conclusion: Findings should be discussed in the light of the literature before going into unnecessary detail and the importance of the findings should be emphasized. It should be finished with a conclusion or suggestion sentence.

Acknowledgment: Personal contribution and monetary support to the study or article should be stated here.

Compilation: These are articles that contain innovations on the subjects of the journal's publications and are prepared by using current references. If the authors have at least 3 works directly related to the subject and they can be accepted for publication. When submitting his review, the responsible author should send the imprint information of the articles related to the subject to the editor of the journal (article tags must be presented on the last page of the article text). Reviews compiled and published in Harran University Veterinary Faculty Journal are invited reviews. In the compilation; Summary, Introduction, Conclusion and References sections should be available.

Case Report: These are the works that contain information of scientific value that the authors discuss the new or rare cases that they encounter. Maximum 15 references should be used and care should be taken to keep these references up to date. Case reports; It should consist of Summary, Introduction, Case description, Discussion and Conclusion and References sections.

Short Scientific Article: In short scientific articles, it should be handled narrowly and new information and findings should be presented. It should be prepared in the form of a research paper and should not exceed 5 pages. Must contain no more than 2 tables or figures.

References:

While citing in the text;

1. The publication year of the reference should be specified in parentheses after the surname of the author or authors; By Adams (1998); By Wilkie and Whittaker (1997); Doyle et al. (2007) by....

2. When cited at the end of the sentence, the name of the author and the year of publication must be indicated in parentheses; ... have been reported (Adams, 1998); has been reported (Wilkie and Whittaker, 1997); has been reported (Doyle et al., 2007).

3. In case of reference to more than one reference, first alphabetical and chronological order should be done;

.... reported (Adams, 1998; Adams, 2008; Doyle et al., 2007; Wilkie & Whittaker, 2006).

4. If the same author has publications in the same year, each should be marked in lowercase letters, starting with the letter "a";

.... (Adams, 2005a; Adams, 2005b;...).

The list of references should be prepared as follows:

1. Reference list should be listed alphabetically by author surname.

2. The names of the journals in the references should be shortened according to the ISI web of Science and should be written in italics.

3. Type of references should be as follows.

Journal article; Sullivan JC, Sasser JM, Pollock JS, 2007: Sexual dimorphism in oxidant status in spontaneously hypertensive rats. *Am J Physiol Integr Comp Physiol*, 292 (1), 64-68.

Book; Cadenas E, Packer L, 2001: Handbook of Antioxidants. 2nd ed., Marcel Dekker Inc., New York, USA.

Chapter in a book: Bahk J, Marth EH (1990). Listeriosis and *Listeria monocytogenes* In: Foodborne Diseases, Cliver DO (Ed), 248-256, Academic Press, San Diego. Web page: Anonymous (1) <http://www.emea.europa.eu>, Access date; 01.04.2010.

Thesis: Er A, 2009: Effect of macrolide antibiotics on cytokine levels in endotoxemia. PhD thesis, SU Health Sciences Institute, Konya.

Paper presented at the scientific meeting: Allen WR, Wilsher S, Morris L, Crowhurst JS, Hillyer MH, Neal HN, 2006: Re-establishment of oviducal patency and fertility in infertile mares. In: Proceedings of the Ninth International Symposium on Equine Reproduction, Kerkrade, Holland, pp. 27-28.

Tables and Figures: Each table and figure should be placed on separate pages. It should be numbered according to the order of use, expressed in short titles, and should be cited by giving the table number in the text. Table titles should be written in the writing language of the article in the upper part of the table. Abbreviations and necessary explanations used in the table should be given under the table. Figure titles should be written at the bottom of the figure in the writing language of the article.

HARRAN ÜNİVERSİTESİ VETERİNER FAKÜLTESİ DERGİSİ

TELİF HAKKI DEVİR FORMU

Harran Üniversitesi

Veteriner Fakültesi Dergisi Editörlüğüne

Biz aşağıda adı, soyadı ve imzaları bulunan yazarlar, tarafımızdan yazılmış,

.....
.....

İsimli makalenin içeriği, sonuçları ve yorumları konusunda, Harran Üniversitesi Veteriner Fakültesi Dergisi'nin hiçbir sorumluluk taşımadığını kabul ederiz. Sunduğumuz makalenin orijinal olduğunu, herhangi bir başka dergiye yayınlanmak üzere gönderilmediğini, daha önce yayınlanmadığını beyan ederiz. Makalenin telif hakkından feragat etmeyi kabul ederek sorumluluğu üstlenir ve imza ederiz. Makalenin telif hakkı Harran Üniversitesi Veteriner Fakültesi Dergisi'ne devredilerek yayınlanması konusunda yetkili kılınmıştır.

Bununla birlikte yazarların aşağıdaki hakları saklıdır:

1. Telif Hakkı dışında kalan patent v.b. bütün tescil edilmiş haklar.
2. Yazarın gelecekteki kitaplar ve dersler gibi çalışmalarında; makalenin tümü ya da bir bölümünü ücret ödemeksizin kullanma hakkı.
3. Makaleyi ticari amaçlarla kullanmamak koşulu ile çoğaltma hakkı.

Yazarın Adı ve Soyadı

Tarih

İmza

.....
.....
.....
.....
.....
.....
.....

Sorumlu yazarın adı/yazışma adresi:

.....

Telefon: Fax: E-mail:

(Makale başvurusu ile bu formu bütün yazarlar tarafından imzalanmış olarak "<http://dergipark.gov.tr/huvfd>" adresinden yükleviniz.)

COPYRIGHT TRANSFER FORM

We grant that Harran University Journal of the Faculty of Veterinary Medicine has no responsibility for the content, results and conclusions of the manuscript entitled,

.....
.....

We state that the submitted manuscript is original, has not been published or is not being considered for publishing elsewhere. We grant to disclaim the copyright and sign this form by undertaking all responsibility. Hereby Harran University Journal of the Faculty of Veterinary Medicine has been authorized for publishing by transferring the copyright of the manuscript.

However the following rights of the author(s) are reserved:

1. All other rights such as patent right.
2. The rights for using the manuscript as a whole or a part in their future Works such as books or lectures without paying any charge.
3. The rights for reproducing the manuscript for purpose other than commercial use.

<u>Name and Surname of the Author</u>	<u>Date</u>	<u>Signature</u>
.....
.....
.....
.....
.....
.....

Address of the Corresponding Author:

.....
.....

Phone: Fax: E-mail:

(Upload the form to "<http://dergipark.gov.tr/huvfd>" after filling it.)

